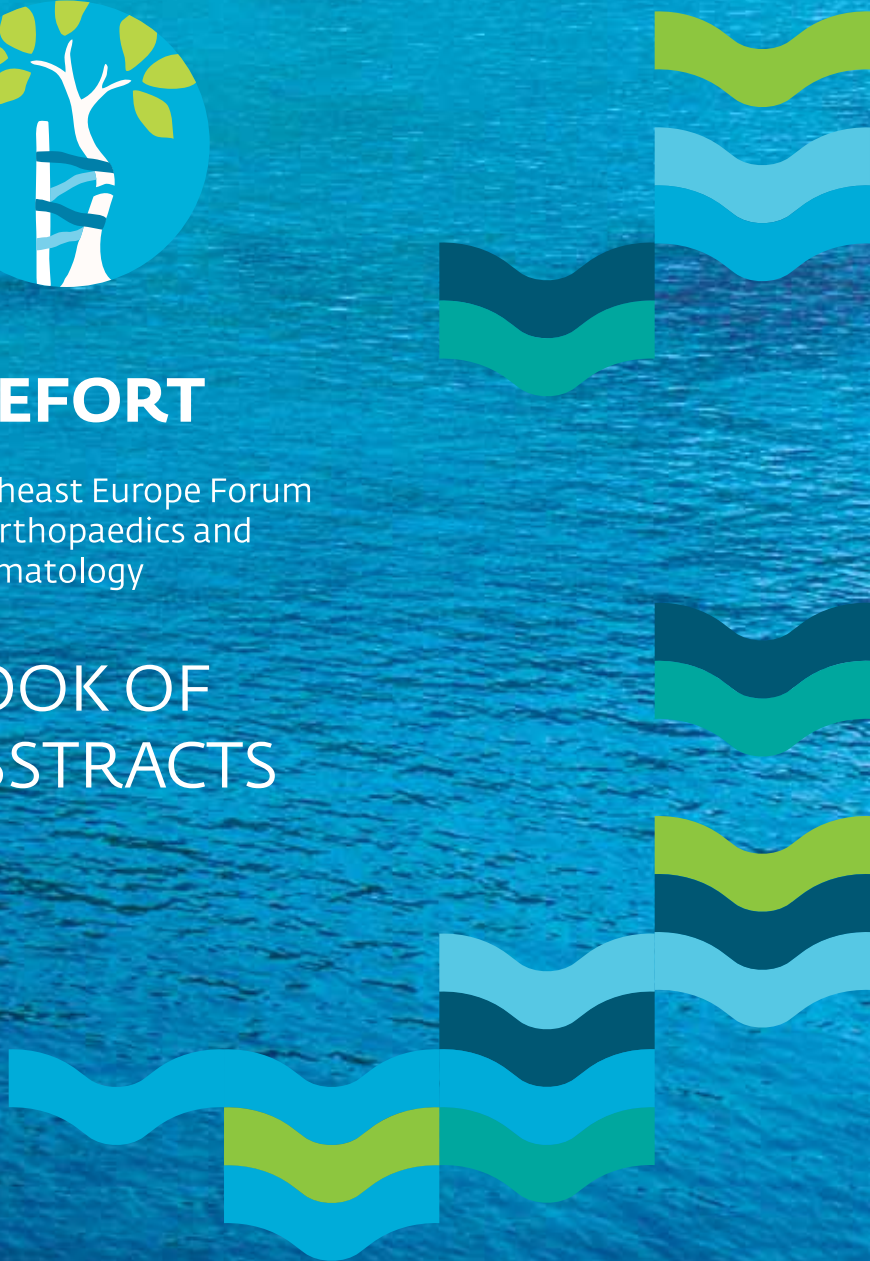



SEEFORT

Southeast Europe Forum
on Orthopaedics and
Traumatology

BOOK OF ABSTRACTS





SEEFORT

Welcome!



Robert Kolundžić
The President of the
Organizing Committee
of SEEFORT



Damir Hudetz
Vice President of the
Organizing
Committee of SEEFORT



Alan Ivković
President of the
Scientific
Committee of SEEFORT




UNDER THE
AUSPICES
PRESIDENT OF
THE REPUBLIC
OF CROATIA
KOLINDA
GRABAR
KITAROVIĆ





SEEFORT – the Southeast European Forum on Orthopaedics and Traumatology was granted 15 European CME credits (ECMEC) by the European Accreditation Council for Continuing Medical Education (EACCME).



SEEFORT will be scored by the Croatian Medical Chamber.

Speaker (CMA) - 20

Participant (CMA) - 12

Speaker (Nurse's day) - 15

Participant (Nurse's day) - 11





ORGANIZING COMMITTEE

Marko Bergovec
Ivan Bohaček
Ivan Bojanić
Robi Božić
Đivo Brailo
Tomislav Čengić
Stipe Ćorluka
Stjepan Dokuzović
Miljenko Franić
Domagoj Gajski
Gordan Gulan
Miroslav Hašpl
Damir Hudetz
Alan Ivković
Željko Jeleč
Mislav Jelić
Petra Jurina
Boris Kirin
Robert Kolundžić
Boris Lah
Zoran Marković
Radovan Mihelić
Michele Mikolaučić
Hrvoje Mitrović
Zdenko Ostojić
Tadija Petrović
Joško Smilović
Neda Vioić
Zoran Zelić
Ognjen Živković



SCIENTIFIC COMMITTEE

Darko Antičević
Miroslav Hašpl
Damir Hudetz
Alan Ivković
Mislav Jelić
Simon Kovač
Aljoša Matejčić
Radovan Mihalić
Boris Poberaj
Krešimir Rotim
Miroslav Smerdelj
Rihard Trebše



FACULTY

Feridun Acar, Turkey
Darko Antičević, Croatia
Aleš Berce, Slovenia
Marko Bergovec, Croatia and Austria
Tahsin Beyzadeoglu, Turkey
Davor Bojić, Croatia
Aleksandra Bonevski, Croatia
Stephen Cannon, UK
Vatroslav Čerina, Croatia
Nataša Desnica, Croatia
Drago Dolinar, Slovenia
Mahmut Nedim Doral, Turkey
Božidar Egić, Croatia
Yavor Enchev, Bulgaria
Francesco Falez, Italy
Niklaus Friederich, Switzerland
Jeroen Geurts, Switzerland
Peter Giannoudis, UK
Nadomir Gusić, Croatia
Vedran Hadžić, Slovenia
Miroslav Hašpl, Croatia
Michael Hirschmann, Switzerland
Damir Hudetz, Croatia
Thomas Hugle, Switzerland
Gazi Huri, Turkey
Muharrem Inan, Turkey
Alan Ivković, Croatia
Saša Janković, Croatia
Mislav Jelić, Croatia
Gregor Kavčič, Slovenia
Karl Knahr, Austria
Alena Kobesova, Czech Republic
Nikša Koić, Croatia
Zlatko Kolić, Croatia
Simon Kovač, Slovenia



Vlado Kovač, Croatia
Ozren Kubat, Croatia
Manfred Kuschnig, Austria
Marteen van der List, Netherland
Inga Marijanović, Croatia
Rene Mihalič, Slovenia
Radovan Mihelić, Croatia
Martin Mikek, Slovenia
Puneet Monga, UK
Manuel Cassiano Neves, Portugal
Philippe Neyret, France
Hakan Omeroglu, Turkey
Geert Pagenstert, Switzerland
Duilio Peroša, Slovenia
Florian Plattner, Austria
Bernd Preininger, Germany
Boris Poberaj, Slovenia
Nebojša Popović, Qatar
Lukas Rasulić, Serbia
Željka Roje, Croatia
Krešimir Rotim, Croatia
Srećko Sabalić, Croatia
Tomislav Sajko, Croatia
Ludwig Seebauer, Germany
Nemanja Slavković, Serbia
Tomislav Smoljanović, Croatia
Vladan Stevanović, Serbia
Robert Streicher, Switzerland
Miklos Szendroi, Hungary
Jurij Štalc, Slovenia
Rihard Trebše, Slovenia
Vladimir Trkulja, Croatia
Peter Verdonk, Belgium
Matjaž Vogrin, Slovenia
Matjaž Voršič, Slovenia
Tobias Winkler, Germany



Online Surveys

Please give us your thoughts on overall Seefort 2015 experience.

Your feedback helps us determine each year how to make the next year's conference even better.

Please, scan to evaluate!

Thank You in Advance!

SEEFORT Team

Thursday 23.4.2015.

HALL 1

BIOTECHNOLOGY IN ORTHOPAEDICS

Chairmen: ŽELJKO JELEČ, Croatia and INGA MARIJANOVIĆ, Croatia

08:30 – 08:37	5' + 2'	Clinical parameters after Fondaparinux vs Nadroparin thromboprophylaxis in total knee arthroplasty	Damjan Dimnjaković, Croatia
08:37 – 08:44	5' + 2'	Contemporary approaches in using of autologous platelet rich plasma in order to stimulate meniscal healing	Džihan Abazović, Montenegro
08:44 – 08:51	5' + 2'	NF-κB signalling controls ADAMTS5 gene expression in OUMS27 cells	Dilek Gün Bilgiç, Turkey
08:51 – 08:58	5' + 2'	Variation in differentiation potential in clonal mesenchymal stem cell populations	WS Khan, UK
08:58 – 09:05	5' + 2'	Expression of inducible nitric oxide synthase and nuclear factor kappa B in synovial membrane in patients with osteoarthritis of the knee	Marko Ostojić, Bosnia and Herzegovina
09:05 – 09:12	5' + 2'	New Regime for Thromboprophylaxis in Knee Arthroplasties	Hussein Nouredine, UK
09:12 – 09:19	5' + 2'	Tranexamic acid in hip and knee arthroplasty our experiences	Petar Cvijić, Bosnia and Herzegovina

BIOTECHNOLOGY IN ORTHOPAEDICS

Orthobiologics - where do we stand?

Leaders: MARKO PEČINA, Croatia and ALAN IVKOVIĆ, Croatia

Chairmen: TAHSIN BEYZADEOGLU, Turkey and DAMIR HUDETZ, Croatia

09:30 – 09:35	5'	Introduction	Alan Ivković, Croatia
09:35 – 09:55	20'	Inovative autologous orthobiologic therapies - from basic concept to clinical application	Matjaž Vogrin, Slovenia
09:55 – 10:15	20'	Autologous Conditioned Serum	Tahsin Beyzadeoglu, Turkey
10:15 – 10:35	20'	Mesenchymal stem cells in orthopaedic tissue engineering	Inga Marijanović, Croatia
10:35 – 11:00	25'	Discussion	
11:00 – 11:15	15'	Coffee Break	

BIOTECHNOLOGY IN ORTHOPAEDICS

New insights in cartilage repair

Leaders: MARKO PEČINA, Croatia and ALAN IVKOVIĆ, Croatia

Chairman: MARKO PEČINA, Croatia and MAHMUT NEDIM DORAL, Turkey

11:15 – 11:20	5'	Introduction	Damir Hudetz, Croatia
11:20 – 11:40	20'	What is the meaning of adjacent surgical procedures in cartilage reconstruction of the knee?	Geert Pagenstert, Switzerland
11:40 – 12:00	20'	Bioreactor-based cartilage engineering	Alan Ivković, Croatia
12:00 – 12:20	20'	The biological tropism of hyaline cartilage in different hosts	Mahmut Nedim Doral, Turkey
12:20 – 12:40	20'	Discussion	
13:00 – 14:00	60'	Lunch	

EFORT FORA

Joint Preserving Knee Reconstruction

Leader: MISLAV JELIĆ, Croatia

Chairmen: MISLAV JELIĆ, Croatia and PHILIPPE NEYRET, France

14:00–14:05	5'	Introduction	Mislav Jelić, Croatia
14:05–14:25	20'	Multiligamentous injuries of the knee	Niklaus Friederich, Switzerland
14:25–14:45	20'	Meniscal transplantation vs synthetic scaffold replacement	Peter Verdonk, Belgium
14:45–15:05	20'	Patellofemoral joint stabilization	Damir Hudetz, Croatia
15:05–15:25	20'	Corrective osteotomies around the knee joint	Philippe Neyret, France
15:25–15:45	20'	Discussion	
15:45–16:00	15'	Coffee break	

GENERAL ORTHOPAEDICS

Chairmen: BORIS KIRIN, Croatia and ROBI BOŽIĆ, Croatia

16:00 – 16:07	5' + 2'	First metatarsal head osteotomy for the correction of moderate hallux valgus with and without lateral release	Goran Vrgoč, Croatia
16:07 – 16:14	5' + 2'	Epidemiological data of rehabilitation after total knee arthroplasty	Jakov Prenc, Croatia
16:14 – 16:21	5' + 2'	Uncemented total knee arthroplasty_ with minimum 2 years follow up	Srdjan Dojcinovic, Switzerland
16:21 – 16:28	5' + 2'	Medial Unicompartmental Knee Arthroplasty in Patients Less Than 50 Years Old - Minimum of Two Years of Follow Up	Srdjan Dojcinovic, Switzerland
16:28–16:35	5' + 2'	Salvage procedures after revision surgery of periprosthetic fractures in TKA	Cristoph Knoth, Switzerland
16:35 – 16:42	5' + 2'	Bone loss management in difficult primary and revision total knee surgery	Boris Žulj, Croatia

GENERAL ORTHOPAEDICS - LOWER EXTREMITY

Round table: Hip arthroscopy

Leader: SAŠA JANKOVIĆ, Croatia

Chairmen: SAŠA JANKOVIĆ, Croatia and TOMISLAV SMOLJANOVIĆ, Croatia

16:45 – 16:50	5'	Introduction	Saša Janković, Croatia
16:50 – 17:10	20'	Indications and portal placement	Tomislav Smoljanović, Croatia
17:10 – 17:30	20'	Femoroacetabular impingement	Saša Janković, Croatia
17:30 – 17:50	20'	Hip labral tear repair	Trpimir Vrdoljak, Croatia
17:50 – 18:00	10'	Discussion	
18:30–19:30	60'	Opening ceremony with welcome drink	

HALL 2

GENERAL ORTHOPAEDICS

Chairmen: ZORAN ZELIĆ, Croatia and MARTIN MIKEK, Slovenia

08:30 – 08:37	5' + 2'	Hook of hamate non union presented and initially mistreated as ulnar nerve compression	Mario Josipović, Croatia
08:37 – 08:44	5' + 2'	Arthroscopic capsulolabral reconstruction in posterior glenohumeral instability facing various intraarticular pathology	Neenad Medančić, Croatia
08:44 – 08:51	5' + 2'	Reverse total shoulder arthroplasty in patients with rheumatoid arthritis – current concepts and our experience	Danijel Matek, Croatia
08:51 – 08:58	5' + 2'	An overview of periprosthetic fracture management after shoulder arthroplasty	Christoph Knoth, Switzerland
08:58–09:05	5' + 2'	Modified Eden Lange procedure for trapezius palsy; A case report	Tomislav Tabak, Croatia
09:05–09:12	5' + 2'	Longitudinal versus Transversal incision in the DeQuervain disease a comparative study	Miguel Frias, Portugal
09:12 – 09:19	5'+2'	Doha Agreement meeting on terminology and definitions in groin pain in athletes	AWeir, Qatar

GENERAL ORTHOPAEDIC TOPICS - UPPER EXTREMITY

Current concepts in elbow surgery

Leader: RADOVAN MIHELIĆ, Croatia and BORIS POBERAJ, Slovenia

Chairmen: NEBOJŠA POPOVIĆ, Qatar and EMILIO LOPEZ VIDRIERO, Spain and RADOVAN MIHELIĆ, Croatia

09:30–09:35	5'	Introduction	Radovan Mihelić, Croatia
09:35–09:55	20'	Arthroscopic treatment of early OA of the elbow	Martin Mikek, Slovenia
09:55–10:15	20'	Radial head fractures: indications and outcomes for radial head	Nebojša Popović, Qatar
10:15–10:35	20'	Posterolateral rotatory instability of the elbow	Emilio Lopez Vidriero, Spain
10:35–11:00	25'	Discussion	
11:00 – 11:15	15'	Coffee Break	

GENERAL ORTHOPAEDIC TOPICS - UPPER EXTREMITY

Instructional Course: Shoulder prosthesis

Chairmen: LUDWIG SEEBAUER, Germany, DANIJEL MATEK, Croatia and BORIS POBERAJ, Slovenia

11:45 – 11:50	5'	Introduction	Boris Poberaj, Slovenia
11:50 – 12:10	20'	Partial shoulder endoprosthesis	Duilio Peroša, Slovenia
12:10 – 12:30	20'	Total shoulder endoprosthesis	Puneet Monga, UK
12:30 – 12:50	20'	Reverse shoulder endoprosthesis	Ludwig Seebauer, Germany
12:50 – 13:10	20'	Resurfacing shoulder arthroplasty	Marteen van der List, Netherland
13:10 – 13:30	20'	Discussion	
13:30 – 14:00	30'	Lunch	

MUSCULOSKELETAL TRAUMA

Round table: Hip trauma

Chairmen: PETER GIANNOUDIS, UK and NADOMIR GUSIĆ, Croatia and NEMANJA SLAVKOVIĆ, Serbia

14:00–14:05	5'	Introduction	Nadomir Gusić, Croatia
14:05–14:25	20'	Fracture non-union: Can biomarkers predict outcome?	Peter Giannoudis, UK
14:25–14:45	20'	Displaced femoral neck fractures: is there a standard of care?	Srećko Sabalić, Croatia
14:45–15:05	20'	Periprosthetic femoral fractures: a review of classification and current treatment	Nemanja Slavković, Serbia
15:05–15:25	20'	Acetabular fractures	Nadomir Gusić, Croatia
15:25–15:45	20'	Discussion	
15:45–16:00	15'	Coffee break	

MUSCULOSKELETAL TRAUMA

Chairmen: SREĆKO SABALIĆ, Croatia and DARKO MATIĆ, Croatia

16:00 – 16:07	5' + 2'	Acceleration of healing of long bone fractures in patients with concomitant severe head injuries	Fathy G Khallaf, Kuwait
16:07 – 16:14	5' + 2'	A new locking plate and dynamic screw system for internal fixation of intracapsular hip fractures: results for the first 530 patients treated	Daniele Pili, Italy
16:14 – 16:21	5' + 2'	„Bio-logical“ carbon fiber – peek intramedullary nailing for humeral shaft fractures - international multi-center experience	Nikša Kojić, Croatia
16:21 – 16:28	5' + 2'	Male sexual dysfunction after pelvic fracture	Ana Čizmić, Croatia
16:28–16:35	5' + 2'	Painful Nonunion After Missed Juvenile Tillaux Fracture In An Athlete - Description Of New Fixation Technique With Soft Suture Anchor	Ricardo Santos Pereira, Portugal
16:35 – 16:42	5' + 2'	Do patients with hip fractures admitted over the weekend have worse outcomes compared to those admitted on weekdays - a retrospective case control study	Svyatoslav Kechyn, United Kingdom

MUSCULOSKELETAL TRAUMA

Instructional course: Proximal humerus fractures

Leaders: ALJOŠA MATEJČIĆ, Croatia and BORIS LAH, Croatia

Chairmen: NIKŠA KOIĆ, Croatia and VLADAN STEVANOVIĆ, Serbia

17:00 – 17:05	5'	Introduction	Vladan Stevanović, Serbia
17:05 – 17:25	20'	Treatment of complex humeral fractures - improvement and limitations	Peter Giannoudis, UK
17:25 – 17:45	20'	Intramedullar nails for humeral fractures	Nikša Koić, Croatia
17:45 – 18:05	20'	LCP system for proximal humeral fractures	Vladan Stevanović, Serbia
18:05 – 18:25	20'	Discussion	
18:30 – 19:30	60'	Opening ceremony with welcome drink	

HALL 3

SPINE

Chairmen: MILJENKO FRANIĆ, Croatia and TOMISLAV SAJKO, Croatia

08:30 – 08:37	5' + 2'	Frequency of infections in politraumatized patients after operating treatment	Sandra Slabe, Croatia
08:37 – 08:44	5' + 2'	The effect of induced brain injury and spinal cord injury on the union of femoral osteotomy in rabbits	Fathy G Khallaf, Kuwait
08:44 – 08:51	5' + 2'	The impact of the Irish economic recession of 2008 and the evolution of spinal surgery in the West of Ireland 2005-2013.	Michael O'Sullivan, Ireland
08:51 – 08:58	5' + 2'	PLIF and Unilateral transpedicular fixation	Saša Rapan, Croatia
08:58 – 09:05	5' + 2'	Is there a place for minimal invasive and endoscopic surgery on the lumbar spine: Are there any advantages for the future?	Stefan Hellinger, Germany
09:05 – 09:12	5' + 2'	4 years outcome after microtubular disc decompression with radiowave disc treatment for herniated discs	Stefan Hellinger, Germany
09:12-09:19	5' + 2'	Decompression coupled with Interspinous Process Device for Degenerative Lumbar Spinal Stenosis	Nino Mirnik, Slovenia

SPINE

Instructional course: Minimally invasive discectomy

Leader: KREŠIMIR ROTIM, Croatia and MATJAŽ VORŠIČ

Chairmen: DOMAGOJ ČORIĆ, USA and KREŠIMIR ROTIM, Croatia

09:30–09:35	5'	Introduction	Krešimir Rotim, Croatia
09:35–09:50	15'	Endoscopic microdiscectomy	Krešimir Rotim, Croatia
09:50–10:05	15'	Minimal invasive lumbar discectomy	Tomislav Sajko, Croatia
10:05–10:20	15'	Posterior lumbar interbody fusion (PLIF)	Matjaž Voršič, Slovenia
10:20–10:35	15'	Comparison between the surgical outcomes of the lumbar microdiscectomy with patients in prone and lateral positions	Yavor Enchev, Bulgaria
10:35–11:00	25'	Discussion	
11:00 – 11:15	15'	Coffee Break	
11:15–11:45	30'	Workshop: Medtronic	

SPINE

Instructional course: Minimally invasive spondylosis

Leader: KREŠIMIR ROTIM, Croatia

Chairmen: FERIDUN ACAR, Turkey and YAVOR ENCHEV, Bulgaria

11:45 – 11:50	5'	Introduction	
11:50 – 12:10	20'	Anterior cervical discectomy	Vatroslav Čerina, Croatia
12:10 – 12:30	20'	Spinal cord stimulation in treatment of failed back surgery syndrome	Feridun Acar, Turkey
12:30 – 12:50	20'	Complications of MISS	Zlatko Kolić, Croatia
12:50 – 13:10	20'	Surgical treatment of chronic pain	Lukas Rasulić, Serbia
13:10 – 13:30	20'	Discussion	
13:30 – 14:30	60'	Lunch	

REHABILITATION DAY

Instructional course: Low back pain

Leaders: MIJENKO FRANIĆ, Croatia and BOŽIDAR EGIĆ, Croatia

Chairmen: ALENA KOBASOVA, Czech Republic and KOLAROV, Czech Republic and BOŽIDAR EGIĆ, Croatia

14:30–14:35	5'	Introduction	Miljenko Franić, Croatia
14:35–14:55	20'	Dynamic Neuromuscular Stabilization approach for low back pain, dysfunction and optimal performance	Alena Kobesova, Czech Republic
14:55–15:15	20'	Diaphragm role in stabilization and definition of ideal postural-locomotion function from developmental perspective	Pavel Kolar, Czech Republic
15:15–15:30	15'	Interactive Workshop: Functional assessment and treatment of postural-locomotion function and breathing stereotype in low back pain (Part 1)	Alena Kobesova and Pavel Kolar, Czech Republic
15:30–15:45	15'	Interactive Workshop: Functional assessment and treatment of postural-locomotion function and breathing stereotype in low back pain (Part 2)	
15:45–16:00	15'	Coffee break	

REHABILITATION DAY

Round table: Isokinetics

Leaders: MIJENKO FRANIĆ, Croatia and BOŽIDAR EGIĆ, Croatia

Chairmen: NATAŠA DESNICA, Croatia, VEDRAN HADŽIĆ, Slovenia and MIJENKO FRANIĆ, Croatia

16:00 – 16:05	5'	Introduction	Božidar Egić, Croatia
16:05 – 16:25	20'	The principles and clinical applications of isokinetic strength testing	Vedran Hadžić, Slovenia
16:25 – 16:45	20'	Isokinetic rehabilitation	Nataša Desnica, Croatia
16:45 – 17:05	20'	Isokinetic treatment of muscle dysfunction	Božidar Egić and Dalibor Veber, Croatia
17:05–17:30	25'	Discussion	
18:30–19:30	60'	Opening ceremony with welcome drink	

Friday 24.4.2015.

HALL 1

GENERAL ORTHOPAEDICS

Chairmen: ZDENKO OSTOJIĆ, BIH, HRVOJE MITROVIĆ, Croatia and JOŠKO SMILOVIĆ, Croatia

08:30 – 08:37	5' + 2'	Enhanced Recovery After Surgery (ERAS) Protocol in Total Joint Arthroplasty	Silvester Tomaž, Slovenia
08:37 – 08:44	5' + 2'	How to improve non original acetabular liner stability after revision surgery?	Ivan Bohaček, Croatia
08:44 – 08:51	5' + 2'	Primary THR in cases of coxarthrosis with high luxation of the hip	Željko Jovičić, Bosnia and Herzegovina
08:51 – 08:58	5' + 2'	Direct anterior approach	Tiago Pinheiro Torres, Portugal
08:58 – 09:05	5' + 2'	Modified lateral approach in dysplastic hip arthroplasty	Goran Bičanić, Croatia
09:05 – 09:12	5' + 2'	Advantages of the modified cotyloplasty technique in dysplastic hip arthroplasty - results of 5 year follow up	Domagoj Delimar, Croatia
09:12 – 09:19	5' + 2'	First results after four years AMIS® surgery. A radiological follow up.	Leitner Mathias, Austria
09:19 – 09:26	5' + 2'	Ceramic BIOLOX delta in Total Hip Replacement	Pavel Dušek, Germany

HIP ARTHROPLASTY

Instructional course: Failed THA – Infection and tribology

Leader: RIHARD TREBŠE, Slovenia and ROBERT KOLUNDŽIĆ, Croatia

Chairmen: KARL KNAHR, Austria, DRAGO DOLINAR, Slovenia, SLAVKO MANOJLOVIĆ, BIH

09:30 – 09:35	5'	Introduction	Rihard Trebše, Slovenia
09:35 – 09:50	15'	Advantages and disadvantages of different bearing couples in the THA	Karl Knahr, Austria
09:50 – 10:05	15'	Hip aspiration – The ultimate diagnostic procedure	Bernd Preininger, Germany
10:05 – 10:20	15'	Surgical mistakes in infected THA treatment	Drago Dolinar, Slovenia
10:20 – 10:35	15'	Two-stage revision with an early reimplantation for PJI	Tobias Winkler, Germany
10:35 – 10:50	15'	Wear and corrosion of metal and ceramic bearings	Robert Streicher, Switzerland
10:50 – 11:00	10'	Discussion	
11:00 – 11:15	15'	Coffee Break	
11:15 – 12:00	45'	Workshop – symposia: Lima O.I.: Trabecular Titanium in acetabular revision: how to achieve biological fixation and joint reconstruction	

HIP ARTHROPLASTY

Round table: Emerging concepts in THA

Leader: RIHARD TREBŠE, Slovenia and ROBERT KOLUNDŽIĆ, Croatia

Chairmen: STEPHEN CANNON, UK, MANFRED KUSCHNIG, Austria, DOMAGOJ DELIMAR, Croatia

12:00–12:05	5'	Introduction	Rihard Trebše, Slovenia
12:05–12:20	15'	Anterior approach with a traction table	Manfred Kuschnig, Austria
12:20–12:35	15'	Anterior approach supine position	Gregor Kavčič, Slovenia
12:35–12:50	15'	Short stems - the evidence from the registries	Simon Kovač, Slovenia
12:50–13:05	15'	Imageless navigation of the socket in THA	Rene Mihalič, Slovenia
13:05–13:20	15'	CAD-CAM THA	Stephen Cannon, UK
13:20–13:35	15'	Fast track THA	Aleš Berce, Slovenia
13:35–13:45	10'	Discussion	All
13:45–14:30	45'	Lunch	

KNEE ARTHROPLASTY

Round table: Arthroplasty options in younger patient

Leaders: MIROSLAV HAŠPL, Croatia and SIMON KOVAČ, Slovenia

Chairmen: FRANCESCO FALEZ, Italy and SIMON KOVAČ, Slovenia

14:30–14:35	5'	Introduction	Miroslav Hašpl, Croatia
14:35–14:55	20'	Knee arthroplasty today	Francesco Falez, Italy
14:55–15:15	20'	Limited resurfacing arthroplasty	Tahsin Bezyadeoglu, Turkey
15:15–15:35	20'	Cemented or cementless knee arthroplasty	Simon Kovač, Slovenia
15:35–15:55	20'	Total knee arthroplasty – always a slam dunk?	Miroslav Hašpl, Croatia
15:55–16:15	20'	Discussion	
16:15–16:30	15'	Coffee Break	
16:30–17:15	45'	Simpozij Boehringer Ingelheim: Thromboembolic prophylaxis and periprocedural management with NOACs in O&T surgery	

KNEE ARTHROPLASTY

Round table: Revision knee arthroplasty

Leaders: MIROSLAV HAŠPL, Croatia and SIMON KOVAČ, Slovenia

Chairmen: PHILIPPE NEYRET, France and MIROSLAV HAŠPL, Croatia

17:15–17:35	20'	Introductory lecture: Open questions in revision knee arthroplasty	Francesco Falez, Italy
17:35–17:55	20'	SPECT/CT for the assessment of painful knee prosthesis	Michael Hirschmann, Switzerland
17:55–18:15	20'	The painful knee after TKA: a diagnostic algorithm for failure diagnosis	Florian Plattner, Austria
18:15–18:35	20'	Revision of unicompartmental arthroplasty to total knee arthroplasty	Philippe Neyret, France
18:35–18:45	10'	Discussion	
20:00–23:30		Dinner hosted by CrOS	

HALL 2

PAEDIATRIC ORTHOPAEDICS

Chairmen: TOMISLAV RIBIČIĆ Croatia and SLAVEN SIMON, Slovenia

08:30 – 08:37	5' + 2'	Range of motion and muscle strength improvement using elastic resistance and kinesiotope after operative treatment of the fractures in the elbow field.	Ana Nikolova, Bulgaria
08:37 – 08:44	5' + 2'	Primary malignant tumors of the pelvis - about 8 cases	Fourat Farhat, Tunisia
08:44 – 08:51	5' + 2'	Računarsko modeliranje nadlaktice i tumorske endoproteze zgloba ramena	Jovan Grujić, Serbia
08:51 – 08:58	5' + 2'	Direct 3D titanium alloy selective laser sintering made implant used for personalized pelvic reconstruction	Tomislav Čengiđ, Croatia
08:58 – 09:05	5' + 2'	Strategy and results in dwarfs lengthening	Daniele Pili, Italy
09:05 – 09:12	5' + 2'	Mid-term results of treatment in children with OCD of the talus	Damjan Dimnjaković, Croatia
09:12 – 09:19	5' + 2'	Management of proximal tibial osteoepiphyseolysis and patellar ligament avulsion with LCP plate	Slaven Simon, Slovenia

PAEDIATRIC ORTHOPAEDICS

The most common problems in paediatric orthopaedics

Leader: DARKO ANTIČEVIĆ, Croatia

Chairmen: DARKO ANTIČEVIĆ, Croatia and DAVOR BOJIĆ, Croatia

09:30 – 09:35	5'	Introduction	Darko Antičević, Croatia
09:35 – 09:55	20'	The most common problems of hip and pelvis	Darko Antičević, Croatia
09:55 – 10:15	20'	Rotational and angular problems of lower extremity	Ozren Kubat, Croatia
10:15 – 10:35	20'	The most common problems of foot and ankle	Davor Bojić, Croatia
10:35 – 11:00	25'	Discussion	
11:00 – 11:15	15'	Coffee Break	

PAEDIATRIC ORTHOPAEDICS

Current role of soft tissue surgery in paediatric orthopaedics

Leader: DARKO ANTIČEVIĆ, Croatia

Chairmen: HAKAN OMEROGLU, Turkey and MUHARREM INAN, Turkey

11:15 – 11:20	5'	Introduction	Hakan Omeroglu, Turkey
11:20 – 11:40	20'	Soft tissues surgery in DDH	Hakan Omeroglu, Turkey
11:40 – 12:00	20'	Lower limb soft tissue surgery in cerebral palsy	Muharrem Inan, Turkey
12:00 – 12:20	20'	Soft tissue surgery in club-foot	Hakan Omeroglu, Turkey
12:20 – 12:40	20'	Arthroscopic hip surgery in children	Muharrem Inan, Turkey
12:40 – 13:00	20'	Discussion	
13:00 – 14:30	90'	Lunch	

PAEDIATRIC ORTHOPAEDICS

Tumors in children. State of the art management.

Leader: DARKO ANTIČEVIĆ, Croatia

Chairmen: MARKO BERGOVEC, Austria and MIKLOS SZENDROI, Hungary

14:30–14:35	5'	Introduction	Marko Bergovec, Austria
14:35–14:55	20'	Tumors and Tumor like Lesions: Epidemiology	Marko Bergovec Austria
14:55–15:15	20'	Reconstruction surgery as challenge in young patient.	Miklos Szendroi, Hungary
15:15–15:35	20'	Molecular technique in the diagnostic, planing and treatment of tumors	Aleksandra Bonevski, Croatia
15:35–15:55	20'	Operative Treatment of tumors and Tumor like Lesions	Marko Bergovec, Austria
15:55–16:15	20'	Discussion	
16:15 – 16:30	15'	Coffee Break	

PAEDIATRIC ORTHOPAEDICS

Paediatric elbow fractures

Leader: DARKO ANTIČEVIĆ, Croatia

Chairmen: MANUEL CASSIANO NEVES, Portugal and DARKO ANTIČEVIĆ, Croatia

16:30 – 16:35	5'	Introduction	Manuel Cassiano Neves, Portugal
16:35 – 16:55	20'	Supra condylar fractures in children. Still a challenge?	Manuel Cassiano Neves, Portugal
16:55 – 17:15	20'	Late Monteggia: how to solve it?	Darko Anticevic, Croatia
17:15 – 17:35	20'	Elbow instability in children	Manuel Cassiano Neves, Portugal
17:35–17:55	20'	Discussion	

YOUTH DAY

17:55 – 18:15	20'	FORTE- Federation of Orthopaedic Trainees in Europe	Gazi Huri, Turkey
18:15 – 18:35	20'	Message to the Young Orthopaedic Surgeon About Orthopaedic Sports Traumatology	Mahmut Nedim Doral, Turkey
18:35–18:55	20'	Harmonisation of orthopaedic and traumatology in EU	Manuel Cassiano Neves, Portugal
20:00–23:30		Dinner hosted by CrOS	

Saturday 25.4.2015.

HALL 1

GENERAL ORTHOPAEDICS

Chairmen: GORAN BIČANIĆ, Croatia and GEERT PAGENSTERT, Switzerland

08:30 – 08:37	5' + 2'	Tendoscopic treatment of posterior tibial tendon insufficiency	Dimnjaković Damijan, Croatia
08:37 – 08:44	5' + 2'	The peg arthrodesis of the interphalangeal joints of toes	Andrej Prija, Slovenia
08:44 – 08:51	5' + 2'	Outcome of ankle arthrodesis with circular frames in post traumatic osteoarthritis.	Daniele Pili, Italy
08:51 – 08:58	5' + 2'	Dual role of peroneal tendoscopy in the treatment of ankle disorders	Goran Bičanić, Croatia
08:58 – 09:05	5' + 2'	Hip Arthroscopy In The Treatment Of Femoroacetabular Impingement	Tiago Pinheiro Toores, Portugal
09:05 – 09:12	5' + 2'	Clinical comparison of the Quadriceps and the Hamstring Tendons for primary reconstruction of an isolated ACL tear - a matched pair analysis	Guido Weirer, Austria
09:12 – 09:19	5' + 2'	Day case anterior cruciate ligament reconstruction - A study of 69 patients.	Srdjan Dojcinovic, Switzerland

YOUTH DAY

Leader: TADIJA PETROVIĆ, Croatia

Chairmen: MARIO JOSIPOVIĆ, Croatia and TOMISLAV ČENGIĆ, Croatia

09:30 – 09:35	5'	Introduction	Tomislav Čengić, Croatia
09:35 – 09:55	20'	Treatment Options for Isolated Patellofemoral Arthritis	Geert Pagenstert, Switzerland
09:55 – 10:15	20'	Foot and ankle	Jurij Štalc, Ankaran, Slovenia
10:15 – 10:35	20'	Current possibilities of reconstructive spinal surgery	Vladimir Kovač, Croatia
10:35 – 10:55	20'	Shoulder arthroscopy - tips and tricks for young orthopaedic surgeons	Boris Poberaj, Slovenia
10:55 – 11:15	20'	Marrow and inflammatory cells in subchondral bone remodeling in osteoarthritis	Jeroen Geurts and Thomas Hugle, Switzerland
11:15 – 11:30	15'	Discussion	
11:30 – 11:45	15'	Coffee Break	
11:45 – 12:30	45'	Workshop – symposia: Johnson & Johnson: Knee Rearthroplasty	

YOUTH DAY

Leader: TADIJA PETROVIĆ, Croatia

Chairmen: STJEPAN DOKUZOVIĆ, Croatia and IVAN BOHAČEK, Croatia

12:30 – 12:35	5'	Introduction	Tadija Petrović, Croatia
12:35 – 12:55	20'	Evidence based medicine principles in Orthopaedics and Traumatology	Vladimir Trkulja, Croatia
12:55 – 13:05	10'	Discussion	
13:05 – 13:35	30'	EFORT Fellowship	
13:45 – 14:00	15'	Closing ceremony	

HALL 2

NURSES DAY

Chairmen: VESNA KLJAJIĆ Croatia and KARMELA HRASTINSKI, Croatia

08:30 - 08:37	5' + 2'	Koštana banka	Vesna Kljaić, Croatia
08:37 - 08:44	5' + 2'	Sestrinska skrb bolesnika sa Ewingovim sarkomom nakon operativne	Marita Anzulović, Croatia
08:44 - 08:51	5' + 2'	Zadatci operacijske sestre kod lumbalne diskektomije minimalno invazivnim metodama	Vesna Svirčević, Croatia
08:51 - 08:58	5' + 2'	Zadaće operacijskih sestara kod intraoperativne primjene Gama detekcijske sonde	Marina Đakulović, Croatia
08:58 - 09:05	5' + 2'	Iskustva medicinskih sestara u OB Dubrovnik u svezi rada na ortopedsko traumatološkom odjelu	Neda Viočić, Croatia
09:05 - 09:12	5' + 2'	Reimplantacija totalne proteze kuka - uloga operacijske sestre tehničara	Željko Žuić, Croatia
09:12 - 09:19	5' + 2'	Kakvu sestru treba pacijent	Karmela Hrastinski, Croatia
09:19 - 09:26	5' + 2'	Sigurna i točna navigacija, snaga medicinske sestre u ortopediji	Kristina Krupljan, Croatia
09:26 - 09:33	5' + 2'	Sestrinske intervencije kod ugradnje intramedularne fiksacije _Supernail_	Željka Vondraček, Croatia
09:33 - 09:40	5' + 2'	Konzervativno liječenje humeroskapularne luksacije	Mihael Strle, Croatia
09:40 - 09:47	5' + 2'	Stručnost, učinkovita komunikacija i timski rad u operacijskoj sali	Blaženka Kozina, Croatia

NURSES DAY

Instructional course: Wound care treatment and management (Liječenje i njega rane)

Leaders: KATARINA DUGINA, Croatia and CECILIJA ROTIM, Croatia

Chairmen: ŽELJKA ROJE, Croatia and CECILIJA ROTIM, Croatia

10:00-10:05	5'	Introduction	Cecilija Rotim, Croatia
10:05 - 10:25	15'	Health care of the patient wound before and after plastic reconstruction surgery (Zdravstvena njega bolesnika kod zbrinjavanja rana prije i nakon rekonstrukcijskih zahvata)	Mirjana Parać, Croatia
10:25 - 10:40	15'	The use of modern compress within clinical practice due to burns and trauma patients (Primjena suvremenih obloga u kliničkoj praksi kod opeklinškog i traumatološkog bolesnika)	Valentina Štrbac, Martina Marić, Croatia
10:40-10:55	15'	Management of wounds with negative pressure therapy system (Zbrinjavanje rana primjenom sistema za negativni tlak)	Željka Roje, Croatia
10:55 - 11:10	15'	How to manage the wound and chose the right dressing (Kako procijeniti ranu i odrediti pravilan način previjanja?)	Željka Roje, Croatia
11:10-11:30	20'	Discussion	Cecilija Rotim, Croatia
11:30 - 11:45	15'	Coffee Break	
11:45-12:30	45'	Radionica (Workshop): Documentation of health care (Dokumentacija zdravstvene njege)	Biljana Kurtović, Croatia and Cecilija Rotim

NURSES DAY

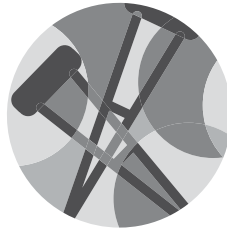
Round table: Standard operating procedures (SOP) in orthopaedics and traumatology (Standardni postupci u ortopediji i traumatologiji)

Leaders: KATARINA DUGINA, Croatia and CECILIJA ROTIM, Croatia

Chairmen: IVANKA BUDIŠEVIĆ, Croatia and NATALIJA HADŽIĆ, Croatia

12:00 - 12:05	5'	Introduction	Natalija Hadžić, Croatia
12:05 - 12:25	20'	Standard operating procedures in outpatient unit (SOP u ambulanti)	Dragana Barukčić, Croatia
12:25 - 12:45	20'	Standard operating procedures in surgical theaters (SOP u operacijskom traktu)	Nevenka Lukavski, Croatia
12:45 - 13:05	20'	Standard operating procedures on clinical wards (SOP na odjelu)	Sonja Staroveški, Croatia
13:05 - 13:25	20'	Outcome analysis of standard operating procedures implementation (Učinci provođenja SOP-a)	Ivanka Budiselić, Croatia
13:25 - 13:45	20'	Discussion	Ivanka Budiselić, Croatia; Natalija Hadžić, Croatia
13:45-14:00	15'	Closing ceremony	

ABSTRACTS



Thursday



Inovative autologous orthobiologic therapies - from basic concept to clinical application

Matjaž Vogrin, Robi Kelc

**Department of Orthopaedic Surgery,
University Medical Center Maribor,
Slovenia**

The development of orthobiologics has been rapid in recent decades and has already changed clinical practice in some therapeutical strategies. Better understanding of regeneration and healing processes of ligaments, tendons, bones and muscles has led to number of studies in aim of achieving more efficient therapy. Reports about the use of autologous platelet concentrates, stem cells, bone grafts, glucosamine and chondroitin are easily to be found in the literature. Despite this fact the consensus about the use of these orthobiologics does not exist, probably due to relatively large discrepancy of different studies. Still, platelet-rich plasma PRP and glucosamine are two of the most widely used orthobiologics in clinical practice. The use of PRP mainly focuses on therapy of relative avascular tissues, i.e. tendons, ligaments, cartilage and menisci; however there is an increasing tendency to use PRP also in muscle tissue in order to accelerate regeneration process and achieve more efficient healing with prevention of reinjuries. While the debate about the usefulness of these preparations continues, estimation is that they are being widely used in clinical practice.



Autologous Conditioned Serum

Tahsin Beyzadeoglu,

Halic University, Istanbul

INTRODUCTION

When transitioning into arthroplasty in an athletic population, traditional onlay designs may be less favorable as a primary procedure in varus malaligned knees as they remove and reapproximate the patient specific joint contour and are too invasive for limited joint arthrosis. In contrast, inlay arthroplasty is more joint preserving utilizing thin, contoured, and defect specific implants, however they inherently do not address malalignment. A previous basics science report described cartilage confluence over the edge of inlay components; however, reports from human observations have not been described in the literature.

OBJECTIVES

The purpose of this study was to examine the outcomes of inlay arthroplasty combined with HTO in an active population over the age of 45 years with mono- and bicompartamental arthrosis in varus knees. The results of second-look arthroscopy providing insight into the biological incorporation of these implants and their effects on opposing surfaces are presented.

METHODS

Patients presenting with varus malalignment of greater than 6 degrees and evidence of mono- or bicompartamental arthrosis underwent detailed preoperative evaluation. Cartilage defects and malalignment were assessed on preoperative radiographic and MRI imaging. Arthroscopic evaluation re-confirmed the indication before HTO and inlay arthroplasty procedures were carried out. Patients having ligament instability or subtotal - total meniscectomy were excluded. Clinical outcomes were evaluated with WOMAC and Knee Society scores pre- and postoperatively. HTO plate removal due to pes anserinus irritation was performed postoperatively at a mean of 14 months (12-19) in 26 knees. At the time of the diagnostic arthroscopy, implant stability, cartilage rim, and ratio of implant surface coverage were measured

and recorded. Opposing native cartilage surface were assessed.

RESULTS

Twenty-eight knees in 24 patients (19 males, 5 females) with a mean age of 54 years (range 45-67 years) were treated with a medial femoral condyle inlay arthroplasty. Half of the knees received a 15 mm, the other half a 20 mm implant. Ten of these knees had bicompartamental arthrosis and were treated with concomitant patellofemoral inlay arthroplasty. The preoperative mean varus mal-alignment was corrected from 9.8° (6°-11°) to zero degrees in all patients. The average follow-up was 43 months (28-64 months). Nineteen of the 24 patients were extremely active and included 2 marathon runners, 3 veteran volleyball players, 6 veteran basketball players and 8 tennis players. The mean time to return to full sports participation was 9 months (6-14 months). The mean WOMAC Score showed a significant improvement from 53 to 80.3 ($p < 0.05$) and the mean preoperative Knee Society Score equally improved from 50 to 85 ($p < 0.05$). No loss of correction was seen radiographically at last follow-up. At arthroscopy, peripheral area coverage of 15 mm implants was 12% (range 5%-25%), 20 mm implants showed 9% (range 5%-15%) and trochlear implants demonstrated 20% (range 10%-40%). No erosive kissing lesions were noted.

CONCLUSIONS

High tibial osteotomy combined with inlay arthroplasty is a promising treatment method for active patients over the age of 45 years with significant varus malalignment and mono- and bicompartamental arthrosis. The contoured defect fill combined with neutral correction may avoid the negative effects of overcorrection in the contralateral compartment. Inlay arthroplasty demonstrates favorable incorporation into the host implant bed and does not seem to pose any immediate deleterious effects on opposing articular cartilage.

KEYWORDS

Inlay Arthroplasty, Osteotomy, Cartilage, Knee



Mesenchymal stem cells in orthopaedic tissue engineering

Inga Marijanović

Faculty of Science University of Zagreb

The main goal of regenerative orthopaedics is to provide better treatments for diseases and injuries affecting musculoskeletal system. There are three main approaches of regenerative orthopaedics – activation of endogenous stem cells, cell therapy and tissue engineering. Instead of replacing damaged tissues with prosthetic and allograft material, tissue engineering aims at production of autologous 3D tissue graft. There are three main constituents of the tissue engineering system – cells, scaffold and environment. Mesenchymal stem cells (MSCs) are adult stem cells that constitute a variety of adult tissues and were found to differentiate to several mesenchymal tissues including bone, cartilage, stroma, adipose and connective tissue, muscle and tendon. Therefore, MSCs are good candidates for the development of various therapeutic modalities in orthopaedics. Various range of matrices have been investigated as a support of MSC growth in 3D culture, including carbohydrate-based scaffolds (agarose, alginate, chitosan, and hyaluronate), protein-based scaffolds (collagen, fibrin and gelatin) and artificial polymers (polyglycolic acid, polylactic acid, polyethylene glycol and polycaprolactone). MSCs loaded on scaffold need an adequate bioactive signal that will induce their differentiation into desired cell type.

This review aims to highlight the concepts in bone and cartilage tissue engineering with the special focus on mesenchymal stem cells, their properties, source, isolation methods and environment requirements needed for the successful graft production.



Bioreactor-based cartilage engineering

Alan Ivković, Damir Hudetz

**Department of Orthopaedic Surgery,
University Hospital Sveti Duh**

The restoration of damaged articular cartilage remains one of the biggest challenges in modern clinical orthopaedics. There is no pharmacological treatment that promotes the repair of the cartilage, and the non-operative treatment inevitably leads to the development of premature osteoarthritis. Current treatment modalities include bone marrow stimulating techniques (microfracture), autologous chondrocyte implantation (ACI), and transplantation of osteochondral grafts, each having their own benefits and shortcomings. Although effective in relieving pain and improving joint function, original versions of these modalities have failed to regenerate true hyaline cartilage, and it is necessary to introduce improvements to the existing methods, as well as to develop new and innovative approaches. The *in vitro* production of osteochondral grafts starting from autologous cells combined with three-dimensional porous biomaterials, is a promising approach for the treatment of osteochondral defects. However, the quality of *ex vivo* generated cartilage and bone-like tissues is currently restricted by a limited understanding of the regulatory role of physicochemical culture parameters on tissue development. By allowing reproducible and controlled changes in specific biochemical and biomechanical factors, bioreactor systems provide the technological means to reveal fundamental mechanisms of cell function in a three-dimensional environment and the potential to improve the quality of engineered tissues. In addition, by automating and standardizing the manufacturing process in controlled closed systems, bioreactors could reduce production costs and thus facilitate broader clinical impact of engineered osteochondral grafts.



The biological tropism of hyaline cartilage in different hosts

Mahmut nedim Doral, K Büyükdoğan, O Bilge, E Turhan, G Dönmez, G Huri, MF Sargon, P Huri, K Kösemehmetoğlu, D Kaya

Hacettepe University, Turkey

PURPOSE

There are many *in vitro* studies about chondrocyte cultures and proliferation. Our aim is to follow *in vivo* chondrocytes proliferation in different hosts; omentum, peritoneum, muscle, paratenon and synovium of the knee joint of rabbits.

Our hypothesis is to clarify some tissues might promote and enhance chondrogenesis in living organisms. We aimed to evaluate the chondrogenetic stimulation potential of various types of soft tissues such as omentum, peritoneum, muscle, Achilles paratenon and synovium of the knee in a rabbit model (1).

METHOD

Forty five New Zealand rabbits were used with the permission of the university ethical committee. Standard sizes of osteochondral grafts were harvested from right knees. Five groups were formed and graft samples were placed securely into the omentum (N=10), peritoneum (N=10), muscle (N=10), Achilles paratenon tissue (N=10) and synovium of the knee (N=10). Control group (N=5) was native distal femoral condylar cartilage of the rabbits. After five months, samples were collected, evaluated histologically and quantification of the chondrocytes was performed by using the camera lucida system of a light microscope (2). Microscopic sections were counted under 200X magnification at a constant area of 0.01mm² at 10 different areas for each section. Additionally; the proportions of empty and cellular lacunae were calculated with the light microscope (3).

RESULTS

The mean number of chondrocytes under 200X magnification at a constant area of 0.01mm² were 15.7 in control group, 14.7 in omentum, 20.2 in synovium, 9.8 in muscle, 9.0 in Achilles paratenon and 15.4 in peritoneum respectively.

The synovium group was statistically higher than the control group (Mann-Whitney U-test, $p < 0.05$). Omentum, peritoneum and muscle groups were not statistically different from control group (Kruskal-Wallis, $p > 0.05$) and Achilles paratenon group contained the lowest amount of mean chondrocyte count according to control and peritoneum group ($p = 0.002$). Empty and cellular lacunae ratios were evaluated and lacunae in peritoneum samples were found to be filled with living chondrocytes in 98.2% of the lacunar cavities. In peritoneum, synovium and control groups, the number of alive chondrocytes in lacunae was found to be significantly higher, when compared to the other groups ($p = 0.010$).

TAKE HOME MESSAGE

After transplantation of osteochondral autografts firstly inside of the abdominal region, grafts sustained viability and cellularity, and secondly inside of the synovium of the knee, grafts sustained viability and increased cellularity, in histological manner. As a result, this study demonstrates that intra-abdominal region and synovium of the knee may have the biological potential to be used as an *in vivo* culture medium for osteochondral tissue growth in animals. The next step will be the functional testing of the new cartilage.

1) Bilge O, Doral MN, Atesok K, Atay OA, Donmez G, Turhan E, Uzumcugil A, Leblebicioglu G, Kaya D, Bilgili H, Sargon M. The effects of the synovium on chondrocyte growth: an experimental study. *Knee Surg Sports Traumatol Arthrosc.* 2012 Jul;20(7):1398-403

2) Sargon MF, Celik HH, Aksit MD, Karaağaoğlu E. Quantitative analysis of myelinated axons of corpus callosum in the human brain. *Int J Neurosci.* 2007 Jun;117(6):749-55.

3) Williams SK, Amiel D, Ball ST, Allen RT, Tontz WL Jr, Emmerson BC, Badlani NM, Emery SC, Haghghi P, Bugbee WD. Analysis of cartilage tissue on a cellular level in fresh osteochondral allograft retrievals. *Am J Sports Med.* 2007 Dec;35(12):2022-32.



Multiligamentous injuries of the knee

**Friederich NF 1,2 Hirschmann MT2,
Zimmermann N2, Müller We2, Hudetz
2,3, Candrian C2, Rychen T2,**

**1.Center of Biomechanics, University of
Basel, CH-4056 Basel, Switzerland**

**2.Department of Orthopaedic
Surgery and Traumatology, CH-4101
Bruderholz, Basel, Switzerland**

**3.University Hospital Sveti Duh, HR
1000- Zagreb**

Background: Traumatic knee dislocations represent a deleterious injury, particularly for athletes having highest demands on their knee function.

Hypothesis/Purpose: Our aim was to analyze the long-term outcomes and return to sport of elite athletes treated surgically according to a standardized treatment protocol and to identify predictive factors for a successful outcome. This presentation includes too a review of the current literature.

Study Design: Retrospective consecutive case series

Methods: All elite athletes treated surgically (n=26) underwent an open complete single stage reconstruction/refixation or repair of the cruciates and collateral ligaments including the posterolateral corner. Return to sport and activity level preinjury and postoperatively were recorded. With a mean follow up of 10 ± 8 years 24 patients (92% follow up rate) were evaluated for visual analogue scale (pain, satisfaction), instrumented anterior-posterior laxity (KT-1000), International Knee Documentation Committee form IKDC, American Knee Society score and Lysholm and Tegner score. Standard weight bearing and stress radiographs were performed.

Results: 79% of patients returned to their previous sport in mean time 8 ± 8 months with 2/5 of them returning to preinjury levels. 8% had a VAS pain > 3 . Most patients had a full range of motion, 13%

showed a flexion deficit $> 15^\circ$ and 8% an extension deficit $> 10^\circ$. The mean side-to-side differences for anterior and posterior laxity were 2.5 ± 1.3 mm and 2.5 ± 1.2 mm respectively.

The total IKDC score was normal in 16 and abnormal in 8 patients. The mean Lysholm score was 84.7 ± 18.4 . The median Tegner score decreased from 9 (7-10) to 7 (2-10). The mean American Knee Society score was 187.5 ± 13.0 . The mean side-to-side differences in stress radiographs in 30° and 90° flexion were $1.0\pm 1.5/1.5\pm 4.1$ mm and $2.5\pm 5.1/3.0\pm 5.5$ mm respectively. Patients who underwent treatment longer than 20 days from injury demonstrated a poorer outcome as measured by satisfaction and relative Tegner score. This group was also unsuccessful returning to sport compared to patients treated earlier.

Conclusions: Athletes treated by early open complete single stage reconstruction within 20-40 days from injury showed favorable results to those treated later. Although 2/3 of patients had good functional outcome scores and stress radiographs proved ligamentous stability and longevity, only 2/5 of athletes reached their identical sport activity level.



REFERENCES:

1. Martinek V, Steinbacher G, Friederich NF, Müller W: Operative treatment of combined anterior and posterior cruciate ligament injuries in complex knee trauma. *The American Journal of Knee Surgery*, Vol 13(2):74-82, 2000
2. Hirschmann MT, Iranpour F, Müller W, Friederich NF: Surgical treatment of complex bicruciate knee ligament injuries in elite athletes: What outcome can we expect. *Am J Sports Med* 38:1103-1109, 2010; DOI 10.1177/0363546509356978 (March 9, 2010)
3. Hirschmann MT, Zimmermann N, Rychen T, Candrian C, Hudetz D, Lorez LG, Ameler F, Müller W, Friederich NF: Clinical and radiological outcomes after management of traumatic knee dislocation by open single stage complete reconstruction. *BMC Musculoskeletal Disorders* 2010. 11:102. DOI 10.1186/1471-2474-11-102
4. Adler T, Friederich NF, Amsler F, Müller W, Hirschmann MT: Clinical and radiological long-term outcome after posterior cruciate ligament reconstruction and nonanatomical popliteus bypass. *International Orthopaedics (SICOT)*: DOI 10.1007/s00264-014-2515-7 (published online September 17, 2014)
5. Friederich NF, Widmer H, Müller W, Schwamborn T, Hauswirth J: Nevjerojatan „comeback“ mlade Janice Kostelic - 12 mjeseci nakon luksacije koljena povratak na svjetski vrh – Unbelievable comeback of young Janica Kostelic return to the top 12 months after a complex knee injury. *Hrvatski Sportskomedicinski Vjesnik*, Godiste 16, Broj 1-2-3, Str. 1-68:60-64, Zagreb 2002 (printed 2003)



Patellofemoral joint stabilization

Damir Hudetz

University hospital Sveti Duh, Zagreb

Specialty hospital St.Catherine, Zabok

Patellofemoral joint is of utmost importance for the function of knee flexion and extension. Tracking in the patellofemoral joint is commonly affected with wide range of problems ranging from mild lateral maltracking and tilt to instability with subluxation and dislocation. Patients with instability have relatively high probability of recurrence. Each episode of dislocation or subluxation contributes to a number of significant problems, including persistent knee pain, functional limitations, decreased athletic performance and arthritic degeneration of the patellofemoral joint. Surgical treatment plays major role in the treatment in cases of recurrent dislocation whereas systemic physical therapy has important role in patients with mild lateral maltracking. Patellofemoral instability with dislocation has usually lateral direction. The incidence of this injury has been shown to be around 6 per 100000 with the highest incidence occurring in the 2nd decade of life.

Tracking and stability of the patellofemoral joint is influenced by osseous anatomy of patella and trochlea. Any dysplastic changes of patella and trochlea can lead to instability. The shape of trochlea closely matches the articular shape of the patella providing restraint for excessive lateral movement of the patella. Patellofemoral dysplasia has been classified by Dejour et al. Patella alta with increased length of the patellar tendon contributes to patellar instability.

Soft tissue structures important for the stability of the patellofemoral joint include lateral retinaculum, iliotibial band and vastus lateralis muscle on the lateral side and medial retinaculum, medial patellofemoral ligament and vastus medialis muscle on the medial side. Weakness or disruption of the medial stabilizers can lead to lateral instability especially at flexion angles between 0-30 degrees. Tightness or excessive force by the lateral stabilizers like lateral patellar retinaculum or iliotibial band with its fibers can produce abnormal patellar tilt and maltracking. Dynamic stabilizers both on medial (vastus medialis obliquus) and lateral side (vastus lateralis muscle) contribute to stability.

Lower extremity malalignment influences patellofemoral joint stability. Increased femoral anteversion with internal rotation of the femoral condyle, external tibial torsion and valgus femoral alignment contribute to femoropatellar maltracking.

Femoropatellar stabilization treatment depends on clinical presentation. The patient may present with instability without pain, pain without instability or instability and pain as a consequence of all anatomical modalities and trauma. Usually first time dislocations are treated conservatively. Recurrent dislocations are treated with surgical therapy adjusted to specific condition. In recent years after introduction in 1994 reconstruction of the MPFL has gained popularity with excellent results. This treatment can be combined with different osteotomy type in order to address underlying osseous pathology. Tibial tubercle osteotomies in various planes, corrective osteotomies of the femoral axis in terms of varisation and derotation or trochleaplasty can successfully stabilize patella with respect to trochlea and reduce pain.



Corrective osteotomies around the knee joint

**Philippe Neyret, Jeremy Cognault,
Sebastien Lustig, Elvire Servien.**

**Hospices de Lyon Croix Rousse - Centre
Albert Trillat, France**

INTRODUCTION

Before the introduction of the total knee arthroplasty into clinical practice, an osteotomy was the treatment of choice for osteoarthritis. Today however an osteotomy is considered technically difficult and demanding for the patient. Nevertheless, in our daily practice osteotomies are a valuable option for arthritis of the knee, as they could allow a return to a high level of activities including sports. An osteotomy delays the need for a total knee prosthesis in young active patients. Obviously the following variables have to be taken into account: the type of arthritis, clinical and radiological criteria, and patient expectations.

MATERIAL AND METHODS

A review of literature (22 articles, more than 500 patients, 10 years follow-up) about common frontal osteotomies as HTO by closing or opening wedge will be presented, such as our own experience about uncommon osteotomies.

The results of associated osteotomies with cruciate or lateral ligaments reconstruction, mosaicplasty or other kind of surgery will be exposed and illustrated by some of our cases.

RESULTS

Gold standards for HTO seem to be locked plates. Poor outcomes appears when there is: severe articular destruction, under-correction or over-correction, advanced age, patellofemoral arthrosis, noticeably decreased range of motion, previous arthroscopic debridements, joint instability, loss of correction and lateral tibial thrust. BMI is a controversial factor. HTO is effective for long periods but results do deteriorate over time.

Sagittal osteotomies can improve function and pain knee recurvatum (bony or soft tissue recurvatum).

CONCLUSION

In this presentation, we will not only discuss the criteria that make us chose an osteotomy over a total knee prosthesis for degenerative knee pathology but also which type of osteotomy is indicated in the different clinical situations.



Indications and portal placement

Tomislav Smoljanovic

**Department of Orthopaedic Surgery,
University Hospital Center Zagreb,
School of Medicine, Zagreb University,
Zagreb, Croatia**

Since the first description of anterior paratrochanteric puncture used for scoping of two adult cadaver hips made by Burman in 1931 hip arthroscopy has passed huge development related to its indications, patient positioning and portal placement. For instance, James Glick and Thomas Sampson introduced lateral decubitus position rather than the supine position at the beginning of 1980s. Ejnar Eriksson estimated distraction forces required for assessment of central compartment of the hip. Lanny Johnson described anatomical landmarks and techniques of needle placement. French rheumatologists, Dorfmann and Boyer, developed a technique without distraction for entry into the peripheral compartment of the hip in 1988. Technical suggestions for the optimal use of supine patient positioning were provided by Thomas Byrd in early 1990s. Mark Phillipon later modified the supine positioning by placing the extremity in 15 degrees of internal rotation, 10 degrees of flexion, neutral abduction, and 10 degrees of lateral tilt. The "periphery first" technique has been further developed by Michael Dienst and his "ballooning" technique which preserves hip capsule while creates sufficient space under it for treatment in the peripheral compartment. Recently, Frederic Laude described new operative technique that consists

of performing an extra-articular capsulotomy under endoscopic control before exploration of the hip joint. The similar capsulotomy is done by Bryan Kelly, but the extra-articular capsulotomy is performed after the exploration and treatment within central compartment of the hip is finished. There are several ways how to name (and position) some of portals used for hip arthroscopy. The anterolateral (AL; the Burman's anterior puncture) portal is the pillar of hip arthroscopy as it is useful for visualization of central, peripheral and peritrochanteric compartments. The other commonly employed (and named) portals are posterolateral (PL) and anterior portal (AP). Beside those three portals, surgeons use proximal and distal anterolateral and mid-anterior portals. A common indication for hip arthroscopy has been the presence of loose bodies causing mechanical symptoms. The most common intra-capsular disorder treated by hip arthroscopy these days is femoroacetabular impingement usually including labral and/or cartilage lesions. Other indications include extra-capsular disorders that affect the iliopsoas tendon and the tensor fasciae latae (with or without inclusion of their bursas) or disorders causing extra-capsular impingement. However, technique and applications of hip arthroscopy are still evolving and frontiers are not reached yet.



Femoroacetabular impingement

Saša Jankovic

KB Sveti Duh, Zagreb, Croatia

Femoroacetabular impingement is an anatomic hip condition that can lead to labral pathology, hip pain and arthritis. Two types of FAI were described. Cam impingement occurs when a prominence of femoral neck is forced under the acetabular rim with hip motion. Pincer impingement is caused by acetabular over-coverage of the femoral head. Hip arthroscopy can be a successful intervention used to address this condition. Arthroscopic techniques continue to evolve and allow for a reproducible and effective algorithm for addressing this condition.

Arthroscopic treatment of early oa of the elbow

Martin Mikek

Artros, Center for orthopedic surgery

Elbow osteoarthritis is a relatively uncommon condition manifested by decreased joint range of motion, pain and locking. Main predisposing factors are heavy manual labor, trauma and rheumatoid arthritis. Progression of symptoms often requires surgical intervention for improvement of function. Advances in elbow arthroscopy in the recent decade have offered new possibilities for less invasive joint preserving treatment of this debilitating condition.

Arthroscopic treatment of elbow osteoarthritis is principally based on the classic Outerbridge-Kashiwagi procedure with some variations. Resecting the arthritic radial head is not considered essential any more to obtaining an excellent functional outcome. Improved joint visualization, less extensive soft tissue dissection and more controlled debridement all potentially contribute to faster recovery and improved functional results.

Several short term and some long-term studies have provided evidence that arthroscopic debridement of the arthritic elbow can provide reasonable pain relief and improve joint motion. Subjective results of this treatment seem even to surpass objectively measured parameters.

Radial head fractures: Indications and outcomes for radial head.

Popovic Nebojsa

Aspetar Orthopaedic and Sports Medicine Hospital-Qatar

Radial head fracture is the most common elbow fracture in adults. The mechanism of injury is commonly a fall on the outstretched hand. It is well recognized that the radial head is an important secondary stabilizer of the elbow. The proper management of comminuted fractures of the radial head is difficult and controversial. Surgical options included internal fixation, excision, or excision and replacement of the head. The choice among those options often remains debatable.

The metal radial head prosthesis was developed to restore elbow stability and permit early joint mobility. There are two different types of metal radial head prostheses; loose mono-block prosthesis and a bipolar prosthesis. In our study on eleven consecutive adults patients treated with floating radial head prosthesis for acute RHF (Radial head fractures) associated with elbow dislocation the short-term (mean 32 month, range 24 to 56 months), the clinical results have been promising.

We also published on the mid-term results (8, 4 years post-operatively) in 51 consecutive patients with a bipolar RHP. This study confirms satisfactory mid-term clinical results. Radiographic changes occur over time, possibly reflecting osteolysis at the bone-cement interface in a number of patients.

Clinicians should be aware that one possible long-term drawback of use of the bipolar radial head prosthesis is a major loss of bone in the area of the stem, which warrants caution regarding the use of this prosthesis in young and active individuals.

We suggest randomized control trails to determine the optimal treatment strategy for these patients.

Partial shoulder endoprosthesis

Duilio Peroša

Department of Traumatology, General hospital Izola

The aim of this paper is to present the experience gained at Trauma Division – Surgical Department of Izola General Hospital in introducing shoulder arthroplasty as a method of treatment for proximal humerus fractures in elderly trauma patients.

Osteosynthesis in four part proximal humerus fracture, especially those in elderly osteoporotic patients, gave disappointing results. A need for a better solution to this problem in elderly arose and was in part resolved by the introduction of trauma shoulder arthroplasty.

Introducing shoulder arthroplasty as a new technique in fracture treatment needed additional othopaedic training with shoulder expert surgeons and in cadaveric models. When starting one's own cases questions like optimal humeral stem height and correct rotator cuff tension arose. First partial shoulder arthroplasties – including those done under expert supervision – were overtight in rotator cuff reinsertion. As a consequence, proximal implant migration and loss of ROM linked to severe pain occurred. Due to this experience with partial shoulder arthroplasty, reverse total shoulder arthroplasty in patients over 65 years was started. In six year period of implanting reverse total shoulder prosthesis we find that these gave better functional results when compared to partial shoulder prosthesis in trauma patients. Partial shoulder prosthesis still remains the implant of choice in patients 50-65 years old in which arthroplasty is considered as a treatment option.

Total Shoulder Endoprosthesis

Puneet Monga

Wrightington Hospital, UK

Following the initial implantation of the first shoulder replacement in the second half of the 19th century, the first "modern" shoulder replacement was pioneered by Dr Charles Neer in the 1953 for proximal humeral fractures. There have been significant design changes in the humeral and glenoid component over the last 60 years along with changes in the materials used.

Total shoulder endoprosthesis is primarily indicated in end stage chronic shoulder conditions such as osteoarthritis, rheumatoid arthritis, osteonecrosis, instability arthritis and post traumatic arthritis where other forms of treatment have either failed or unlikely to be of benefit in view of the advanced disease. Contra indications for an unconstrained total shoulder endoprosthesis include axillary nerve palsy, active infection and poor bone stock.

Preoperative Xrays and CT scans are essential for assessing bone stock. Following the commonly used deltopectoral approach, the subscapularis is either tenotomised or raised as an osteotomy. Adequate soft tissue releases are needed prior to using either a pegged or keeled glenoid component. Various stem designed are available and described during the talk.

The outcomes following total shoulder replacement are superior to hemiarthroplasty without any increase in complications or revisions. Excellent to good results can be expected in a vast majority of patients with osteoarthritis and rheumatoid arthritis with relatively inferior outcomes in post-traumatic arthritis or fixed dislocations.



Reverse shoulder endoprosthesis

Ludwig Seebauer

Center of Orthopaedics, Traumatology and Sportsmedicine Klinikum Bogenhausen

Since its introduction 25 years ago the Grammont type of reverse shoulder arthroplasty has proven to be a beneficial operative treatment for different type of difficult to treat shoulder pathologies as cuff tear arthropathy, failed shoulder prosthesis, posttraumatic or postinfectious deformities, massive pseudoparalytic rotator cuff tears in the elderly and acute and chronic severely distorted proximal humerus fractures. A reliable pain relief and improvement in function is characteristic in this type of shoulder arthroplasty despite of difficult pathologic conditions is characteristic. In the first published clinical series about reverse shoulder arthroplasty a relatively high number of complications and revisions were reported. More recent studies clearly disclosed that with a careful preoperative planning and operative technique the rate of potential complications could be dramatically decreased.

The major complications are: dislocation, infection, periprosthetic fracture and glenoid notching. The prerequisite for a successful and long-lasting reverse shoulder arthroplasty is a secure and firm fixation of the glenoid and humeral component in proper position, an intact deltoid and a functioning axillary nerve.

A detailed analysis of the bony geometry of the glenoid and potential bony defects is highly important. The glenoidbaseplate positioning as low as possible to the inferior glenoid rim is critical. If bone defects exists bone grafting is necessary to restore the glenoid joint line in the coronal plane. Both maneuvers are decisive for primary stability of the glenoid component and a good long term functional result. A low positioning of the glenosphere with an inferior overlap of about 4 mm is significantly reducing rate and degree of inferior notching.

Also an adequate soft tissue release of asymmetric scarring around the joint and positioning the implant with proper version and height to get appropriate tensioning of the deltoid and the residual cuff is important for avoiding postoperative

dislocations. A greater glenosphere diameter as large as individually possible give more range of motion and stability. Finally the reattachment of the subscapularis is helpful to avoid complications. The use of a superior deltoid split approach and avoiding subscapularis detachment is the most beneficial method to avoid dislocations.

Infection could be avoided with a proper perioperative antibiotic prophylaxis and draping the operation field with iodinated incision drapes. Be aware of preexisting contamination in previously operated patients or in patients with a history of multiple operations.

Following consequently a proper operative technique and observing potential risk factors like previous operations, osteopenic bone, preexisting bony defects on the acromion, glenoid and humerus in combination with a meticulous soft tissue preparation and release helps to reduce the complication- and revisionrate to lower level than with anatomic shoulder arthroplasty.

REFERENCES

1. Grammont PM & Baulot E: Delta shoulder prosthesis for rotator cuff rupture. *Orthopaedics* 16:65-68, 1993
2. Boileau P, Watkinson DJ, Hatzidakis AM, Balg F. Grammont reverse prosthesis: design, rationale, and biomechanics. *J Shoulder Elbow Surg* 14 (1 Suppl S): 147-161S, 2005
3. Seebauer L, Walter W, Keyl W. Total Shoulder Replacement in Defect Arthroplasty. *Operat Orthop Traumatol* 17: 1-24, 2005
4. Boileau P, Watkinson D, Hatzidakis AM, Hovorka I, Neer Award 2005: The Grammont reverse shoulder prosthesis: results in cuff tear arthritis, fracture sequelae, and revision arthroplasty. *J Shoulder Elbow Surg* 15: 527-540, 2006
5. Zumstein MA, Pinedo M, Old J, Boileau P. Problems, complications, reoperations, and revisions in reverse total shoulder arthroplasty : A systematic review. *J Shoulder Elbow Surg* 20: 146-157, 2011

Displaced femoral neck fractures: is there a standard of care?

Srećko Sabalić, Ana Čizmić

University Hospital Centre Sestre milosrdnice, Zagreb ,Croatia

Displaced femoral neck fractures (FNF) have a significant rate of poor outcomes due to a high incidence of complications, among which nonunion and AVN of the femoral head are the two most commonly encountered and intractable. Treatment options include closed reduction and internal fixation or ORIF with different constructs, hemiarthroplasty, and THA. Despite advances in treatment, the reported incidence of nonunion after internal fixation ranges from 15% to 33%. None of the implants had significantly superior results for outcomes related to fracture healing, osteonecrosis, wound infection, pain scores, reoperation rate, use of walking aids, periprosthetic fracture, or mortality. Although multiple screw fixation with cannulated screw is most common, and the use of DHS may be associated with slightly longer operating times and increased blood loss, implant selection will continue to be determined based on surgeon preference and experience. The biomechanical challenges of femoral neck fixation and the vulnerability of the femoral head blood supply lead to a high incidence of non-union and osteonecrosis of the femoral head after internal fixation of displaced FNF. Anatomic reduction and stable internal fixation are essentials in achieving the goals of treatment in young patient population. We do not recommend the routine use of capsulotomy for FNF given the lack of evidence to support the development of osteonecrosis from intracapsular hematoma. Managing displaced FNF with THA in the cognitively intact elderly patient is well-supported in the literature. Revision surgery rates and mortality rates were similar after THA and HA treatment for displaced FNF in healthy elderly. None of these treatment options appeared to be superior with respect to postoperative minor or major complications. Risk of dislocation favoured HA. Estimates for function, pain and quality of life are less clear, but tend to be in favour of THA.

Periprosthetic femoral fractures : a review of classification and Current treatment

Nemanja Slavković

Institute for Orthopaedic surgery
"Banjica", Serbia

Fractures of the femur after total hip arthroplasty are special diagnostic and therapeutic challenge, since, in most cases, it is necessary to coordinate and implement two different surgical philosophy - traumatology and arthroplasty, during one operation. The successful resolution of this problem can only be reached by surgeon or surgical team with enough experience and knowledge in both of these areas. The incidence of these injuries is increasing with a tendency to further increase, primarily due to the increasing number of primary and revision arthroplasty of the hip. Decisions concerning treatment are made primarily by analyzing the localization and other characteristics of a fracture, but at the same time, by taking into account the type and stability of existing implants. In most cases, patients with periprosthetic fractures are elderly with numerous comorbidities, less mobile and with poorer quality of bone tissue. A particular problem is the situation after revision arthroplasty of the hip, when the ability to successfully complete surgical reconstruction is limited by often present bone defects. The final decision is, despite everything, made during the operation, since the intraoperative findings are often worse compared to the preoperative radiography, based on which the planning of surgical procedures is most often implemented. Periprosthetic femoral fractures can be treated successfully only in well-equipped, specialized orthopedic institutions. Detailed preoperative preparation, perioperative and postoperative monitoring, well-trained medical staff and varied choice of osteosynthetic materials and endoprosthetic systems are required.



Acetabular fractures

Gusic Nadomir

**Department of Traumatology and
Orthopaedics, Pula County Hospital,
Pula, Croatia**

Acetabular fractures are often complex, with multiple fragments and secondary fracture lines. Accurate radiographic diagnosis and classification are the cornerstones of effective management. The classification system of Judet and Letournel has led to improved management of such injuries. The ten patterns are divided into five elementary and five associated patterns. Column fractures divide the acetabulum into front and back halves. Transverse fractures divide the acetabulum into top and bottom halves. Bicolunar family involve two columns. It is very variegated and include one elementary and a four associated patterns: elementary transverse fracture, associated transverse-posterior wall, T-shaped, associated anterior-posterior hemitransverse and associated both column (BC) fracture. To be classified as a true BC fracture no articular surface remains attached to the innominate bone.

Surgery is recommended if trauma leads to an acetabular joint step or gap more than 2 mm. Essential in surgical treatment is choosing the surgical approach that will provide best access to the technically most demanding parts of a complex fracture. Matta indicated that the choosing of the surgical approach for the four fracture types that involve two columns was not consistent and should be individualized to the fracture pattern and to the surgeon's experience. Because these fractures are commonly occurring, it is obvious how important is the problem of choosing of the most appropriate surgical approach.

Conclusion of our study of 157 surgically treated acetabular fractures that involve two columns is that good preoperative planning, proper equipment, advanced surgical techniques and surgical experience can lead to a more consistent view of the selection of the single surgical approaches. The usage of combined and extensile surgical approaches, which are associated with a greater number of complications, could be significantly reduced. T-types (Tr, T-shape, Tr+PW) fractures can be successfully operated through the single posterior approach, with only one-exception Tr+AW fractures, for which we suggest the anterior approach. For BC fractures we recommend single anterior approach with only one exception BC+PW fractures, for which we suggest the combined approach.

LCP system for proximal humeral fractures

Vladan Stevanović

Institute for orthopaedic surgery
"Banjica"

What can we expect in surgical treatment of proximal humerus fractures ?

Earlier techniques for treating vary and include fixations using tensionbands, percutaneous pins, bone suture, T-plates, intramedullary nails, hemiarthroplasty. Complications of these techniques include cutout or backout of the screws and plates, avascular necrosis, nonunion, malunion, nail migration, rotator cuff impairment, and impingement syndromes. Insufficient anchorage from conventional implants may lead to early loosening and failure, especially in osteoporotic bones.

On the other hand, the locking compression plate fixation provides greater angular stability than do conventional implants. It works as a locked internal fixator and provides better anchorage of screws in osteoporotic bone, with good functional outcomes. Complications include screw perforations into the glenohumeral joint or head, screw loosening and backing out, secondary implant dislocations from the humeral head, avascular necrosis of the humeral head, pseudoarthrosis with a broken plate, subacromial impingement requiring plate removal, nonunion, malunion due to loss of purchase in the humeral head, broken distal screws with separation of the plate from the bone, and transient axillary nerve palsies.

What are the advantages of LCP systems, how to avoid complications and how to achieve good functional outcome in older and younger patients as well? Do we finally have ideal implant for proximal humerus fractures, or not? Do we need implant after quality reconstruction and grafting?

Improving knowledge in proximal humerus fracture treatment will help us in this dilemmas!

Endoscopic microdiscectomy

Krešimir Rotim, Darko Stipičić

University Hospital Centre Sestre
milosrdnice, Zagreb, Croatia

Introduction: Selective endoscopic discectomy (SED) is a minimally invasive procedure for removing lumbar disc extrusions (LDH). We present our experience in treating LDH using this surgical technique.

Patients and methods: From February 2009 to April 2014, in a five-year period, we operated 104 patients. There were 33 patients operated at the level L5/S1, 49 at the level L4/L5, 20 at the level L3/L4 and 2 patients at the level L2/L3. Patients were evaluated using Oswestry Disability Index (ODI), and VAS one year after the operation and compared to a group of 50 patients operated by standard microsurgical discectomy.

Results: Good or very good results were achieved in 86% of the patients while unsatisfactory results were present in 14% of the patients in the SED group. In the SED group there were 7 open reoperations because of re-extrusion or residual extrusion, there were no postoperative infections. Two SED operations were converted to open procedure due to epidural venous hemorrhage.

Conclusion: Our results match those described in the literature. SED is acceptable and effective alternative to standard, open microdiscectomy that might offer less postoperative back pain and faster recovery but does not provide different overall outcome one year after the surgery.



Minimal invasive lumbar discectomy

Tomislav Sajko, Rotim K, Borić M, Stipić D, Radić I, Božić B, Živković DJ

Department of Neurosurgery, „Sestre milosrdnice“ University Hospital Center, Zagreb, Croatia

AIM

Back pain is the second leading symptom that prompts visits to physicians. As many as 80% of adults experience at least one episode of low back pain during their lifetime, and 5% experience chronic problems. The focus of this study was to examine the functional outcome of minimal invasive treatment of herniated lumbar discs.

PATIENTS AND METHODS

Prospective randomised study has been started January 1st 2012. at the Department of Neurosurgery „Sestre milosrdnice“. Only patients with single level lumbar disc protrusions or extrusions have been included. Patients with spinal canal stenosis, lateral recess stenosis, patients with accidental finding like synovial cysts or reoperated patients have been excluded. Surgery was proposed when conservative treatment had failed after 12 weeks or when progressive neurological deficits burdened the patients. The informed consent was given for „lumbar microdiscectomy“. Microdiscectomy using the Met-Rx retractor system was performed. Each patient has been completing the Oswestry disability index (ODI) questionnaire before surgery and at one and three months postoperatively. A visual analog scale (VAS) form for back and leg pain and the degree of leg paresthesias has been filled by patients before surgery and each day after surgery until hospital dismissal. Also the VAS back and leg pain form, the degree of leg paresthesias and analgesics consumption has been followed at one and three months postoperatively.

RESULTS

124 patients were operated from 2011-2015 using Met-Rx tubular retractor system. The preoperative median ODI was 55%. The postoperative ODI was 25%. The intensity of preoperative leg pain was similar in all patients. The lowest VAS score was reached at dismissal. The preoperative back pain was also similar in all patients. Following surgery the VAS score decreased to 1,2. The degree of leg paresthesias were similar in patients preoperatively. Postoperative leg paresthesias were higher. The mean postoperative analgesics consumption was 0,6.

CONCLUSION.

Lumbar microdiscectomy improves pain and ODI irrespective of the type of approach and retractor used. However, the postsurgical analgesic consumption is significantly less if a tubular retractor is inserted.



Posterior lumbar interbody fusion (plif)

Vorsic Matjaz

**University Hospital Maribor, Ljubljanska
5, 2000 Maribor, Slovenia**

AIM OF THE STUDY:

The surgical treatment of the degenerated lumbar spine may require the transpedicular fixation together with fusion in order to achieve the rigid stability of the affected motion segment. PLIF procedure is still a golden standard although other procedures are gaining on popularity such as Transforaminal Interbody Fusion (TLIF), eXtreme Lateral Interbody Fusion (XLIF) etc.

The aim of the study was to determine the clinical results and the outcome in the patients treated for the lumbar spondylolisthesis using the standard PLIF procedure or minimally invasive TLIF procedure.

METHODS:

In the study, 24 patients with the painful, lumbar spondylolisthesis (Grade I) were treated with the PLIF procedure and 16 patients with less invasive TLIF procedure. Clinical outcomes were assessed before, one year and two years after the procedure using neurological examination, the Oswestry Disability Index (ODI) and Visual analogue score (VAS) for back and leg pain, with 15 % improvement in ODI and 20 % in VAS defined as a clinically significant. The X-ray and CT scans of the patients were taken accordingly.

RESULTS:

Forty patients with the stable lumbar spondylolisthesis, treated with either procedure were included in the study with a minimum follow-up of two years. There was a significant improvement for back and leg pain according to ODI and VAS score in both groups with no statistically important difference between the two groups. There was a slightly faster recovery time of the TLIF patients but did not affect the outcome after two years. The fusion rate was much better with the PLIF group.

CONCLUSIONS

Both procedures (PLIF and minimally invasive TLIF) resulted in significant pain reduction and good functional outcome for the patients with better results in the PLIF group regarding the fusion rate.



Comparison between the surgical outcomes of the lumbar microdiscectomy with patients in prone and lateral positions

Yavor Enchev, FRCS(Eng), B. Iliev, T. Kondev, Pl. Trendafilov, Stephanie Todorova

Department of Neurosurgery, University Hospital "St. Marina", Medical University of Varna, Varna, Bulgaria

BACKGROUND

The patient positioning represents important part of every neurosurgical procedure. The two most frequently used positions in lumbar microdiscectomy are lateral and prone. The purpose of this study was to compare the clinical outcomes of patients operated on in lateral and prone positions and the associated advantages and drawbacks.

MATERIAL AND METHODS

During the period of 3 years (2012-2014) in the Department of Neurosurgery at University Hospital "St. Marina"- Varna were performed 169 lumbar microdiscectomies. In 113 cases the patients were treated in lateral position and in the rest 56 cases in prone position. Universal neurosurgical checklist examiner was applied routinely for prevention of wrong site and wrong level surgery and complications due to incorrect positioning of the patients.

RESULTS

In their series of 169 microdiscectomies, the authors have produced good-to-excellent clinical results in nearly 96% of patients, with the majority returning to work within 1 month. The complication rate of dural tears, discitis has been about 1%, with a reoperation rate of less than 4% equally distributed between both positions. No events of wrong site and wrong level surgery and complications due to incorrect positioning of the patients were found out.

CONCLUSION

The different positioning of the patients for lumbar microdiscectomy does not influence significantly the surgical outcomes. However, it is associated with different potential complications due to eventual incorrect positioning of the patient. Both positions have their advantages and shortcomings and the neurosurgeon must judge which the best option for every individual case is.

Anterior cervical discectomy

Vatroslav Čerina, Krešimir Rotim, Darko Stipić

University Hospital Centre Sestre milosrdnice, Zagreb, Croatia

Introduction. Anterior cervical discectomy (ACD) for spinal cord or nerve root compression was first described by Cloward, and by Smith and Robinson more than 50 years ago. With time, ACD became the gold standard for treating compressive radiculopathy and myelopathy caused by cervical disc herniations. We present our experience in treating these conditions with ACD.

Patients and methods: From January 2008 to June 2014, in a seven-year period, we operated 231 patient. There were 201 single-level operations, 27 two-level and 3 three-level operations. We used carbon fiber intervertebral cage in 191 patients. Anterior cervical plate was used in 78 operations, 153 operations were performed without plating. Patients were evaluated using Neck Disability Index, and VAS one year after operation. Only patients with carbon fiber implant were included.

Results: Good or very good results were achieved in 89% of the patients while unsatisfactory results were present in 11% of the patients. Our complications included 1 surgical site haematoma that developed few hours postoperatively, 2 cases of worsening of motor deficit in patients with myelopathy, 7 cases of transitory hoarseness, 1 implant extrusion and 4 durotomies. We did not have any infections.

Conclusion: Our results and complications match those described in the literature.

Spinal cord stimulation in treatment of failed back surgery syndrome

Feridun Acar

Pamukkale University, Turkey

Intractable axial and extremity pain is a serious problem in failed back surgery syndrome. In algorithm of its treatment, spinal cord stimulation (scs) has Class 1 evidence in pain control. In this lecture, mechanisms and indications of scs will be discussed. The new techniques and its outcomes will be presented. After this lecture, the audience will have a clear idea of the updated applications of scs.



Complications of minimally invasive spine surgery

Zlatko Kolic , Vukas D

Department of neurosurgery, University Hospital Rijeka

The goal of minimally invasive spine surgery (MISS) is to stabilize the vertebral bones and spinal joints and relieve the spinal roots compression, faster and safer with less recovery time, then open procedures. MISS reduced trauma to the muscles and soft tissues with better cosmetic results, reduced risk of infection, and blood loss with less pain medications after surgery and rehabilitation required.

MISS techniques include: radiofrequency neuroablation, radiofrequency disc biacuplasty, percutaneous disc decompression (PLDD, coblation, discogel), spine surgery with tubular retractor (METRx), percutaneous spinal decompression, percutaneous placement of screws and rods, PLIF, TLIF and AxialIF, and spinal endoscopy. As with any surgical procedure, there are certain risks in MISS procedure that include possible adverse reaction to the anesthetic, unexpected blood loss during the procedure, and infections.

The rare common complications of MISS are infections, with hidden cause. Incidence of postprocedural infections are 5,5/1000, with mortality of 11,7%. In less then 50% Staphilococcus aureus was revealed as cause. Some of infections as spinal arachnoiditis, epidural and paravertebral abscess, and vertebral osteomyelitis are rare. The treatment depends on stage and cause of infections, with long term antimicrobial admittance an average of three months. After completion antimicrobial therapy, each case was reevaluated and reoperated.



Surgical treatment of chronic pain

Lukas Rasulić

School of Medicine University of
Belgrade

Clinic for Neurosurgery, Clinical Center
of Serbia

INTRODUCTION: One of definitions of pain is unpleasant sensory and emotional experience associated with actual or potential tissue damage. There are several classifications of pain. Pain can be classified as nociceptive, visceral, deafferentation, sympathetically maintained pain (causalgia). Generally, pain can be considered as acute pain, which is generated by activation of nociceptors in tissue that has sustained an injury (it resolves as the injured tissue heal) and chronic pain, which outlasts the typical period required for healing of an acute injury (lasts longer than 3 or 6 months).

METHODS: Basic consideration.

ASSESSMENT OF PAIN: The peripheral nerve injury scale classifies neuropathic pain based upon the effect on the activities of daily living: SEVERE - constant disturbance of daily life, work, study and sleep (4 points), SIGNIFICANT - able to sleep but not to work, study or enjoy hobbies (3 points), MODERATE - able to work, but the pain sometimes so severe as to require time off (2 points), MILD - aware of pain but able to lead a normal life (1 point)

TREATMENT OF PAIN: Medical therapy and/or surgical treatment

SURGICAL TREATMENT: Reserved for cases refractory to medical management or when side effects of medications exceed risks and drawbacks of surgery. Most frequent surgical procedures in neurosurgery which can be considered in surgical treatment of medicamentous intractable pain due to the trigeminal neuralgia are: (1) peripheral nerve ablation or neurectomy (radiofrequency, balloon compression, glycerol injections), (2) Percutaneous trigeminal rhizotomy (PTR), (3) Microvascular decompression (MVD), (4) Stereotactic radiosurgery (SRS).

SURGICAL PROCEDURES IN PAIN TREATMENT:

All surgical procedures in surgical management of pain in neurosurgery can be focused in two major groups, central (cranial) and peripheral nerve procedures as follows: (1) Electrical stimulation (deep brain stimulation in periaqueductal or periventricular gray matter, spinal cord stimulation), (2) Direct drug administration into the CNS (spinal - epidural or intrathecal, intraventricular, different agents: local anesthetics, narcotics), (3) Intracranial ablative procedures (cingulotomy, medial thalamotomy, stereotactic mesencephalotomy), (4) Spinal ablative surgical procedures (cordotomy, cordectomy, commissural myelotomy: for bilateral pain, punctate midline myelotomy: for relief of visceral cancer pain, dorsal root entry zone lesion, dorsal rhizotomy, dorsal root ganglionectomy, sacral cordotomy), (5) Peripheral nerve procedures (nerve block, neurolytic: injection neurodestructive agents e.g. phenol or absolute alcohol) on or near the target nerve using local anesthetics, sometimes in combination with corticosteroids, neurectomy, peripheral nerve stimulators).

CONCLUSION: The first line of treatment of pain are medications. In the cases of chronic pain, where medications do not achieve good pain management and pain decreases quality of life of the patient, one should consider surgical options. Variety of surgical options are available in treatment of chronic pain, and no one is ideal. The best solution are the cases where the very cause of pain can be removed, and in these cases the rate of pain free patient after surgery is high (trigeminal neuralgia, compression, scarring, etc.). Detailed pre-surgical evaluation is paramount for successful treatment. Individual approach to every patient is essential in choosing optimal treatment.



Dynamic Neuromuscular Stabilization approach for low back pain, dysfunction and optimal performance

Alena Kobesova, Pavel Kolar

Rehabilitation Prague School, Czech Republic

Department of Rehabilitation and Sports Medicine, University Hospital Motol, Prague, Czech Republic

Dynamic Neuromuscular Stabilization (DNS) is a new rehabilitation strategy based on the principles of developmental kinesiology and the neurophysiological aspects of a maturing postural-locomotor system. The maturation of the postnatal central nervous system (CNS) and muscle function are related to anatomical maturation (morphological development). Postural activity occurs automatically in the course of maturation of the CNS via coordinated activity of muscles. Postural ontogenesis defines ideal posture from a developmental perspective. Optimal muscle coordination is ideal for joint loading and defines ideal motor stereotypes. The process is genetically determined and begins automatically during CNS maturation. At the age of 4.5 months, stabilization of the spine, pelvis and the chest in the sagittal plane is completed. Completion of basic sagittal stabilization is followed by the development of extremity movement patterns (i.e., supporting and stepping forward/grasping functions) coupled with trunk rotation. As such, the quality of trunk stabilization is essential for any phasic (dynamic) movement since each movement is preceded by stabilization of body segments to provide balance, efficient coordination and stability for its participating elements. DNS diagnosis is based on comparing the patient's stabilizing pattern to the developmental stabilization pattern of a healthy infant. The treatment approach emphasizes training of these ideal patterns as defined by developmental kinesiology. The brain must be properly stimulated and trained to automatically activate optimal movement patterns that are necessary for co-activation of the stabilizers. The ultimate strategy is to teach the brain to maintain central control and stability of the movement restored during therapy. This can be achieved by activation of the stabilizers when placing the patient in the developmental positions. DNS approach requires patient's participation

and compliance. Perception, i.e., the conscious feeling of the movement, is critical. The patient must differentiate between the correct "centrated movement" and the incorrect "decentrated movement" and be able to correct any "decentrated" segments. This ability depends on adequate body awareness. Daily exercise practice is a prerequisite for long lasting effects of the DNS approach to treat pain, prevent repetitive strain injury and enhance sports performance.

Lecture 2: Diaphragm role in stabilization & definition of ideal postural-locomotion function from developmental perspective

Kobesova A, Kolar P.

Dynamic neuromuscular (core) stability is necessary for optimal motor stereotypes and is not achieved purely by adequate strength of abdominals, spinal extensors, gluteals or any other musculature but is accomplished through precise coordination of these muscles and intra-abdominal pressure regulation by the central nervous system. Understanding developmental kinesiology provides a framework to appreciate the regional interdependence and the inter-linking of the skeleton, joints, muscles during movement.

One cannot move without first stabilizing. To maximize our ability to treat our clients with pain in the locomotor system or to train athletes, we must take a global approach, understanding that stabilization for movement & sport involves the entire body, not just the "core". The "core" is involved in the process of stabilization, but only as one piece in a massive neuro-mechanical chain of events. Stabilization does not represent a static position but dynamic neuromuscular strategy along kinematic chain throughout the whole range of movement. At any phase of movement, under optimal condition, the brain coordinates our muscles in a way that minimizes and balances the load applied on joint surfaces or discs. Via central nervous control joints are functionally centred, during any phase of movement. Functional joint centration comprises the maximum available intra-osseous contact at any phase of movement. If one cannot stabilize with proper patterns, compensatory movement stereotypes dominate leading to hyperactivity of certain (usually larger, superficial) muscles groups, resulting in significant increase in joint forces, increasing the risk of injury and decreasing quality of movement performance.



The principles and clinical applications of isokinetic strength testing

Vedran Hadžić

University in Ljubljana, Faculty of Sport,
Dept. of Sports Medicine

Another aspect to consider when training optimal movement (sport) performance is inseparability of respiration and stabilization. One cannot stabilize correctly without proper breathing mechanics. It is through respiration that continuous activation of the diaphragm, abdominal wall, and pelvic floor are maintained. Research has shown that the diaphragm is not just respiratory muscle but it is also key stabilizer of the pelvis, ribcage and spine ("core"). Thus respiration keeps the postural stabilizing system activated for each and every movement we make. As the diaphragm contracts and the central tendon descends during inhalation and postural tasks, the pelvic floor and the abdominal muscles eccentrically contract to regulate the volume within the abdominal cavity, which, in turn, controls the intra-abdominal pressure. As the intra-abdominal pressure rises, automatic stabilization of the spine occurs. This stability is paramount for the efficiency and stability of all motions. In a physiological situation, during postural activity related to breathing, diaphragm excursion and its flattening are more accentuated when compared to breathing at rest. During non-respiratory or strictly postural activity, the diaphragm does not change its shape in a typical fashion. It does contract and flatten, but non-homogenously (the diaphragm does not activate as one muscle but rather its individual parts can be active at different times). This pattern also differs in healthy individuals and in patients with chronic low back pain. Dynamic MRI demonstrated that patients with chronic low back pain and abnormal morphological findings in the lumbar spine, show greater flattening of the lumbar portion of the diaphragm when compared to a healthy population.

The diaphragm is also considered to be an external esophageal sphincter and during the respiratory cycle will demonstrate regular pressure fluctuations (pressure increase during an inspiratory phase) in the lower esophageal sphincter region, which can be verified by manometric observation. Since the diaphragm is simultaneously a respiratory and postural muscle, a dysfunction in these areas reflects also in sphincter dysfunction, which is an important component in the diagnosis and treatment of gastroesophageal reflux disease. Many patients with GERD, therefore, demonstrate not only sphincter dysfunction, but also a combined respiratory-postural dysfunction,

Isokinetic strength evaluation is an important part of the comprehensive evaluation and rehabilitation of the musculoskeletal system. Isokinetic testing provides us with essential information regarding (1) the absolute and/or relative strength of the muscle groups of interest, (2) the existence of strength deficits and (3) the existence of strength imbalances using either the conventional strength ratio: $\text{Antagonistconc}/\text{Agonistconc}$ or the dynamic control (also functional) ratio: $\text{Antagonistecc}/\text{Agonistconc}$. These parameters have an important predictive value for lower or upper extremity injuries in the terms of injury prevention and as a common objective clinical outcome measure to be used in evidence based rehabilitation guidelines. This is best seen in ACL injuries where all major clinical guidelines [1, 2] suggest isokinetic knee testing when making a clinical decision in regard to progression to the next phase of rehabilitation or return to sport and/or ADL activities [3]. While isokinetic testing of the knee dynamic stabilizers is well known, it is very important to highlight that isokinetic strength testing of the shoulder is as equally informative and important as it enables us to evaluate both rotator cuff [4] and scapular stabilizers [5]. Isokinetic testing has a special place in the area of sports medicine where isokinetic strength parameters are used to predict the players at risk [6] for some important and frequent injuries but also sports performance of healthy players (e.g. sprinting [7], vertical jumping [8, 9], overhead spiking [10]). The open kinetic chain conditions provide excellent isolation of certain muscle groups and ability of modern dynamometers to tightly control training loads and velocities makes them an important strength-training tool in the treatment of tendinopathies and muscle strains (e.g. hamstring strains) [11]. Isokinetic dynamometry has evolved into important, objective, safe and reproducible diagnostic tool in rehabilitation and sports medicine and it is becoming increasingly popular and important in training as well. To utilize the most from such advanced diagnostic tool it is important to choose adequate testing protocol that has a good sensitivity and specificity, and one must



be aware that the protocol may differ based on the clinical endpoint.

References

1. Wilk KE, Macrina LC, Cain EL, Dugas JR, Andrews JR: Recent advances in the rehabilitation of anterior cruciate ligament injuries. *The Journal of orthopaedic and sports physical therapy* 2012, 42(3):153-171.
2. Manske RC, Prohaska D, Lucas B: Recent advances following anterior cruciate ligament reconstruction: rehabilitation perspectives : Critical reviews in rehabilitation medicine. *Current reviews in musculoskeletal medicine* 2012, 5(1):59-71.
3. Myer GD, Paterno MV, Ford KR, Hewett TE: Neuromuscular training techniques to target deficits before return to sport after anterior cruciate ligament reconstruction. *Journal of strength and conditioning research / National Strength & Conditioning Association* 2008, 22(3):987-1014.
4. Hadzic V, Sattler T, Veselko M, Markovic G, Dervisevic E: Strength Asymmetry of the Shoulders in Elite Volleyball Players. *Journal of Athletic Training* 2014, 49(3):338-344.
5. Cools AM, Geerrooms E, Van den Berghe DF, Cambier DC, Witvrouw EE: Isokinetic scapular muscle performance in young elite gymnasts. *J Athl Train* 2007, 42(4):458-463.
6. Myer GD, Ford KR, Khoury J, Succop P, Hewett TE: Development and validation of a clinic-based prediction tool to identify female athletes at high risk for anterior cruciate ligament injury. *The American journal of sports medicine* 2010, 38(10):2025-2033.
7. Bracic M, Hadzic V, Coh M, Dervisevic E: Relationship between time to peak torque of hamstrings and sprint running performance. *Isokinetics and Exercise Science* 2011, 19(4):281-286.
8. Sattler T, Sekulic D, Spasic M, Osmankac N, Joao PV, Dervisevic E, Hadzic V: Isokinetic knee strength qualities as predictors of jumping performance in high-level volleyball athletes; multiple regression approach. *The Journal of sports medicine and physical fitness* 2014.
9. Sattler T, Sekulic D, Esco MR, Mahmutovic I, Hadzic V: Analysis of the association between isokinetic knee strength with offensive and defensive jumping capacity in high-level female volleyball athletes. *Journal of science and medicine in sport / Sports Medicine Australia* 2014.
10. Forthomme B, Croisier JL, Ciccarone G, Crielaard JM, Cloes M: Factors correlated with volleyball spike velocity. *The American journal of sports medicine* 2005, 33(10):1513-1519.
11. Opar DA, Williams MD, Shield AJ: Hamstring strain injuries: factors that lead to injury and re-injury. *Sports medicine* 2012, 42(3):209-226.

Isokinetic rehabilitation

Nataša Desnica

Kaliper centar, Croatia

Isokinetic rehabilitation has shown to be a very effective method in treating different acute and chronic injuries of the musculo-skeletal system. It is fast and pain-free and can be used in acute and chronic injuries, as well as preoperatively and postoperatively.

It is also successfully used in prevention of injuries by solving imbalances of the antagonistic muscle groups, which are especially common in athletes.

During the rehabilitation, it is very important to use isokinetics at the right time, and in synergy with other physical treatments

In this talk different examples of using isokinetic rehabilitation will be shown.

Key words: isokinetic, muscle imbalance, rehabilitation

Isokinetic treatment of muscle dysfunction

Egić Božidar, Veber Dalibor

Ordinacija Dr Egić, Croatia

Community Health Centre Vukovar, Croatia

The complexity of a locomotor system and the power of adaptation it, in fact the nervous system, can exert is best demonstrated through variety of sports, dances and rituals humans engage to. Physiological adaptation is sometimes so large that it is hard to discern when or where begins the pathology. The theory of developmental kinesiology provides us with great help by defining the ideal physiological motor patterns like role models we should strive for. With the physiological development of a child in utero and during the first few years of life, there is a gradual development of posture as a result of central nervous system maturation and release of the genetically encoded motor programs. This is a spontaneous process, taking place under the influence of gravity and proper environmental stimuli. Muscle synergies are formed, while contractions of the antagonists become balanced, resulting in equilibrium between the function of the phylogenetically older, tonic, and phylogenetically younger, phasic, part of the musculoskeletal system. The influence of this balance irradiates to the joints and enables the movement in the neutral zone (Panjabi) or, put in another words, enables the joint centration during the movement (Kolář). Moreover, there is minimal energy expenditure and articular surfaces are in maximal contact, thereby protected from overloading. Simply put, movements have reached biomechanical perfection.

If this harmony becomes impaired, usually in the sense of facilitation of the tonic or inhibition of the phasic system, a pattern of imbalance develops that spreads throughout the system like a reflex, shedding some light on the mutual connection of distant muscles along the way. Given that motor patterns are genetically defined and hence predictable, as taught by developmental kinesiology, the same predictability can be applied to impaired muscle reactions. By virtue of this observation, Janda has categorized dysfunctions of the muscular system in three major syndromes: upper crossed syndrome, lower crossed syndrome,

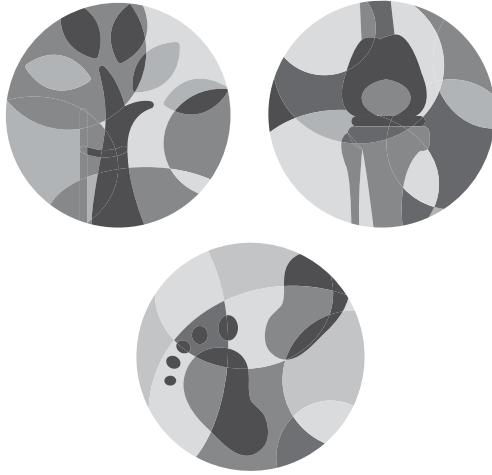


stratification syndrome. Functional pathology or dysfunction of the locomotor system is the most frequent cause of pain. It often affects all parts of the locomotor system simultaneously, from passive (bones, joints, ligaments), active (muscles, fascia) to control part (peripheral and central nervous system, motor patterns), creating chain reactions and complex clinical syndromes hardly explainable in terms of cause and effect. There are multiple causes of dysfunction, but the end result is always the same, pain as a first warning sign and impairment of static and/or dynamic function of the locomotor system. Structural changes are mostly absent or of marginal significance. Spine is probably the best example of presented pathophysiological process, because the pain of spinal origin is mostly analyzed only locally, where we seek for responsible structural pathology. However, if we confuse the source of pain for the cause of pain, we are more than often destined to failure. Moreover, the causative factor affects only the local level in the beginning, leading to reflex changes and adaptation. If this is insufficient, its influence gradually radiates to the higher levels of the central nervous system and impairs the central motor patterns, leading to global pathology. In this way, local dysfunction becomes global and spine can be the cause of the problem, but also just one link in a chain of global dysfunction of the locomotor system.

Dysfunction of the locomotor system is a complex term. It is defined as imbalance (facilitation or inhibition) between motor units of single or group of muscles and becomes visible through inadequate motor stereotypes that lead to inadequate positioning of articular surfaces during the movement. Described pathological adaptation is associated with reflex changes which can lead to many symptoms, from pain to visceral problems. In treatment it is important to find the root of the problem that usually hides far away from the source of pain. Along numerous diagnostic and kinesietherapeutic procedures, isokinetic diagnosis and training can be very helpful as the root of the problem frequently lays in the muscle imbalance. By measuring the parameters of isokinetic muscle contraction, using the isokinetic dynamometer, one can determine the muscle strength, work and endurance. These results are later analyzed and used for planning and performing isokinetic training. The advantages of isokinetic training are efficiency, safety, reproducibility and comparability.

The drawbacks are nonphysiological contraction (constant angular speed), impossibility to achieve neural reactions, motor learning and complexity of the movement (3D). The scope of the use of isokinetics is wide, from prevention, rehabilitation after trauma or surgery, various pain syndromes of muscular origin, to sports training. Contraindications are few, the use is simple as is the storing of data, an important consideration regarding the limited amount of time available for a patient. In spite of all the benefits of isokinetics, it has to be viewed as just one part of the rehabilitation process. The complexity of the locomotor system and the chain reactions which result from its dysfunction require multidisciplinary approach in the treatment.

KEYWORDS: isokinetics, dysfunction, locomotor system, chain reaction, pain syndrome, rehabilitation, developmental kinesiology



Friday



Advantages and disadvantages of different bearing couples in Total Hip Arthroplasty

Karl Knahr, Leder S.

Orthopaedic Hospital Vienna-Speising,
Vienna, Austria

During the last decades polyethylene, ceramic and metal have been the most effective materials for articulations in total hip arthroplasty. Nevertheless, over the years all of them have shown disadvantages and therefore modifications of the materials took place.

Polyethylene has been improved by cross-linking and recently addition of vitamin E should further improve the long-term results. The most concerns of ceramic articulations were fracture and squeaking, which mainly took place in the first generations of this material. During the last years introduction of combinations of aluminiumoxid and zirconiumoxid have improved these shortcomings.

Most concern we have to face with metal articulations, especially those with large diameter heads and surface replacement. Severe metallosis and allergic reactions against wear debris of metal led to a series of failures during the last years. Therefore guidelines have been introduced for further use of metal-on-metal pairings.

This paper will give a summary of all the advantages and disadvantages of the above mentioned articulation materials. Recent data of clinical results will hopefully give better information about the success rate of these materials to allow a sufficient recommendation for clinical use.



Hip aspiration – The ultimate diagnostic procedure

Bernd Preininger, Viktor Janz, Philipp von Roth, Tobias Winkler, Andrej Trampuz, Carsten Perka, Tilman Pfitzner

Department of Orthopaedics, Center for Musculoskeletal Surgery and Berlin-Brandenburg Center for Regenerative Therapies, Charité - University Medicine Berlin, Charitéplatz 1, D-10117 Berlin, Germany

Introduction: A reliable detection of persistence of periprosthetic joint infection (PJI) is essential for successful two stage septic total knee arthroplasty (TKA) revision surgery. Despite the questionable reliability and lack of validation, synovial aspiration of the in vivo PMMA-spacer is a common practice. Aim of the current study was to investigate the diagnostic validity of synovial aspiration in comparison to CRP-values for the detection of PJI persistence during two staged septic TKA revision surgery.

Methods: 62 patients, undergoing a two staged septic TKA revision surgery, were analyzed during the course of this retrospective cohort study. After the initial explantation and septic debridement a temporary knee arthrodesis was performed through internal fixation in combination with a PMMA-Spacer. Six weeks after spacer implantation, followed by a two week antibiotic-free interval, a synovial aspiration was performed. CRP-values (cut off <5mg/l) were acquired at the time of explantation of the prosthesis, at the time of synovial aspiration and at the time of TKA reimplantation. The definite diagnosis of PJI persistence was made according to the results of the histological analysis, microbiological culture of tissue samples and presence of pus or a sinus tract at the time of reimplantation and according to the MSIS criteria for diagnosis of periprosthetic infection, respectively. The sensitivity and specificity of synovial aspiration of the PMMA-Spacer and CRP-values for determination of PJI persistence were evaluated.

Results: 27 males and 35 females with an average age of 68 (+/- 11) years were included in this study. The sensitivity of synovial aspiration of the PMMA-

Spacer according to the PJI criteria were quite low (21% and 28%, respectively), with a specificity of 100%. The sensitivity of the CRP-values at the time of spacer aspiration were moderate (66% and 67%, respectively) while being quite unspecific (35% and 67%, respectively). At the time of reimplantation the CRP-values achieved a sensitivity of 61% and 84%, respectively as well as a specificity of 48% and 65%, respectively.

Conclusion: The synovial aspiration of a PMMA-Spacer for detection of a persistence of PJI achieves a very low sensitivity. However, a positive bacterial culture for the spacer aspiration was always predictive of a PJI persistence in our patient collective.

The evaluation of CRP-values achieved a superior sensitivity over the spacer aspiration, however, a normal CRP-value could not reliably exclude a persistence of PJI. Our results suggest that spacer aspiration and CRP-values are not reliable to determine the correct timing for TKA reimplantation.



Surgical mistakes in infected THA treatment

Drago Dolinar

**Department of Orthopaedic Surgery,
University Clinical Centre Ljubljana,
Slovenia**

The treatment of orthopedic implant infections is often difficult and complex, although the chances of successful treatment with a properly selected diagnostic, surgical and antibiotic treatment protocol have recently increased significantly. Surgical treatment is a key factor in the treatment of infections of orthopedic implants, and any errors in this respect often lead to worse clinical outcomes. The most important and frequent surgical errors include: conservative treatment of periprosthetic infections with antibiotics alone, delayed surgical revision, insufficient debridement during surgical revision, inadequate intraoperative sampling for bacteriological and histological analysis. It is important to have and to follow proper treatment algorithm for periprosthetic joint infection. In this work we present the listed surgical errors and some illustrative clinical cases.



Two-stage revision with an early reimplantation for PJI

Tobias Winkler, B. Preininger, P. von Roth, T. Pfizner, H. Baecker, A. Trampuz, C. F. Perka

CMSC, Charité Berlin

INTRODUCTION

Two-stage exchange is the current clinical standard for infected total knee (TKA) and hip (THA) arthroplasty. Due to a lack of evidence the optimal time of the interval between explantation and reimplantation remains undetermined although there are considerable limitations and care need during this interval for the patients. The aim of the current study was to investigate the clinical outcome between short (SI) and long (LI) intervals for two-stage exchange.

METHODS

38 consecutive patients undergoing two-stage exchange were enrolled retrospectively. (18 hips, 20 knees). All patients underwent explantation of the prosthesis and debridement followed by an either calculated or resistogram-adapted antibiotic therapy up until 12 weeks after the first debridement. No holiday period with joint aspiration was performed before reimplantation. Patients with an early infection or difficult to treat microorganisms were excluded. For THA a Girdlestone-resection and for TKA a temporary arthrodesis was performed. Prostheses were reimplanted after < 4 weeks (SI) or > 4 weeks (LI). Patients were followed up for delayed prosthesis failure (reinfection or septic loosening within 2 years), need for care in the interval and function after reimplantation.

RESULTS

The LI was 66.7 days in average, the SI 17.9 days. 35/38 patients could be followed (92 % FU) for an average time of 25 months. 1 patient in the LI group suffered from a reinfection, the SI group was without reinfection at the latest FU. The need for care was significantly lower in the SI than the LI group both for THA and TKA (days of care 0 and 20.4 days, respectively). The range of motion and the leg length was equal in both groups.

CONCLUSION

Our results show that in two-stage septic revision arthroplasty sufficient debridement combined with standardized antibiotic therapy without antibiotic holiday allows to shorten the interval between explantation of the prosthesis and reimplantation not yielding inferior results compared to the long interval. Care cost and patient inconvenience due to immobilization could be reduced dramatically while the outcome did not show any inferiority in terms of clinical outcome.

Our results suggest that patients with periprosthetic joint infection can be treated with a shorter interval between stages without medical compromises but much higher economical efficacy.

Summary: Patients with periprosthetic joint infection can be treated with a shorter interval between stages without medical compromises but much higher economical efficacy.



Wear and corrosion of metal and ceramic bearings

Robert M. Streicher

Dr. Streicher GmbH, Switzerland

INTRODUCTION

Aseptic and septic loosening, dislocation, wear induced osteolysis and adverse reaction to metals are major factors leading to revision in THA. The choice of the bearing couple materials may exert a significant influence on the incidence of revision surgery.

EXPERIMENTS / RESULTS

Wear rates were evaluated both in vitro and in vivo for ceramic-on-ceramic (CoC) articulations (retrievals) and ceramic and metal bearings vs. highly cross-linked polyethylene XP (radiographs). CoC wear was negligible and independent on the bearing diameter. An 8-fold decrease for bearings using CoC with composite ceramic and a significant 54% wear rate reduction of highly cross-linked polyethylene with ceramic compared to metal heads were found.

Friction measurements were conducted in vitro with CoC and CoP, MoP, CoXP and MoXP bearings with diameters from 28 to 40 mm in serum. CoC demonstrated the lowest friction moment of all combinations; 40% less. CoC bearings with 40 mm had almost the same friction moment compared to bearings with PE/XP with 28 mm. Highly cross-linked PE exhibited a higher friction moment than standard PE, while using ceramic heads reduced the friction marginally.

Fretting corrosion estimation was carried out by qualitative surface analysis on retrievals on i) a matched cohort (time in situ, stiffness,) of 50 different stems made from three different alloys, each with either metal or ceramic head; and ii) 54 retrievals with various bearings using the same prosthesis. Both investigations revealed a significant reduction of corrosion damage, and subsequently particle and metal ion release, of the stem tapers when coupled with a ceramic bearing component with obviously no damage on the ceramic heads.

Additionally material loss for i) was evaluated quantitatively using sophisticated metrology. The results confirmed that of the qualitative study. Stem metal loss was less for modular components with ceramic heads. On the head inner taper ceramic bald heads showed some metal transfer and no material loss, while of the taper of metal head metal loss was evident; being about 10 times higher than on the stem taper. As metal heads are made from CoCr alloy this raises concerns about local and systemic adverse reactions, especially to Co.

To answer the question if taper morphology has an influence on material loss from the interface 347 stems and ball heads from metal-on polyethylene retrievals was estimated qualitatively using a modified Goldberg score. No statistical difference in metal loss was detected between smooth and micro-grooved/grooved stem tapers.

CONCLUSION

Reducing the dislocation risk by using larger components for enhanced stability of THA can be achieved using CoC bearings which do not increase wear and friction of the bearing. In

general ceramic components reduce the issue of wear and friction and also diminish corrosion/fretting effects for modular implants, addressing therefore several potential risks for THA failure.

Anterior approach with a traction table

Manfred Kuschnig, M. Leitner,

Orthopaedic Department EKH,
Klagenfurt, Austria

For a long time the standard way to implant a hip prosthesis in Austria, and also in our hospital, was a „lateral“ or „anterolateral“ approach. The results were good and the patients were satisfied. A lot of them had no problems to return to the daily routine. But demands are changing. Patients get younger and their level of activity is increasing. Many patients are not retired; they have to return to their job after the operation. These patients like to carry on with their preferred sports. Lots of people believe that everything can be completely repaired, with a simple mouse click. Minimally invasive surgical (MIS) techniques have motivated surgeons to change their implants to more MIS friendly designs. Both, new implant designs and MIS might reduce longevity of total hip replacements (THR). The anterior approach using an extension table was introduced by Robert Judet (1) in 1947. This so-called „AMIS“ approach is an anatomical approach. Due to the protection of the gluteal muscles it is, according to William J. Hozack, the best way for a minimal invasive surgery - „MIS should lessen the impact of the operation on the quality of life and disruption of daily routine. In 2007 we started anterior minimally invasive hip surgery as described F. Laude and J.M. Matta. We started using special instruments and the AMIS mobile leg positioner a so to speak "light extension table". Until today we have performed more than 2.000 interventions this way. After three years, we did a retrospective review of the first 100 consecutive patients undergoing THR with the AMIS technique. In 2014 we had an investigation of patients operated in the period of Mai 2010 to October 2011 with a special stem, the „AMISTEM“. Points of interest were the age, tribological pairing, radiolucent lines due to "green zones", blood loss and number and reason of revisions. Our conclusion is that most of our patients experience a clear benefit from the AMIS procedure. Still, there should be several further.

Anterior approach supine position

Gregor Kavčič

General hospital Novo mesto, Slovenia

Different approaches to the hip joint are possible and every approach is a good approach, if the surgeon performs it routinely. In our opinion direct anterior approach is the best approach, because it is the only true minimally invasive approach, done in intermuscular and internervous plane. It is muscle preserved procedure and no muscle desinsertion or denervation is done, which causes less dislocations, less postoperative pain and enables fast rehabilitation without strict limitations. Disadvantages of this approach are longer learning curve and possible damage to lateral femoral cutaneous nerve. Direct anterior approach in supine position has advantages of easy leg-length and stability check and forces needed for femoral preparation are under assistant surgeon control. Preparation of the acetabulum and implantation of the acetabular component is an easy task with standard instruments, preparation of the femoral canal involves careful preparation of the dorsal capsule, positioning of the operated leg in figure 4 position and leverage of the femur. A broach handle with lateral offset is needed. After completion of the learning curve it can be applied for all different patients (old, young, thin, obese, muscular, osteoporotic...). In our hospital we use this approach since 2010 for total hip arthroplasty in cases of osteoarthritis, avascular necrosis, rheumatoid arthritis, subcapital femoral fractures and revision surgeries for cup loosening.



Short stems – the evidence from the registries

Kovač Simon

Valdoltra orthopaedic hospital, Ankaran

The concept of short stem replacement is not new. The interest in short stems is increasing in last years. Short stems became an accepted treatment option for total hip arthroplasty. New designs have been introduced in last years, however many of them have already been withdrawn from the market. Number of published results increased substantially in last two years.

There are several potential advantages of short stems. There is less thigh pain, medullary canal is left intact for future revisions and lower incidence of microembolism. There are several potential disadvantages as well. Surgical technique should be modified; there can be lack of primary stability, malpositioning of the stem can occur. Higher incidence of intraoperative femoral fractures is probable and procedure can be technically difficult – that can lead to patient selection and surgeon dependent results. (1,2,3)

There is limited material for outcome assessment of these implants from clinical sample based studies. Majority of the articles are publishing short to mid-term results. (4,5,6)

This fact leads us to analyze the data from Arthroplasty registers from Lombardy (Italy), Emilia Romagna (Italy), Slovakia, and Valdoltra hospital (Slovenia). The analysis focused on revision of the stem for any reason. Five different stems were identified - CFP Collum femoris preserving®, Mayo®, Metha®, Proxima® and Nanos®. The results of the short stems were analyzed and compared with the data from the published case series. There have been no signs of worse than expected short to mid-term results of short stems. In analyzed Arthroplasty Register datasets all short stems included in this analysis have mid-term revision rates that are similar to conventional total hip arthroplasty.

1. Gilbert GE, Salehi-Bird S, Gallacher PD, Shaylor P. The Mayo conservative hip: experience from a district general hospital *Hip Int* 2009; 19(3): 211-214.
2. Mollí RG, Lombardi AV Jr, Berend KR, Joanne B. Adams JB, Sneller MA. A Short Tapered Stem Reduces Intraoperative Complications in Primary Total Hip Arthroplasty. *Clin Orthop Relat Res* 2012; 470:450–461.
3. Pons M. Learning curve and short-term results with a short-stem CFP system. *Hip Int* 2010; 20 (Suppl 7) (S7): 52-57.
4. Gill IR, Gill K, Jayasekera N, Miller J. Medium term results of the collum femoris preserving hydroxyapatite coated total hip replacement. *Hip Int* 2008; 18(2):75-80
5. Tóth K, Mécs L, Kellermann P. Early experience with the Depuy Proxima short stem in total hip arthroplasty. *Acta Orthop Belg.* 2010 Oct;76(5):513-8.
6. Briem D, Schneider M, Bogner N, Botha N, Gebauer M, Gehrke T, Schwantes B. Mid-term results of 155 patients treated with a collum femoris preserving (CFP) short stem prosthesis. *Int Orthop.* 2011 May;35(5):655-60.



Imageless navigation of the socket in THA

René Mihalič

Orthopaedic Hospital Valdoltra,
Jadranska cesta 31, 6280 Ankaran

Total hip arthroplasty (THA) is one of the most successful surgical procedures ever performed (1). Even though we live in an era of rapid high tech modernisation of products for daily living, the golden standard for THA is still freehand implantation of components. Malposition of the socket is not uncommon during THA, and is the most important risk factor of dislocation or excessive early wear. Optimal socket positioning remains still a challenge (2, 3). Lewinnek et al. defined a "safe zone" for acetabular component positioning between 30° and 50° of inclination and 5° and 25° of anteversion (4). To place the socket in "safe zone" the surgeon must rely on different landmark marks, which could be hard to identify, especially by inexperienced surgeons. To avoid this problems various systems of computer-assisted orthopaedic surgery (CAOS) in THA were implemented in the past. These include computer assisted preoperative planning, robotic devices, navigation and patient specific surgical templates (5). Except of the imageless navigation, all other CAOS systems require preoperative computed tomography (CT) images.

Imageless navigation is a passive system and is just a helpful tool for surgeon to place the socket in the desired position, according to the patient's anatomical conditions. The system consists of optical or magnetic localiser and optical or magnetic trackers. Accuracy of the imageless navigation depends on landmark pointing. This is typically done by registering the anterior superior iliac spines and the pubic tubercle. Those created landmarks define anterior pelvic plane (APP) and computer can determine where the pelvis lies in space. For imageless navigation systems, registration is accomplished with optical trackers or sensor mounted to the pelvis (6). Real and created APP can be different if the surgeon does not take into account soft tissue thickness on the landmark. To perform the surgery surgeon still uses conventional tools equipped with different types of trackers or sensors which guide the placement of the socket, according to the created APP. Several studies demonstrated better socket alignment

with imageless navigation compared to freehand technique (6, 7, 8).

Orthopaedic Hospital Valdoltra in collaboration with software company Ekliptik® Ljubljana created also an effective imageless navigation system. The validation of the system was approved by national ethics committee. We performed 20 THAs by freehand technique. Prior to placement of the socket the APP was defined by special self-developed non-invasive tool and tracking sensor was mounted according to the imageless navigation protocol. After placement of the socket by freehand technique inclination and anteversion angles of the socket were measured with imageless navigation system. After the procedure all 20 patients had postoperative CT of the pelvis and the position of the sockets was also measured by independent person. Then we compared the results and calculated the average deviation between both measurements. The results were excellent. The average deviation for anteversion was -1.9° and for inclination 0.7° respectively. Our results also demonstrate the importance of imageless navigation for the accurate positioning of the socket in THA.

REFERENCES

1. Crawford RW, Murray DW. Total hip replacement: indications for surgery and risk factors for failure. *Ann Rheum Dis* 1997; 56: 455-457.
2. Lee YK, Biau DJ, Yoon BH et al. Learning curve of acetabular cup positioning in total hip arthroplasty using a cumulative summation test for learning curve (LC-CUSUM). *J Arthroplasty* 2014; 29: 586-589.
3. Saxler G, Marx A, Vandeveld D, Langlotz U, et al. The accuracy of free-hand cup positioning - a CT based measurement of cup placement in 105 total hip arthroplasties. *Int Orthop* 2004; 28: 198-201.
4. Lewinnek GE, Lewis JL, Tarr R, Compere CL, Zimmerman JR. Dislocations after total hip replacement arthroplasties. *J Bone Joint Surg Am.* 1978; 60: 217-220.
5. Sugano N. Computer-assisted orthopaedic surgery and robotic surgery in total hip arthroplasty. *Clin Orthop Surg.* 2013; 5: 1-9.



CAD-CAM THA

6. Kelley TC, Swank ML. Role of navigation in total hip arthroplasty. *J Bone Joint Surg Am.* 2009; 91(1): 153-158.
7. Kalteis T, Handel M, Herold T, Perlick L, Baethis H, Grifka J. Greater accuracy in positioning of the acetabular cup by using an image-free navigation system. *Int Orthop* 2005; 29: 272-276.
8. Lass R, Kubista B, Olischar B, Frantal S, Windhager R, Giurea A. Total hip arthroplasty using imageless computer-assisted hip navigation. A prospective randomized study. *J Arthroplasty* 2014; 29: 786-791.

Stephen R Cannon

**Royal National Orthopaedic Hospital,
Stanmore, United Kingdom**

Due to the increasing early failure of uncemented femoral implants in the 1980s the Institute for Bio-Mechanical Engineering, Stanmore developed a hip design work station to model and manufacture CAD CAM hip replacements for the complex primary case and revision hip arthroplasty. The rationale of the design was to provide initial early fixation, prevent distal migration and allow bone on-growth. The design allowed for early loading of the calcar area. The design was based on key anatomical areas recognised by radiography and CT and automatic correction of femoral anteversion could be achieved. The surgery allowed for line to line fit within the femoral cavity, with minimal removal of cancellous bone. The theoretical stresses produced were closer to normality than other stem types.

RESULTS

Over 3,000 stems have been inserted and RSA analysis shows that migration, even in revision cases, is minimal and less than cemented hip replacement. Radiological analysis confirmed 'spot welding' to be present on all cases, with no evidence of bone pedestal formation, and in a study of 112 components in young people with a follow-up of between 10 and 17 years no failures or aseptic loosening has been seen.



Fast track Total Hip Arthroplasty

Ales Berce

Aleris Hospital Sweden

INTRODUCTION:

Total hip Arthroplasty (THA) has gained reputation to be the most successful surgical procedure in the 20th Century, due to its success in restoring patient function, functional longevity of the implants and mainly its low peri- and postoperative complication rate of around 1-2%, of which implant-associated infection, early postoperative dislocations and perioperative fractures (esp.femur) are the most common.

As surgeons are getting more and more experienced in this routine surgical procedure, so do nurses and physiotherapists and other supporting services. A historical trend to shortening of hospital stay is apparent, from weeks in the past century to a trend where it is done as a day-surgery procedure in several hospitals (in the USA) with direct anterior approach gaining in popularity. As THA surgery is spreading in terms of number of procedures annually done on the worldwide scale, so are the patients getting more and more demanding in terms of expectations regarding recovery to work and even omitting standard postoperative restrictions (early crutches, raised seats, most sports activities).

Any surgery with accelerated rehabilitation that leads to early discharge and improves the patient experience is a fast-track surgery. From a critical point of view, however, the biggest concern with fast-track THA is patient safety, which should not be compromised with early discharge from the hospital. Patient education, well defined hospital protocols, trained staff and functioning social home-help services (for elderly, debilitated, home-alone patients) are of paramount importance.

MATERIALS AND METHODS:

The Swedish fast track THA model with a 2 nights hospitalization length is presented. Data from a regional small hospital is shown, covering the past 2 years (2013: 276 procedures, 2,6 days median time; 145 patients 3 days, 1 patient 12 days. 2014: 313 procedures, 2,2 days median time; 50 patients 3 days and 1 patient 16 days).

RESULTS:

Postoperative pain, general bad condition/tiredness and wound discharge were the main factors associated with prolonged in-hospital time.

DISCUSSION: The nationwide spread of the 2-night model, low number of fast-track associated complications (in terms of preventable events) are statistically validated each year with the Swedish Hip Registry doing annual analysis and reporting feedback to hospitals. So far, the model has shown to be safe and is in fact practised also in most hospitals in Denmark, Norway and Finland. The main associated deciding factor to fast-track THA is also healthcare insurance company reimbursement model.



Knee arthroplasty today

Francesco Falez

Ospedale Santo Spirito, Italia

With the change of style of life, increasing of activity level and mean age of population we have assisted in the last decade to an impressive growing of procedures of Total Knee Replacement (TKR) and today this is the most growing arthroplasty procedure, and the procedure itself has gone through dramatic changes both in surgical technique in design and mechanics of the components, but despite its enormous success it remains among the most debated and controversial between dedicated surgeons and there are many issues with pros and cons that are constantly investigated.

The understanding of such issues have permitted greater surgical evolution in various knee condition permitting better outcomes and long term results .

The A presents and debate these various issues discussing on different old problems and new technologies such as prevention of DVT , use of cement, navigation and PSI.

Best options for treatment of infection and possible surgical procedure are discussed in order to give a complete information on the status of the art on TKR.

MANAGEMENT OF BONE LOSS IN REVISION TKR

Revision surgery in TKR remains challenging because of so many possible scenario that can be correctly evaluated only intraoperative ; as a matter of fact imaging may frequently underestimate severity of bone loss for the presence of the implant and because its removal may determine further bony disruption.

The A gives a useful handout of possible surgical option in relation to grade of bone loss classified in accordance to the most updated classification and describe for each degree of the AORI classification possible surgical solution with review of results reported in the literature.

The presentation may be found extremely useful to the participants who can have a complete instructional presentation on how to manage different amount of bone loss in order to obtain a well functioning revision implant.



Cemented or cementless knee arthroplasty

Simon Kovač

Valdoltra orthopaedic hospital, Ankaran

Cementless fixation in hip arthroplasty is well proven to have good long term results with well-designed implants. In many countries cementless hip fixation became the golden standard. On the other hand, cementless fixation of the knee is rarely used and cemented fixation is golden standard. The history of cementless TKA began with poorly designed knees and bad press fit fixation. That resulted in early loosening mainly of the tibial plateau and patellar component. Approximately 10% of surgeons in US dealing with the primary TKA are using cementless knees as a primary option (1). Number of cementless knee in arthroplasty registers is increasing in last years (2).

With the improvements of design, fixation surfaces results of the cementless TKA improved. Migration of a total knee during first two years has shown to be predictive for the probability of later aseptic loosening. The stability of the modern cementless components, as find out with RSA, is excellent. As with cemented designs, the prosthesis migrates in first postoperative year. Afterwards, in some designs, the plateau remains stable between 2nd and 5th postoperative year (3).

The advantages of cementless fixation are reducing the risk of the failure of cement fixation, thermal necrosis and third body wear. Additional advantage is reducing the operative time.

On the other hand, cement can be used to fill the voids between the bone and the prosthesis in imperfect cuts. The risk of the inflammation can be reduced with antibiotic loaded cement. And the costs of the cementless implants are higher.

With newer designs excellent results of 95-99% of survival at 14 to 20 years have been reported (4,5). These results are the same as results of cemented designs. Recently, some articles with comparative survivorship of cemented and cementless prostheses were published (6,7). These results are comparable as well.

In Orthopaedic hospital Valdoltra 598 cementless

knees were implanted with average follow up of 6.1 years. The survival probability with aseptic loosening as the end point was 99.8%. The survival of cemented total knees of the same design in the time period was almost the same and no statistical difference between the groups was found.

Although the newest data regarding cementless total knees are justifying their usage, there is no evidence of the benefit over the cemented components at the moment.

1. Berry DJ, Bozic KJ. Current practice patterns in primary hip and knee arthroplasty among members of the American Association of Hip and Knee Surgeons. *J Arthroplasty* 2010;25(6 Suppl):2.
2. Swedish Knee Arthroplasty Register Annual report 2013. http://myknee.se/pdf/SKAR2013_Eng.pdf.
3. Dunbar MJ, Wilson DAJ, Hennigar AW, Amirault JD, Gross M, Reardon GP. Fixation of a Trabecular Metal Knee Arthroplasty Component. A Prospective Randomized Study. *J Bone Joint Surg Am.* 2009;91: 1578-86.
4. Ritter MA, Meneghini RM. Twenty-year survivorship of cementless anatomic graduated component total knee arthroplasty. *J Arthroplasty* 2010;25: 507.
5. Eriksen J, Christensen J, Solgaard S, et al. The cementless AGC 2000 knee prosthesis: 20-year results in a consecutive series. *Acta Orthop Belg* 2009;75: 225.
6. Choy WS, Yang DS, MD, Lee KW, Lee SK, Kim KJ, Shann-Haw Chang. Cemented Versus Cementless Fixation of a Tibial Component in LCS Mobile-Bearing Total Knee Arthroplasty Performed by a Single Surgeon. *J Arthroplasty* 2014;29: 2397-41.
7. Park JW, Kim YH. Simultaneous cemented and cementless total knee replacement in the same patients. *J Bone Joint Surg* 2011. 93-B: 1479-86.



Total knee arthroplasty – always a slam dunk?

Miroslav Hašpl, Denis Trsek, Tomislav Tabak

AKROMION, Special Hospital for Orthopaedic Surgery, Krapinske Toplice, Croatia

INTRODUCTION:

During primary knee arthroplasty we are faced the cases that are clinically particularly difficult. For arthroplasty in such patients need to be prepared for much difficult further surgical procedures, bone grafting, the use of modular or more constrained endoprosthesis.

AIM:

To determine the number particularly difficult, complex primary total knee arthroplasty, say that the reason so severe cases, analyze possible complications and assess the outcome of treatment compared to standard primary knee arthroplasty.

MATERIAL AND METHODS:

In a time period from 2008 to 2013, we performed 595 primary knee arthroplasties, 84 (14%) was difficult cases, 60 (71%) female and 24 (29%) male, age 15-86 (66). Predominantly it was the complications after intraarticular and extraarticular knee fractures at 23 (27%) cases, severe varus or valgus deformity more than 20 degree at 36 (43%), flexion contraction more than 30 deg. 8 (9,2%), aseptic femoral condyle necrosis 6 (7%), knee dislocation 3 (4%), patellectomy 2, tibial stress fracture 2, bone cysts 2, knee fusion 1. At 22 (26%) knees we used bone grafting, stem augmentation at 15 (17, 9%), mostly CR and CS arthroplasty, in one case hinge prosthesis. For result analysis we used WOMAC score.

RESULTS:

FU was 29, 1 (6-67) months. All knees survived. We haven't noted any septic or aseptic endoprosthesis loosening so far. WOMAC score improved from 40,3 to 85,6.

CONCLUSION:

During primary knee arthroplasty in a relatively small number we can expect increased intraoperative difficulties, particularly after posttraumatic osteoarthritis. It needs to be recognized on time. It is necessary preoperative planning procedures, to have proper surgical instruments, and particularly a wide range of implants, although it is a primary knee arthroplasty



SPECT/CT for the assessment of painful knee prosthesis

Michael Hirschmann

Kantonsspital Baselland (Bruderholz, Liestal, Laufen), Department of Orthopaedic Surgery and Traumatology, Switzerland

Knee arthroplasty is a very successful treatment for osteoarthritis of the knee joint, however, careful scrutiny of the orthopedic and radiological literature reveals that up to 20–40% of patients are not fully satisfied and symptom free following joint replacement, and complain of pain, stiffness, and loss of range of motion. The most common explanations for these are infection, aseptic loosening, instability, malposition of the prosthetic components, arthrofibrosis, and patellofemoral problems. To date, the clinical and radiological diagnostics tools (radiographs, CT, MRI, scintigraphy, SPECT, PET) are limited and do not clearly identify the site and cause of the patient's symptoms.

In patients with unexplained symptoms following arthroplasty, SPECT/CT offers both radiologists and surgeons a rich source of information, combining mechanical, structural, and metabolic data on the patient's knee joint.

The combination of the use of three-dimensional (3D) reconstructed CT-based analysis of component position, orientation, mechanical and anatomical leg axes, as well as both the distribution and intensity of SPECT tracer uptake values has introduced a new dimension on diagnostics. Biomechanics and biology are brought together.

This presentation gives an overview on the clinical value, and current and future applications of SPECT/CT in patients after knee arthroplasty. In addition, clinical cases are shown and the clinical benefit in the treatment of these patients is highlighted.



FORTE - Federation of Orthopaedic Trainees in Europe

Gazi Huri (FORTE President)

Hacettepe University, Turkey,

In this era of continuous change and evolution, orthopaedic training and education gain even more significance. This is where the Federation of Orthopaedic Trainees in Europe (FORTE) plays a major role in the field. FORTE was established in 2005 in Lisbon. It represents all trainees in orthopaedics from day 1 of their residency up to 2 years after they complete it.

Our aims are simple:

- To promote and improve the standards of orthopaedic training in Europe.
- To provide a basis for international links for orthopaedic trainees across Europe.
- To act as a communications center with information about courses and educational opportunities.
- To build a database of educational activities and fellowship opportunities.
- To act as a point of referral and contact for industry, educational bodies and government regarding orthopaedic training in Europe.
- To represent the interests of trainees in orthopaedic surgery in Europe.

FORTE is becoming even stronger and is growing rapidly. It is now possible to accomplish our goal of having a reference for all orthopaedic residents in Europe. Already 19 European countries are actively involved and by the end of 2015 hopefully we will reach 22 countries. It is estimated there are 3,000 active members in FORTE's activities. Please visit our website or join us on Facebook and Twitter.

In addition, FORTE is working on producing educational material that will complement training and the preparation for the EBOT exam. Currently, we are preparing a Study Guide Book Series in collaboration with Springer Publishing. This series will cover all aspects of Orthopaedics and is aiming to serve as a guide for Residents and Fellows who are preparing for their Residency or Board Exams.

I believe that for the young generation, FORTE means more than Orthopaedics. Because FORTE philosophy is based on education and education is the best tool to bring a positive change in society, to develop a generation of responsible individuals and contribute to the development of good human beings. It gives us wings and tells us where to fly, makes us socially aware and self-aware and helps us to walk on the right way. Literally, the fundamental purpose of FORTE is to create good human beings in addition to a good orthopedic surgeon



Revision of unicompartmental arthroplasty to total knee arthroplasty

**Philippe Neyret, Jeremy Cognault,
Sebastien Lustig, Elvire Servien.**

**Hospices de Lyon Croix Rousse - Centre
Albert Trillat**

INTRODUCTION

Many studies suggest revision UKA to TKA (U2T) is easy and leads to results comparable to primary TKA (PTKA) at long term outcome.

MATERIAL AND METHODS

A PubMed research has found

- 20 articles (it means 6902 UKA revision) were published during the past 6 years with a follow-up from 8 months to 15 years. including :
- 6 registry review (Australian, Swedish, New Zealand, Finnish, Wales),
- 5 were multicenter study
- 9 monocenter study
- 1 one review article about the papers previously published.

We also present our own experience.

RESULTS

Clinical outcome was good with an average KSS about 160. Many publications found the clinical outcome of U2T as good as PTKA, whereas few of articles found a poorer one. Nevertheless, all the studies agree there is no statistical difference for the range of motion in both groups. U2T requires often the use of stems, grafts, augments or revision implants. The cost of U2T is equal for implants or length of stay and cheaper than a RTKA. The risk of re-revision of a U2T is equal to a PTKA for 3 authors. The risk of revision of a UKA revised by a UKA is higher (about 30% at 4 year follow-up) than the risk of revision of a UKA revised by a TKA. French experience notice that in carefully selected patients, UKA-to-UKA revision performed according to a rigorous operative technique deserves a role in the surgical strategy for failed UKA.

We reported 53 patients at 4 year follow-up confirm literature results.

No major surgical difficulties were described, but skill and precision are mandatory. Obviously, preoperative planning (X-rays, CT scan) is crucial to manage bone loss and order appropriate implants.

CONCLUSION

Patients who require revision of a unicompartmental knee arthroplasty can benefit from surgical outcomes similar to a primary total knee arthroplasty, despite technical concerns such as use of stems and augments to manage bone loss and longer operative duration. The only problem is to deal with femoral component orientation particularly in rotation. To improve the outcome of UKA revision, the reasons of failure must be clearly known and managed. The revision of UKA is safer with TKA implant than with UKA implant.

REFERENCES

- Epinette JA, Leyder M, Saragaglia D, Pasquier G, Deschamps G, Societe Francaise de la Hanche et du G. Is unicompartmental-to-unicompartmental revision knee arthroplasty a reliable option? Case-control study. Orthop Traumatol Surg Res. 2014;100:141-5.
- Chatain F, Richard A, Deschamps G, Chambat P, Neyret P. [Revision total knee arthroplasty after unicompartmental femorotibial prosthesis: 54 cases]. Rev Chir Orthop Reparatrice Appar Mot. 2004;90:49-57.

Rotational and angular deformities of the lower extremities

Ozren Kubat

Department of Orthopaedic Surgery,
Clinical Hospital Centre Zagreb

Rotational and angular deformities of the lower extremity are uncommon, however variations in the rotational and angular profiles are very common complaints encountered in the pediatric orthopaedic surgeon's outpatient clinic.

It is important to be aware of these variations in children during growth, and reassure parents that they will eventually lead to "normal" lower extremity alignment at the end of growth. However, it is also important to know that a variation is considered a deformity when the amount of deviation from normal, for that particular age, equals more than two standard deviations. Rotational problems manifest as intoeing and out-toeing during gait. Intoeing is most commonly the results of increased femoral anteversion, internal tibial torsion and/or metatarsus adductus. Out-toeing is not as common as intoeing and the causes are similar, only opposite: femoral retroversion and external tibial torsion. Varus or valgus (bowlegs and knock-knees) make up the angular problems. These issues, isolated or combined, are very often seen in small children (e.g. less than three years of age), but when they persist into older age one should suspect a more serious underlying cause. In cases of pronounced deformities the clinician must look for underlying causes, which may be: previously unrecognized cerebral palsy, developmental dysplasia of the hip, spinal cord anomalies, vitamin D deficiencies, bone dysplasias, Blount's disease, etc. A careful history and detailed clinical examination can discern between variations of normal and deformities that require further evaluation and possibly treatment. In the past, many conservative modalities of treatment were developed. Over the years, almost all of these were proven to be ineffective. If real deformity exists, it usually needs to be addressed by surgical means, e.g. corrective osteotomies, guided growth, etc. Surgical treatment is usually utilized in older children with pronounced deformity, causing functional or significant cosmetic issues.

The most common problems of foot and ankle

Davor Bojić

Children's hospital Zagreb

Foot and ankle problems are common in the pediatric population.

Problems are usually related to skeletal maturity and are fairly specific to the age of the child.

An awareness of congenital anomalies, developmental variation, skeletal maturation and lower extremity alignment will aid the physician in evaluation and management.

Evaluation and management is challenging and requires a thorough history and physical exam, and understanding of the pediatric skeleton.

The clinical history should include a thorough description of the pain characteristics (location, character, onset, duration, change with activity or rest, aggravating and alleviating factors, night pain); trauma (acute macrotrauma, repetitive microtrauma, recent/remote); mechanical symptoms (locking, catching, clicking, instability, worse during or after activity); inflammatory symptoms (morning stiffness, swelling); neurological symptoms (weakness, altered sensation); gait (limp, altered weight bearing); effects of previous treatments and the current level of function of the child. Location of pain is the most important historical factor in aiding diagnosis.

Pain can usually be localized to the forefoot, midfoot, hindfoot or ankle. It is important for the clinician to be aware of conditions unique to the growing pediatric skeleton including congenital and developmental variation (pes planus, tarsal coalition, os trigonum, symptomatic accessory navicular, hallux valgus), apophysitis and osteochondroses (Sever's disease, Iselin's disease, Kohler's disease, Freiberg's disease), skeletal maturation (growth centers, growth plate fractures) and lower extremity alignment. Foot and ankle pain is occasionally caused by serious underlying systemic disease including inflammatory conditions and malignancies. The clinical history and physical exam often lead to correct diagnosis and identify cases requiring further evaluation, imaging or referral. Identification and treatment of predisposing biomechanical factors is important to reduce symptom recurrence. General return to play guidelines can be followed for most causes of foot and ankle pain.

Use of Soft Surgery in the Treatment of Club Foot

Hakan Ömeroglu

Eskisehir Osmangazi University Hospital,

Dept. Orthopaedics & Traumatology, Section of Pediatric Orthopaedics

Soft tissue surgery is still an important part of the treatment of clubfoot. While performing the manipulation and casting using the Ponseti method, achillotomy is needed in about 80% to 90% of the idiopathic cases. We prefer to perform percutaneous achillotomy in untreated mild-moderate cases, and open achillotomy in severe and relapsed cases under general mask anesthesia. From the age of 3 years, tibialis anterior tendon transfer to the third cuneiform is a well-worked operation in relapsed clubfoot cases. We have rarely performed extensive posteromedial soft tissue release for the last 10 years due to the high success rate of the Ponseti method. If needed an ala-carte procedure is the best way to handle such neglected cases. Clubfoot in myelomeningocele is another difficult problem to overcome. Manipulation and casting commonly fails in such cases and surgical treatment is frequently needed. An extensive procedure including resection of the posteromedial side tendons, meticulous release of the posteromedial capsule and lateral column shortening if needed provide acceptable results in neglected or relapsed cases.

Use of Soft Tissue Surgery in D.D.H.

Hakan Ömeroglu

Eskisehir Osmangazi University Hospital,

Dept. Orthopaedics & Traumatology, Section of Pediatric Orthopaedics

The treatment of D.D.H. is conservative under the age of 6 months. If the conservative treatment fails or the child admits to the hospital between 6 and 18 months of age, soft tissue surgery is one of the treatment options. The anterior approach allows capsulorrhaphy, which is an important part of the hip stabilization. However, it damages the iliac crest apophysis, additional incision is needed to release the adductors and most of the barriers to the concentric reduction are located in the inferomedial deep side of the wound. The medial approach provides an easy access to inferomedial extracapsular and intracapsular barriers to the concentric reduction. However, a capsulorrhaphy is not possible, most of the surgeons are not familiar with this approach and there are several concerns about the possibility of development of osteonecrosis of the femoral head and the use of this approach after walking age. The author has been using Ferguson's posteromedial approach for more than 20 years. A multicentric study group in which the author took place initially described, "limited posteromedial surgery in DDH under the age of 18 months". According this procedure, adductor longus and iliopsoas tendons are sectioned through the Ferguson's posteromedial approach and hip arthrography is performed. In case of an arthrographically documented concentric reduction the operation is ended and the hips are immobilized in a spica cast in human position. If the reduction is not considered concentric then an open reduction is performed. The mid-term radiological and clinical results of this technique are encouraging.



Tumors in children. State of the art management.

Marko Bergovec

**Department of orthopaedic surgery,
Medical University Graz**

Tumors and Tumor like Lesions: Epidemiology

Bone tumors is a group of various lesions, diverse in their size and morphologic features. Classification of primary bone tumors is made according to histological appearance. Three main groups are benign bone tumors, malign bone tumors and tumor like lesions.

The epidemiology of benign bone tumors is not known because many of those lesions are not biopsied. Many of those lesions are accidental findings on x-rays, performed for another reason. Benign tumors outnumber malignant tumors by at least hundred times. Nonossifying fibromas are the most common benign bone tumor in children: it is estimated that 30% of children have this tumor, although only a few have any symptoms. The second most common benign bone tumor is osteochondroma, which is often treated surgically because it causes mechanical irritation.

A group of various tumor-like lesions presents in a many different ways, from small asymptomatic lesions to locally big and aggressive aneurismal bone cysts. The most common tumor like lesion is simple bone cyst, often presented with a pathologic fracture.

Out of the malignant bone tumors, osteosarcoma is the most common, followed by Ewing sarcoma. While the overall primary malignant bone tumor incidence accounts about 0.5% of all tumors, in children and teenagers malignant bone tumors represent approximately 5% of all malignancies. Even more, malignant soft tissue tumors account another 5% of all malignancies in children. Still, this number in total count is relatively small: the yearly incidence of osteosarcoma is less than 2 per million, and for Ewing less than 1 per million.

Primary radiographic analysis is a first step in diagnosing bone tumors. By a hint of a tumor, a child should be referred to a orthopaedic centre experienced in tumor treatment. Additional imaging should be indicated by an orthopaedic oncologist. Finally, biopsy and pathohistology analysis are often performed. The treatment should consist of, when appropriate, preoperative chemotherapy, surgical wide excision of tumor and reconstruction, followed by the postoperative chemo- and/or radiotherapy.

Due to wide range and variety of bone lesions: ranging from benign to rapidly fatal, it is crucial to do a proper diagnose as fast as possible. Timely diagnosis allows appropriate treatment in order to increase chances of survival, but also maintain an affected limb and as much as possible maintain limb's function. Limb salvage surgery is performed in most of the patients.



Reconstruction surgery as challenge in young patient

M. Szendrői, J. Kiss, T. Perlaky, I. Antal

**Dep. of Orthopaedics, Fac. Gen. Med.
Semmelweis University, Budapest**

Aim of the study:

Reconstruction of the defect following the resection of the tumorous bone segment in tumour patient under the age 10 is always a challenge in case we want to perform a limb-saving surgery. The medullar cavity is narrow for both standard and custom made tumour endoprosthesis and we have to calculate with significant discrepancy in length destroying the growing plate. It is also extremely difficult to find a size-matched massive osteoarticular allograft for the joint reconstruction.

Material and methods:

We record more than 6000 cases in the Bone Tumour Registry of the Semmelweis University Budapest. Limb saving surgery is achieved in 87% of the cases needing a consecutive reconstruction of the defect. About 3 per cent of the patient in our material did not reach the age ten at the definitive operation. We analyzed the different options for the reconstruction in terms of complications, postoperative quality of life, usefulness of the saved limb.

Results:

Autologous fibula graft were used in 1 cases for the proximal part, in 2 cases for the diaphysis of the humerus. In 4 patients a one bone lower arm was created by fusion of the distal part of the radius and proximal part of the ulna. Metaphyseal resection saving the epiphysis and replacement of the defect by fibula was performed in 2 patients around the knee, in 1 patient around the hip. In one patient a vascularized fibula was used for the proximal part of the femur. Reuse of the tumorous bone segment following a denaturalization by autoclaving was used in 2 patients, by radiation in another 2 patients and by deep freezing in one patient. In two patients special custom-made tumor endoprosthesis was used for the hip. In two patients a resection through the epsilon cartilage was performed at internal hemipelvectomy. The rate of complications were about 30 per cent (fracture, pseudoarthrosis, infection, but non malunion), amputation was needed in 2 patients, one for local recurrence, one for extreme shortening and bone defect.

Conclusion:

Limb-saving surgery is always demanding in a bone tumour patient under the age 10. The strategy of reconstruction should be tailored always individually for every patients. The results and rate of complications are comparable with those of adults but of different nature.

Molecular technique in the diagnostic, planing and treatment of tumors

Aleksandra Bonevski

Children's Hospital Zagreb

Primary malignant solid tumors in children and young adults are rare diseases. Introducing the multimodal therapy which consists of chemotherapy, surgery and radiotherapy to the treatment four decades ago, has improved the survival rate, but still it hasn't reached the satisfactory level of healing. The approach to the tumor biology of cancer has been substantially changed by the identification of genes that were specifically affected in human cancer. The extensive application of the molecular techniques discovered the functional and structural gene alterations responsible for tumor induction and promotin of the tumor development and progression.

Therefore, using the molecular diagnostic techniques, especially in high risk patients, can provide benefit in staging, planing the treatment itself, and introducing specific therapy. Also, detection and follow-up of the minimal residual disease, give us the information about the tumor biology and how it is changing through the provided treatment plan, primary established at the time of diagnosis.

According to the information given by the new techniques in tumor biology, and complementing them with already established standard protocols of treatment, we are given the chance to improve the level of treatment for patients with primary malignant solid tumors.

Operative treatment of tumors and tumor like lesions

Marko Bergovec

Department of orthopaedic surgery,
Medical University Graz

The optimal management of a patient with a bone tumor is by a multidisciplinary team experienced in the diagnosis, oncologic and surgical management of bone pathology. The principles of surgical approach to benign tumors and tumor like lesions are quite different than of the treatment of malign bone tumors.

Treatment of benign bone tumors is focused on symptoms and/or prevention of negative local tumor behaviour. Removal of osteochondromas is mostly performed for mechanical irritation, osteoid-osteoma for pain, simple bone cyst for preventing future pathologic fracture. This symptome-based surgical treatment of benign tumors should be focused in the same time on tumor as well as on keeping full function of the extremity.

Malignant alteration of benign bone tumors is very rare: solitary osteochondroma could transform to chondrosarcoma, or osteoid-osteoma to osteosarcoma. In this cases postulates for malign tumor treatments are applied.

The main aim of surgical treatment of malign bone tumor is to completely remove the tumor tissue. On the list of principles, the whole orthopaedic oncology team should focus primary on keeping a patient's life, and then afterwards on keeping the extremity. Last, but still important, the surgeon should try to keep / restore as much function as possible. The first goal should not be jeopardised by the attempts to get a better function. By following these order of principles, it is clear that the perfect limb salvage operation that restores normal function is rarely possible. Most of the operations will restore function at a satisfaction level.

Improvements in understanding bone biology and better surgical techniques allowed using more and more biological reconstructions, like vascularised autografts, allograft-autograft composits and reimplantation of autograft after boiling, freezing or irradiating. Endoprosthesis implantation is very popular for good short term results and fast mobilisation of the patients, but long term results are still not satisfactory. Choosing the best reconstruction technique with optimal short and long term outcome remains one of the major challenges in orthopaedic oncology.



Supra condylar fractures in children. Still a challenge?

Manuel Cassiano Neves

Hospital CUF Descobertas, Portugal

The supracondylar fracture is the most common fracture around the elbow in children with a peak between 3 and 6 years of age and accounts for 22% of the fractures in children at age 2 to 4.

It results from a direct fall on the outstretched hand in the majority of the cases (fracture in extension) or from a fall over the elbow (flexion fracture – 5%), that sometimes is difficult to recognize due to its rarity. Because of the close interaction between the humerus and neuro-vascular structures around the elbow, several complications can be associated. It is fundamental to look for the associated injuries that constitute a challenge: the most common nerve palsy seen with supracondylar humerus fractures is the neuropraxia of the anterior interosseous nerve neuropraxia (branch of median n.) followed by the radial and ulnar nerve palsy. The vascular injury can be present in 1% of the cases and calls for close monitoring.

The clinical exam will show an elbow with oedema with a typical deformity with swelling, bruising and limited active elbow motion in the presence of a displaced fracture. On the physical exam it is fundamental to exam the neurovascular structures and look for the inability to flex the interphalangeal joint of his thumb and the distal interphalangeal joint of his index finger (can't make A-OK sign) or

inability to extend the wrist or digits due to radial nerve injury-

Vascular insufficiency at the initial stage can be present in 5-17% defined as cold, pale, and pulseless hand. A warm, pink, pulseless hand does not qualify as vascular insufficiency, since the rich collateral circulation can maintain circulation despite vascular injury.

Radiographs will help in the final diagnosis: on the lateral view the anterior humeral line should intersect the middle third of the capitellum. In a case of a SC fracture in extension the capitellum moves posteriorly to this reference line in the extension type.

On the AP view a Baumann's angle is created by drawing a line parallel to the longitudinal axis of the humeral shaft and a line along the lateral condylar physis. Normal is 70-75 degrees, but best judge is a comparison of the contralateral side. Deviation of more than 5 degrees indicates coronal plane deformity and should not be accepted.

Giving the displacement of the fragments fractures are classified according to Gartland: Type I no displacement, Type II displaced but posterior cortex intact and Type III full displacement.

Recently the AAOS come up with guidelines regarding the treatment of SC fractures in children: the recommendation goes for a plaster with the elbow in flexion (below 90°) for the Type I and close reduction and pin fixation for the Types II and III. There is still some debate between the configuration of the construct with no clear indication between the lateral entry pins versus the cross pin configuration. However it seems that the lateral entry is safer with less neurological complications and with the same stability when compared with cross-pins.

The challenge is the treatment of the fractures with complications: nearly all cases of neuropraxia following supracondylar humerus fractures resolve spontaneously, and therefore, further diagnostic studies are not indicated in the acute setting. For the fractures associated with vascular injury emergency reduction is indicated and this solve the absence of pulse in the most of the cases. In the presence of a no-pulse with hand is mandatory the vascular exploration



Late Monteggia: how to solve it?

Darko Antičević

**Department of Orthopaedic Surgery,
University of Zagreb, Zagreb, Croatia**

DEFINITION

Monteggia lesion is complex elbow/forearm injury which is consisting of radial head/capitellum dislocation with fracture of proximal or mid-shaft ulna. In immature ulnar bone injury may be a greenstick fracture or "simple plastic" deformation and could be unappreciated.

Late (chronic) Monteggia lesion is a radiocapitellar dislocation that still persists 4 (four) weeks after injury due to unreduced primary lesions or missed diagnosis frequently after ulnar greenstick fracture or "plastic" deformation

HISTORY

First description (1814.) of fracture/dislocation by Giovanni Battista MONTEGGIA (surgical pathologist, Milan, Italy). José Luis BADO (chief orthop. surg., Montevideo, Uruguay) in the year 1958. subdivided fracture in four types according to direction of ulnar fracture angulation and radial head dislocation, and he coined the term "Monteggia lesion". Classification is published in English in the year 1967.

AETIOLOGY AND MECHANISMS OF INJURY

The aetiology is traumatic and mechanism is proposed by Tompkins (1971). The child falls on an outstretched arm with the elbow joint forced in hyperextension. The radial head is dislocated anteriorly by strong reflexive biceps contraction. The weight of the body is then solely on the ulna which breaks on anterior cortex by tension force.

PATHOMORPHOLOGY

In acute Monteggia lesion annular ligament could be damaged and interposed within radio-ulnar joint as it is observed during surgical reduction. Occasionally, an intact annular ligament may be pulled over the radial head obstructing closed reduction.

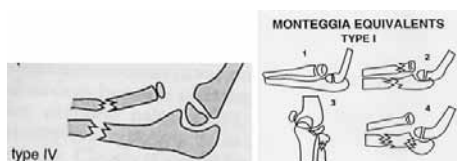
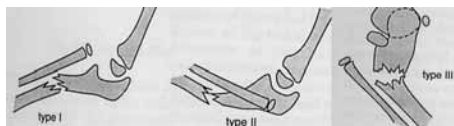
In chronic radial head dislocation pathologic changes of elbow joint were studied by Kim et al. (2002.). Dysplastic changes were observed in both congenital and posttraumatic group:

- ▶ large deformed radial head;
- ▶ slender radial neck;
- ▶ ulnar bowing;
- ▶ radio-capitellar incongruence.

These changes are likely to produce pain, limitation of motion, osteoarthritis and disability in adulthood.

CLASSIFICATION

Bado classification of Monteggia lesion and equivalents (1958.) is the most accepted one in the literature.



DIAGNOSIS

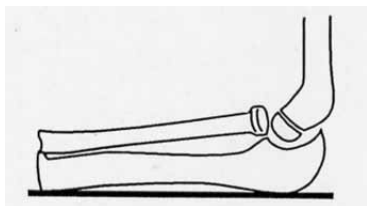
In acute Monteggia lesion diagnosis of ulnar fracture is visible on good quality X-rays that include whole forearm with elbow and radio-carpal joints. Note: plastic ulnar deformation and greenstick fracture could be missed, especially in a busy ED (Gleeson & Beattie, J Acc & Emerg Med, 1994; Perron et al., Am J Emerg Med 2001).

A high degree of suspicion is needed. Ulnar bow sign could be helpful as described by Lincoln & Mubarak (JPO 1994.). Deviation of the ulnar border from the

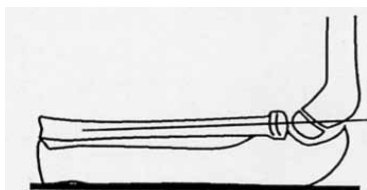


reference line is shown on schematic drawing (A). Positive sign is deviation of more than 1 mm.

A



B



Soft tissue part of Monteggia lesion could be overlooked by inexperienced physician, even if ulnar fracture is diagnosed. Another, radio-capitellar line is helpful to check normal radiocapitellar congruence. A true lateral X ray view of the elbow is needed. A line passing through centre of radial head and neck should extend directly through the centre of capitulum, regardless of the degree of elbow flexion or extension as it is shown on schematic drawing (B). Recently questioned by Ramirez et al. (JPO 2014)

DIFFERENTIAL DIAGNOSIS

a) Congenital dislocation of the radial head

- usually bilateral, posterior direction, X-ray features: radial head is convex, enlarged, irregular and eccentric; capitulum is flattened.

b) Pathological

- Neuromuscular: Erb's palsy; cerebral palsy, arthrogryposis (amyoplasia);
- Hyperlaxity syndromes: osteogenesis imperfecta;
- Tumors like conditions: multiple exostosis, Morbus Ollier.

TREATMENT (FOR DELAYED DIAGNOSIS = CHRONIC CASES)

- Indications (Papandrea & Waters, 2000; Wilkins 2002.):

- ▶ progressive radio-capitellar subluxation or dislocation;
- ▶ progressive valgus deformity;
- ▶ limited range of elbow or forearm motion;
- ▶ pain at the malaligned radiocapitellar or radioulnar joint;
- ▶ age less than 12 years;
- ▶ concave radial head (convex, deformed radial head would not produce congruous radio-capitellar joint);
- ▶ long time span from original injury is not a limitation for surgery if above conditions are fulfilled.

- Treatment options:

- ▶ watchful waiting;
- ▶ open radio-capitellar reduction + ulnar osteotomy (plate & screws vs. Ex. Fix)
- ▶ open radio-capitellar reduction + ulnar osteotomy + annular ligament reconstruction:
 - a) Bell-Tawse procedure w/ a slip of triceps tendon
 - b) Hui et. al. (JPO, 2005.) w/ forearm fascia

Controversy:

- ulnar osteotomy + overcorrection (YES or NO?)
- addition of trans-capitellar K-wire fixation (YES or NO?)



COMPLICATIONS

Reconstruction of chronic Monteggia lesion in children may be associated with

numerous complications (Rodgers et al., JBJS /Am/ 1996; Đapić et al. 2004.):

- 1) nerve lesions - radial and ulnar nerve;
- 2) malunion of ulnar shaft;
- 3) residual radiocapitellar subluxation;
- 4) non-union at ulnar osteotomy site;
- 5) ulnar fracture below the osteotomy site;
- 6) compartment syndrome.

CONCLUSION

Late reconstructive procedures of chronic Monteggia lesion should not be attempted before learning the basic principles that need to be addressed. A thorough study of the possible complications is mandatory before surgery is performed. Current best possible treatment for anterior lesion (Bado type I) is ulnar flexion angulation (with elongation, if necessary); fixation with plate/screws or external fixation (recent reports). Open reduction of radio-capitellar joint, if necessary.

REFERENCES

(selected references for extended reading)

1. Bado JL. The Monteggia Lesion. *Clin Orthop* 1967;50:71-86.
2. Best TN. Management of old unreduced Monteggia fracture dislocations of the elbow in children. *J Pediatr Orthop* 1994;14:193-9.
3. Bor N, Rubin G, Rozen N, Herzenberg JE. Chronic anterior Monteggia lesions in children: report of 4 cases treated with closed reduction by ulnar osteotomy and external fixation. *J Pediatr Orthop* 2015;35:7-10.
4. Đapić T, Antičević D, Bilić R, Duvančić D. Reconstruction of chronic Monteggia's lesions in children. *Acta Clin Croat* 2004;43:371-7.
5. Exner GU. Missed chronic anterior Monteggia lesion. *J Bone Joint Surg (Br)* 2001;83:547-5.
6. Geeson AP, Beattie TF. Monteggia fracture-dislocation in children. *J Acc & Emerg. Med* 1994;11:192-4.
7. Goyal T, Arora SS, Banerjee S, Kandwal P. Neglected Monteggia fracture dislocation in children. A systematic review. *J Ped Orthop B* 2015;24(3):191-9.
8. Gyr BM, Stevens PM, Smith JT. Chronic Monteggia fractures in children: outcome after treatment with the Bell-Tawse procedure. *J Pediatr Orthop B* 2004;13:402-6.
9. Hamilton W, Parkes JC. Isolated dislocation of the radial head without fracture of the ulna. *Clin Orthop* 1973;97:94-6.
10. Hasler CC, Von Laer L, Hell AK. Open reduction, ulnar osteotomy and external fixation for chronic anterior dislocation of the head of the radius. *J Bone Joint Surg (BR)* 2005;87:88-94.
11. Hirayama T, Takemitsu Y, Yagihara K, Mikita A. Operation for chronic dislocation of the radial head in children. *J Bone Joint Surg (Br)* 1987;69:639-42.
12. Hui JHP, Sulaiman AR, Lee H-C, Lam K-S, Lee E-H. Open reduction and annular ligament reconstruction with fascia of the forearm in chronic Monteggia lesions in children. *J Pediatr Orthop* 2005;25:501-6.
13. Kim HT, Conjares JN, Suh JT, Yoo CI. Chronic radial head dislocation in children, Part 1: Pathologic changes preventing stable reduction and surgical correction. *J Pediatr Orthop* 2002;22:583-90.
14. Kim HT, Park BG, Suh JT, Yoo CI. Chronic radial head dislocation in children, Part 2: Results of open treatment and factors affecting final outcome. *J Pediatr Orthop* 2002;22:591-7.
15. Nakamura K, Hirachi K, Uchiyama S, et al. Long-term clinical and radiographic outcomes after open reduction for missed Monteggia fracture-dislocation in children. *J Bone Joint Surg (AM)* 2009;91(6):1394-404.
16. Lincoln TL, Mubarak SJ. "Isolated" traumatic radial-head dislocation. *J Pediatr Orthop* 1994;14:454-7.
17. Lu X, Kun Wang Y, Zhang J, Zhu Z, Guo Y, Lu M. Management of missed Monteggia fracture with ulnar osteotomy, open reduction and dual-socket external fixation.



- J Pediatr Orthop 2013;33(4):398-402.
18. Lloyd-Roberts GC, Bucknill TM. Anterior dislocation of the radial head in children. Aetiology, natural history and management. J Bone Joint Surg (BR 1977;59:402-7.
19. Papandrea R, Waters PM. Posttraumatic reconstruction of the elbow in the pediatric patient. Clin Orthop Relat Res 2000;370(Jan):115-28.
20. Perron AD, Hersh RE, Brady WJ, Keats TE. Orthopaedic pitfalls in the ED: Galeazzi and Monteggia Fracture-Dislocation. Am J Emerg Med 2001;19:225-8.
21. Pletcher D F-J, Hoffer MM, Koffman DM. Non-traumatic dislocation of the radial head in cerebral palsy. J Bone Joint Surg (Am) 1976;58:104-5.
22. Ramirez RN, Ryan DD, Williams J et al. A line drawn along the radial shaft misses the capitellum in 16% of radiographs of normal elbows. J Pediatr Orthop 2014;34(8):763-7.
23. Rahbek O, Deutch SR, Kold S, Søjbjerg JO, Møller-Madsen B. Long-term outcome after ulnar osteotomy for missed Monteggia fracture dislocation in children. J Child Orthop 2011;5(8):449-57.
24. Rodgers WB, Waters PW, Hall JE. Chronic Monteggia lesions in children. Complication and results of reconstruction. J Bone Joint Surg (Am) 1996;78:1322-9.
25. Santos MM. Monteggia fractures in children. Surgical Techniques in Orthopaedics and Traumatology 55-250-A-30, 2002:p.1-6.
26. Tompkins DG. The anterior Monteggia fracture. Observation on aetiology and treatment. J Bone Joint Surg (Am) 1971;53:1109-14.
27. Wilkins KE. Changes in the management of Monteggia fractures. J Pediatr Orthop 2002;22:548-54.



Elbow instability in children

Manuel Cassiano Neves

Hospital CUF Descobertas, Portugal

Elbow instability in children and adolescents is rare when compared with other injuries around the elbow. But when we look at the incidence including all ages almost 50% have the first episode in the first two decades.

The stability of the elbow joint is dependant 50% on the osseous constrains and 50% on the soft tissue (capsule and ligament) stabilizers. The mechanism of injury is mostly a fall on the outstretched hand with a posterior dislocation either associated with a valgus or a varus mechanism. This will determine the associated lesions, medial pillar involvement in valgus (the most common) and the lateral pillar in the varus deformity.

The dislocation can be classified according to the displacement of the distal fragments or the injury of the ulnar-radio ligaments. Accordingly to Carlioz this classification is not reliable since in his series, the dislocation was posterior in 100% of the cases and associated with a fracture of the medial epicondyle in 60%. For this reason we recommend to divide the instability according to the involvement of the bony lesions: type I no involvement, type II involvement of the medial pillar and type III involvement of the medial and lateral pillar. This classification also has a prognostic value since for the type I and II it is expected to have 88% of good clinical results in contrast with 38% of the type III.


The clinical exam will show an elbow with oedema with a typical deformity with a posterior displacement of the tip of the olecranon. On the physical exam it is fundamental to exam the neurovascular structures.

The diagnosis is based on radiology AP and lateral views. Attention should be paid for the screening of occult fractures and in particular joint entrapment of the medial epicondyle.

All dislocations should be reduced under anesthesia and reduction should be confirmed on the x-rays and as the same time associated bony lesions should be ruled out. A stress test should be performed in order to evaluate associated lesions. In case of severe instability as in Type II and III the injured structures should be repaired in order to avoid late complications, like axial deformity, peri-articular calcifications, joint stiffness or chronic instability

Chronic elbow instability is rare but in our series it accounts for 5.9% of 78 elbow dislocations. It can also be associated with ligament injuries associated with a pots-traumatic cubitus varus as pointed out by O' Driscoll.

The goal in the treatment of an elbow instability is to have a correct diagnosis in order to avoid pitfalls. A stress test after reduction should be made in order to screen major soft tissue lesions and the treatment should be done according to the anatomic lesion. You can expect good clinical results for Type I & II



Saturday



Foot and ankle

Jurij Štalc

**Valdoltra Orthopaedic Hospital,
Slovenia**

AAFD is defined as collapse of medial longitudinal arch in patients with previously arched feet. Tibialis posterior tendon (PTT) failure is an important step in the pathogenesis of this condition. Patients complain of medial ankle pain. Swelling over PTT can be seen. Heel is in valgus and forefoot is abducted to various degree. Several radiographic parameters can be used to describe the amount of deformity with Meary's angle and talo-navicular uncoverage being the most widely used.

AAFD is classified into four types according Myerson. Type II is defined by inability to perform single heel rise test due to the pain and dysfunction of tibialis posterior tendon but the deformity remains flexible and can be passively corrected. Anderson introduced subtypes A and B according to the amount of talo-navicular uncoverage and subtype (C) which covers patients with forefoot varus after passive correction. In type III rigidity occurs, the deformity cannot be passively corrected. Types I and IV remain controversial. Type IV is characterized by talar valgus caused by the deltoid dysfunction. As type III never progresses to IV it should be classified as another disease. Type I is defined by PTT tenosynovitis with no deformity.

Treatment of later stages is usually surgical. Type III is addressed with hindfoot fusion in a corrected position. Treatment of type II usually consists of combination of bony and soft tissue procedures. Medial displacement calcaneal osteotomy, lateral column lengthening, Cotton osteotomy and Lapidus fusion are the main bony procedures. Damaged PTT is replaced by transfer of the flexor digitorum tendon. Other soft tissue procedures include gastrocnemius recession, peroneus brevis recession and suturing of damaged plantar calcaneo-navicular (spring) ligament. The role of the sinus tarsi implants or arthroereisis of subtalar joint in treatment of type II AAFD remains unproven.



Current possibilities of reconstructive spinal surgery

Vladimir Kovač, Stjepan Dokuzović

Clinical Hospital Dubrava, Zagreb

Spinal surgery is a relatively new specialty. It is still not clear whether it is an orthopaedic or neurosurgical subspecialty, or a completely new specialty. Great effort has been made to organize formal education in spinal surgery in Europe. Currently, there are 5 modules (basic, degenerative, tumors & trauma, deformities, revisions & complications), leading to the formal European spine diploma.

There are still many controversies that are waiting to be better investigated, documented and explained. National registries provide us with new data, which will probably change our perception of spinal surgery in the future.

Degenerative:

Fusions

It seems that market interests are currently tending to make spine surgery less invasive rather than to make it more successful. It is generally accepted that success of solid bony fusion can be achieved in nearly 95%. However, results from registries suggest that only successful pain relief in DSD is achieved in only 50% of cases. In 38%, pain remains unchanged while in 12% there is even worsening, mainly due to the instrumentation. There is no difference between different surgical instrumentations. Fusion without instrumentation gives equally good clinical results. What can we learn from that?

Arthroplasty

It seems that adjacent level disease is a definitely proven entity (after single segment fusion?).

Use of cervical arthroplasty is therefore in definite expansion. On the contrary, enthusiasm for lumbar arthroplasty is decreasing despite favourable FDA judgment.

Posterior non fusion techniques offer controversial clinical results. There are insufficient data about indications and efficacy.

Tumors & Trauma

There is a variety of instrumentations, from minimally invasive vertebroplasties, to complex en block resections and reconstructions. Different evaluation scoring systems (Tomita, Tokuhashi, SINS, etc.) serve to prevent under or overtreatment. However, better oncologic prediction is necessary.

Osteoporotic fracture treatment is increasingly being performed. Short term results are obviously good, but long term results of this systemic disease treatment are still not documented well enough. Cost of treatment makes this form of surgery problematic in underdeveloped countries.

Deformities

Posterior techniques are standard. Data about screw protrusions in spinal canal in free hand techniques raise questions about neuromonitoring and navigation. It makes this surgery extremely complex and expensive, and this is particularly a problem in underdeveloped countries. Anterior mobilization and instrumentation techniques eliminate the problem, offering better correction, and safer instrumentation. However 10% of respiratory loss, demanding anterior surgery and potential balance problems must be taken into consideration. Early onset scoliosis is a challenge and there is no adequate instrumentation at the moment

Revisions

Anterior and/or posterior osteotomies, wedge resections, are well established in salvage surgery. High complication risk limits this type of surgery to highly specialized centers.

Conclusion

Obviously, widespread spine surgery is in increase and a separate spine surgery specialty will be the definite future.



Shoulder arthroscopy - tips and tricks for young orthopaedic surgeons

Boris Poberaj

**Orthopaedic Hospital Valdoltra,
Jadranska c. 31, 6280 Ankaran**

Shoulder arthroscopy is primarily dedicated to treat soft tissue around the shoulder joint and very rarely to be just a diagnostic tool. It means that diagnosis must be known before someone enters the joint.

Patient position during surgery, beach chair or lateral decubitus, is always debatable and usually individual surgeon's preference.

Shoulder is a 3D joint, thus orientation is crucial. Certain anatomical structures, such as subscapularis tendon, long head of the biceps, GH ligaments can be perfect landmarks. The best way to start arthroscopy tour of the joint is to follow a checking list of all visible structures of the joint even when pathology is very well defined already before surgery.

While dealing with certain pathology it is always of great benefit to switch the scope to different viewing portals in order to get better 3D appreciation

Portals? The first entry portal for the scope is standard posterior one which is defined by palpation of posterior GH rim. All the rest portals are made on demand, using the spinal needle first to define the best entry point. Even at standard procedures, such as Bankart repair, as there might be some individual anatomical peculiarities, portals must be adapted accordingly.

Cannulas? Probably useful at the beginning, especially in instability cases where multiple entries are needed inside the joint through the capsule. Once triangulation has been learned and the instruments skillfully used, surgery without cannulas is much easier, because the instruments have no conflict with plastic tubes and thus a greater range of working field is enabled.

Care must be taken when tissue ablation electrodes are used to control the outflow of hot water to prevent skin burns.

The instruments used during arthroscopic surgery must feel as an extension of fingers. This issue and other technical tricks will be shown on videos.



Marrow and inflammatory cells in subchondral bone remodeling in osteoarthritis

Jeroen Geurts and Thomas Hügle

**Osteoarthritis Research Center Basel,
Orthopaedic Department, University
Hospital Basel, Basel, Switzerland**

Osteosclerosis of the subchondral bone is a pathological hallmark of osteoarthritis and can be routinely detected by conventional radiographs or computed tomography. There is an increasing body of evidence that extensive subchondral bone remodelling plays an active and decisive role in the progression of osteoarthritis, exerting direct mechanical and biochemical effects on cartilage tissue. While obviously strongly influenced by biomechanical factors, bone remodelling is a biological process involving osteoblasts, osteocytes, osteoclasts, blood capillaries and various bone marrow cells such as macrophages and mesenchymal stem cells. Since bone formation principally is a reversible process, molecular targeting of aberrant bone remodelling is an emerging strategy for treatment of osteoarthritis.

However, the cellular and molecular mechanisms of aberrant subchondral bone remodelling leading to osteosclerosis in osteoarthritis remain incompletely understood. Compositional changes of the subchondral marrow compartment in human osteoarthritis have been frequently observed using magnetic resonance imaging and these bone marrow lesions are a prognostic factor for disease progression and correlate spatially with sites of cartilage degeneration. Molecular changes to human subchondral osteoblasts, including elevated expression of alkaline phosphatase and transforming growth factor-beta1 and blunted matrix mineralization in vitro, have been implied to be involved the onset and/or progression of osteoarthritis.

Here, we summarize current research efforts of phenotypical characterization of the cellular component of the subchondral bone unit in human osteoarthritic joints using advanced tissue culture techniques, direct flow cytometry and immunohistological analyses. We have identified a specific association of increased marrow inflammatory cells and osteoclasts with subchondral osteosclerosis in knee osteoarthritis. In addition, osteoprogenitors from knee and hip osteoarthritic joints revealed stable molecular imprinting of a sclerotic bone phenotype. Elucidation of the molecular pathways - in and between - marrow and inflammatory cells involved in aberrant bone remodelling is therefore warranted and holds potential for orthobiologic treatment of osteoarthritis.



Evidence based medicine principles in Orthopaedic and Traumatology

Vladimir Trkulja

Zagreb University School of Medicine

The term "Evidence Based Medicine" (EBM) was coined some 35 years ago to depict a concept implying that decisions in medicine should be based exclusively on the "best available evidence" gathered from valid experimental clinical research. Initially, it referred almost exclusively to therapeutic interventions – primarily pharmacological, but it subsequently extended to all other therapeutic interventions, including surgery, physical therapy, psychotherapy etc. Nowadays, the EBM-concept is practiced (or should be practiced) in all areas of medical decision-making: diagnostic, prognostic and therapeutic.

Orthopaedics is a specific clinical branch that deals with a variety of diseases/diseased conditions with greatly variable etiology or "contributing risk factors", employs a range of clinical, laboratory and radiological diagnostic tests and implements a range of therapeutic interventions: surgical, pharmacological, physical. Hence, the complexity of prognostic, diagnostic and therapeutic decision-making is considerable. With ever evolving technological/technical/pharmacological development, the need for ability to critically recognize, evaluate and judge "evidence" about values and disadvantages of such new procedures/concepts is essential. While in the past "surgical" medical branches were considered inappropriate for evaluation by the EBM methodology, it is nowadays obvious that there is absolutely no reason why EBM methods/reasoning would not be implemented in full in daily orthopedics decision making. The present talk outlines several key points related to methodology of evaluation of diagnostic procedures, prognostic factors and therapeutic interventions using orthopedic examples and illustrates the process of overall evaluation of the "body of evidence".



FREE PAPERS
Thursday

Clinical parameters after Fondaparinux vs Nadroparin thromboprophylaxis in total knee arthroplasty

Damjan Dimnjaković

KBC Zagreb, Croatia

Regarding the possible perioperative complications such as deep vein thrombosis or pulmonary embolism, the role of thromboprophylaxis in orthopedic surgery is extremely important. Fondaparinux, with no cases of HIT proven until today, is a direct Xa inhibitor which is indicated to be as effective as LMWH. The main goal of our prospective randomized control trial was to define if the thromboprophylaxis in patients undergoing TKA due to primary osteoarthritis of the knee, influences clinical parameters in the same manner in patients receiving Fondaparinux as in those receiving Nadroparin during the first 14 postoperative days. Unilateral TKA was performed by a single surgeon at our Department in sixty patients with primary osteoarthritis of the knee. Patients were randomized into two groups consisting of 30 patients each, receiving thromboprophylaxis with either Fondaparinux or Nadroparin. Comparison between groups was made regarding laboratory results (CBC, aPTT, PT, CRP, SE, D-dimers), duration of the operation, perioperative blood loss (intraoperative bleeding, postoperative autotransfusion, postoperative bleeding and postoperative allogotransfusion), and clinical evaluation of the edema of the operated leg during the early postoperative period. Regarding the average duration of the surgery or the perioperative blood loss, no statistically significant differences were found between the groups. Similar results were also found regarding the CBC, aPTT, PT or D-dimers as well as clinical signs of the edema of the knee and the lower leg. The only statistically significant difference was found between the groups regarding the level of urea, which was significantly lower in the Nadroparin group on the first and second postoperative day. No cases of HIT, DVT or PE were noted during this study. Our results show that both Fondaparinux and Nadroparin have the same influence on clinical parameters during the first 14 postoperative days in patients undergoing TKA.

Contemporary approaches in using of autologous platelet rich plasma in order to stimulate meniscal healing.

Džihan Abazović

Emergency medicine centre of Montenegro, Montenegro

Introduction

Meniscal injury treatment that doesn't request operative management is limited and includes physical therapy compression elevation and icing so using of an alternative is justified. The use of platelet - rich - plasma (PRP) to improve clinical outcome following soft tissue regeneration has been the subject of intense investigation and discussion.

Goals

To present the results of research and advances of PRP activated by AT (AT) in reducing size of meniscal lesion and decreasing time of healing. Materials and Methods Study is designed to demonstrate achievements in meniscal lesion treatment by use of activated PRP It presents the preliminary results of a pilot project. Experimental group includes the meniscal injuries which don't request surgical treatment. We draw ml of whole blood from which after the processing we obtained platelet - rich - plasma and AT The average count of platelets in PRP was - x baseline. Before the application we activated PRP with AT The ml of final product was injected in the knee joint space We conducted the clinical and MRI investigation. to observe healing process. Results Preliminary in RENOVA clinic Belgrade we have done of the planned procedures of preparation and application of activated PRP for meniscal injuries. Clinical outcome in treated patients shows shorter time of rehabilitation and MRI have shown the increased healing in treated patients compared to our usual practice.

Discussion

We are considering the possible use of PRP activated with AT as way of stimulation of healing process in meniscal injuries that don't require surgical treatment.

Conclusion

The use of activated autologous PRP gives great results in terms of clinical outcomes in patients with meniscal injury. The current results of our research which is still in the preliminary phase support this hypothesis.

NF- κ B signalling controls ADAMTS5 gene expression in OUMS27 cells

Dilek Gün Bilgiç, Ömer Faruk Hatipoğlu, Sadık Çiğdem, Esra Gündüz, Mehmet Gündüz

Turgut Ozal University, Selcuk University, Turkey

Osteoarthritis (OA) is the most common joint disease characterized by cartilage destruction, subchondral bone sclerosis, and osteophyte formation. The primary proteases responsible for aggrecan cleavage that the major proteoglycan of cartilage structure, aggrecanases, are members of the ADAMTS (A Disintegrin And Metalloprotease with ThromboSpondin motifs) family of metalloproteases. In the cartilage, ADAMTS4 and ADAMTS5, have been isolated. The knock-out mice of ADAMTS5 are protected from cartilage degradation in the mouse OA models. Seguin et. al (2005) showed that in response to TNF α in nucleus pulposus cells, ADAMTS-5 gene expression up-regulated. The nuclear factor kappa B pathway is a mutual pathway activated by several cytokines, including TNF- α , and can later induce elevated expression of aggrecanases. To understand the mechanism of ADAMTS-5 gene regulation by NF- κ B, we stimulated HEK 293T and OUMS27 cells with TNF α and IL-1, after RNA and protein isolation at different time points, we performed RT PCR and western blotting to assess expression levels of ADAMTS5, I κ B α and TNF α . There was a significant difference between control and stimulated cells in terms of I κ B α and TNF but not ADAMTS5 in HEK 293T cells. However, the results were quite promising in OUMS27 cells. We have cloned possible kB sites containing regions in ADAMTS-5 promoter to luciferase reporter vector. HEK 293T and OUMS27 cells were transfected and luciferase assay was performed. One construct with the possible kB site showed induced luciferase activity. Taken together, these results bring some new evidence that NF- κ B signalling specifically controls ADAMTS5 gene expression in OUMS27 chondrocytes.

Variation in differentiation potential in clonal mesenchymal stem cell populations

WS Khan, Hardingham TE, G Blunn, D Marsh

University College London IOMS, Royal National Orthopaedic Hospital, Stanmore, UK

Aims

Synovial mesenchymal stem cells are a potential source of cells for the repair of articular cartilage defects. Our aim was to identify clonal populations and determine whether they differed in characterisation and differentiation potential.

Methods

Mesenchymal stem cells were isolated from the synovium of patients undergoing total knee arthroplasty and expanded in culture. Six clonal populations were also isolated before initial plating using limiting dilution and expanded. The cells from the mixed parent population and the derived clonal populations were characterised for stem cell surface epitopes, and then cultured in osteogenic medium for 21 days and as cell aggregates in chondrogenic medium for 14 days. Gene expression analyses; glycosoaminoglycan and DNA assays; and immunohistochemical staining were determined to assess chondrogenic responses.

Results

Cells from the mixed parent population and the derived clonal populations stained strongly for markers of adult mesenchymal stem cells including CD44, CD90 and CD105, and they were negative for the haematopoietic marker CD34 and for the neural and myogenic marker CD56. A variable number of cells were also positive for the pericyte marker 3G5 both in the mixed parent and clonal populations. The clonal populations exhibited a variable chondrogenic response.

Conclusions

Pericytes are a candidate stem cell in many tissue and our results show that all six clonal populations derived from the heterogenous synovial fat pad population express the pericyte marker 3G5. The variable chondrogenic responses suggest inherent differences between these populations. The chondrogenic potential of the synovium could be optimised by the identification of clonal populations with a propensity to differentiate down particular differentiation pathways.

Expression of inducible nitric oxide synthase and nuclear factor kappa B in synovial membrane in patients with osteoarthritis of the knee

Marko Ostojić

University clinical hospital Mostar, BiH

Introduction

Osteoarthritis affects the whole joint, not just the cartilage. Synovitis plays a key role in the progression of the disease. The amount of inflammatory factors is higher in early than in late osteoarthritis. NF-kB-dependent activation of the iNOS promoter supports the stimulation of an inflammatory process. The expression of iNOS has a dual function in Nf-kB regulation, depending on the cell type which it affects.

Objective

To determine the difference in severity of the Krenn's synovitis score in early and late osteoarthritis and in a control group (staged radiologically). Also, to analyse NF-kB and iNOS expression in synovial membrane and determine which cells expressed forementioned factors. Every tested parameter was correlated to the clinical stage of the disease by WOMAC score.

Methods

The research was performed on 29 biopsies of synovial membrane. Ten biopsies were taken from patients with mild radiological changes (Kellgren-Lawrence scale), ten from patients with severe changes and nine from control group. Immunohistochemical reactions and double immunofluorescence staining were used for the expression and localization of Nf-kB and iNOS. WOMAC score and general information were taken from the patients.

Results and conclusion

Krenn's synovitis score was significantly higher in early than in late osteoarthritis. Examined factors were present in fibroblasts, macrophages, endothelial and smooth muscle cells. Epithelial cells and stroma of synovial membrane showed significantly higher NF-kB expression in early than in late osteoarthritis. Epithelial cells in patients with late osteoarthritis had a high number of iNOS positive cells, reflecting the localised inflammatory process, and causing the inhibition of NF-kB production there. MMP-9 was expressed in macrophages of late osteoarthritis as well as in CD5+ lymphocytes in late osteoarthritis.

New Regime for Thromboprophylaxis in Knee Arthroplasties

Hussein Noureddine

William Harvey Hospital, United Kingdom

The nice guidance for elective total knee replacements states that patients should be given mechanical thrombo - prophylaxis and if no contraindications chemical thromboprophylaxis in the form of Dabigatran etexilate Rivaroxaban UFH LMWH or Fondaparinux sodium (CG92 January). In Practice administering oral agents has been the dominant practice as it reduces the nursing needs and shortens hospital stay and is generally received better by patients. However there are well documented associated bleeding risks and their effects are difficult to reverse in case of major bleeding. Our experience with oral factor inhibitors used for thromboprophylaxis was marked with several patients developing complications necessitating return to theatre for wound washouts. This has led us to try a different protocol for thromboprophylaxis that we applied on our patients undergoing total and unicondylar knee replacements. We applied mechanical thromboprophylaxis in the form of intermittent pneumatic pressure devices and chemical thromboprophylaxis in the form of one dose of prophylactic LMWH pre - op then mg of Aspirin to start hours after the surgery and to continue for weeks alongside GI cover with PPIs or antihistamines. We also administered local anaesthetics intra - operatively in line with the ERAS protocol thus encouraging early mobilization. We have identified a cohort of patients who underwent one of the aforementioned procedures in the same trust and by the same surgeon where this protocol was applied and examined their medical notes retrospectively with a mean follow - up period of months to identify the rate and percentage of patients who had thrombo - embolic events in the post - operative period.

Tranexamic acid in hip and knee arthroplasty our experiences

Petar Cvijić

Institute of Orthopaedics, physical medicine and rehabilitation Dr. Miroslav Zotović, BiH

Introduction

Tranexamic acid is the antifibrinolytic agent. Its antifibrinolytic effect is achieved by blocking the binding of lysine to plasminogen and moving into active form - plasmin, and in higher doses performs inhibition of plasmin activity.

Objectives

To present our experiences in the application of tranexamic acid in reducing intra and post-operative bleeding, as well as complications, compared to patients to whom tranexamic acid was not applied.

Materials and methods

We observed 80 patients who underwent hip and knee arthroplasty at the our Department for the period November 2013-May 2014. They were divided into two groups - 40 patients treated with tranexamic acid (Group 1) and 40 patients to whom tranexamic acid was not administered (Group 2). Laboratory parameters were monitored (RBC, Hgb, Htc preoperatively and postoperatively), the occurrence of increased or prolonged bleeding, the amount of required units of blood and blood derivatives, postoperative hematoma size and appearance of thromboembolic complications (ultrasound control after a month).

Results

Mean preoperative values of monitored parameters in both groups were within reference values. Mean postoperative values of Hgb, RBC and Htc were closer to the reference values in the Group 1. Also in the Group 1 significantly less intraoperative bleeding and postoperative loss on drain were seen. To patients in Group 1 a total of seven units of blood and blood derivatives (0.18 U per patient) were administered, while the patients in Group 2 received 51 units (1.3 U per patient). In Group 1 significant reduction in the size of postoperative hematoma was observed.

Conclusions

The use of tranexamic acid significantly reduces intra- and post-operative bleeding, the use of autologous transfusion sets, the need for blood and blood derivatives, as well as related complications. On the other hand there is economic importance of tranexamic acid use.

First metatarsal head osteotomy for the correction of moderate hallux valgus with and without lateral release

Goran Vrgoc, Maki Grle, Vladimir Hohnjec, Ivan Bohacek, Zdravko Jotanovic, Marko Martinac

Department of Orthopaedic Surgery, University Hospital Sveti Duh, Croatia; Department of Orthopaedic Surgery, University Hospital Center Mostar, Mostar, Bosnia and Herzegovina; Department of Orthopaedic Surgery, University Hospital Centre Zagreb, Zagreb, Croatia, University Hospital for Orthopaedics and Traumatology Lovran, School of Medicine, University of Rijeka, Rijeka, Croatia; Addiction Prevention and Out of hospital Care Centre, Mostar, Bosnia and Herzegovina

Introduction

Hallux valgus (HV) presents one of the most common deformities of the foot. In this study we compared patients with or without lateral soft tissue release (LSTR) undergoing Austin procedure in treatment of moderate hallux valgus deformity.

Methods

We had two groups of patients, Group I consisted of 23 patients (25 feet), average age 55 (range, 43 to 77) years, which underwent Austin osteotomy alone (without LSTR); and Group II which consisted of 18 patients (23 feet), average age 59 (range, 52 to 70) years, which underwent Austin osteotomy with LSTR. X-ray imaging of the feet in weight bearing antero-posterior (AP) and latero-lateral (LL) projection were done in all patients preoperatively and postoperatively and Hallux Metatarsophalangeal-Interphalangeal scale (AOFAS Hallux MTP-IP) scoring postoperatively. We measured hallux valgus angle (HVA), intermetatarsal angle (IMA), proximal articular set angle (PASA), distal articular set angle (DASA) and measurements of the position of medial sesamoid bone on AP weight bearing radiograph using modified Hardy and Clapman system. Patient's postoperative satisfaction survey was also performed.

Results

In both groups HVA and IMA improved on postoperative X-rays. Significantly better results of the medial sesamoid bone position on X-rays was achieved in Group II. Patients' satisfaction score as well as AOFAS Hallux MTP-IP survey score was higher in Group II. The results showed significant improvement of PASA postoperatively in both groups.

Conclusion

We may conclude that distal metatarsal osteotomy for moderate HV deformity correction combined with LSTR provides better results than procedure without LSTR in terms of improved X-ray together with overall patient's satisfaction score.

Epidemiological data of rehabilitation after total knee arthroplasty

Jakov Prenc, Damir Hudetz

Clinic of Traumatology Zagreb, Croatia

The main objective of this paper is to analyze the effect of rehabilitation in recovery after postoperatively the way to determine the difference in the clinical-functional tests of the knee joint. We will try to prove that we can do better outcome results by our on-line instructions for rehabilitation through recorded video material where every patient is on their own at their own home. The SF-36 is a multiapplicable health status questionnaire with 36 questions. These are questions with multiple choice answers. The SF-36 is a theoretically based and empirically proven operationalization of two general concept of health-physical health and mental health and their two general events: the functioning and well-being. The study included 30 patients who were treated according to the same protocol, which consisted of preoperative preparation, surgery and post-operative rehabilitation in hospital and spa. The scientific contribution of this research is significant for clinical orthopedic practice. This study evaluated a completely new approach and the use of new platforms for part of the recovery process in which patients are mostly left to themselves and the organization of rehabilitation, which does not always follow their needs. With the help of this method, we could communicate to patient daily in the early stages of recovery important messages to the possibility of performing kineziotherapy through the video instructions which could shorten the postoperative period of rehabilitation and improve clinical outcomes.

Uncemented total knee arthroplasty, with minimum 2 years follow-up

Srdjan Dojcinovic, Renaud Maes, Sladjan Marinkovic, Vladicin Han, Mirko Kovacevic

Clinique Générale, Switzerland

Review of the literature shows mixed results regarding uncemented total knee arthroplasty (TKA). To our knowledge, there are no reports of results for uncemented TKA that incorporates a ultra-dish and rotating platform design. It is theorized that these design features could decrease the stress at the bone-implant interface. This study reports results on 100 uncemented TKAs (XNOV) at a minimum of 2-year follow-up. Average Knee Society clinical score improved from 52.9 to 95.1; average Knee Society functional score improved from 60.5 to 82.0. Ninety-eight percent of patients had excellent and 2% had good results based on Knee Society scores. There was 99% implant survival; 1 patient required revision of a loose tibial component after an infection. The promising short-term results support the continued use of this implant and suggest a prospective randomized study comparing cemented vs uncemented TKA of this design is warranted.

Medial Unicompartmental Knee Arthroplasty in Patients Less Than 50 Years Old: Minimum of Two Years of Follow-Up

Srdjan Dojcinovic, Renaud Maes, Sladjan Marinkovic, Vladicin Han, Mirko Kovacevic

Clinique Générale, Switzerland

The appropriate treatment when joint degeneration is limited to the medial compartment remains controversial in young people. Alignment osteotomy are well studied for genu varum. The purpose of this work was to evaluate the midterm results in a series of medial unicompartmental-knee prostheses in people under fifty years.

Material and methods

Forty five mobile bearing, uncemented, medial unicompartmental arthroplasties were performed in 18 men and 27 women with a mean age of 49 years (range, thirty-three to fifty-five years old) at the time of surgery from 2007 through 2010 among a total of 200 total knee arthroplasty. The mean preoperative IKS was 102 (range: 54 to 164). Implants used were uncemented Xnov Kaps. The IKS score was established preoperatively and at last follow-up. Outcome assessment searched for clinical, radiological and surgical criteria affecting survival. The Kaplan-Meier method was used to determine implant survival.

Results

Forty patients (45 knees) were reviewed at mean six years (range: five to seven years). Mean IKS at one year was 185. At last follow-up, mean IKS was 166 (range: 28 to 200). Overall malalignment without revision was 2° (range: -2 to +6°). Two arthroplasties were revised, all for extension of the degenerative disease (two supplementary in total-knee arthroplasties).

Discussion

The results of this investigation suggest that UKA offers an attractive alternative to TKA and high tibial osteotomy in appropriately selected, younger active patients. We hypothesize that these outcomes are related to improved implant design and surgical technique but also to preservation of the cruciate ligaments and the unresurfaced compartments. Continued clinical follow-up and observation of this cohort will be necessary to determine construct durability at longer-term follow-up.

Salvage procedures after revision surgery of periprosthetic fractures in TKA

Knoth C, Zettl R, Hess F

Department of Orthopaedics and Traumatology Kantonsspital Frauenfeld, Switzerland

We present 2 cases of complications in periprosthetic fractures of the distal femur after two time revision of knee arthroplasty that were finally treated with a modular total femur megaprosthesis. The first case, a 84 year old patient, showed a loosened femoral component after cemented revision total knee prosthesis 4 years earlier. We decided to do a TKR with a replacement prosthesis (megasytem-c, Link Germany) for the distal femur because a lot of bone stock was lost after implant and cement removal. The distal femoral replacement prosthesis loosened 4 month later and a pathological fracture occurred above the stem. To preserve as much bone as possible a modular megaprosthesis was implanted. A total hip arthroplasty was performed through a minimal invasive antero-lateral approach and stems were connected with a modular rod that was inserted through the femoral canal. The second case, a 73 year old multimorbid patient with severe parkinsons disease, showed a loosened femoral component after primary total knee replacement 3 years earlier. A two-step TKR was performed. Four month later a periprosthetic distal femur fracture above the stem occurred and was treated by minimal-invasive osteosynthesis. Two months later a fracture of the proximal femoral shaft occurred spontaneously and was treated with a proximal intramedullary nail. Three month later after breakage of the periprosthetic locking plate all implants were removed and a total femoral replacement was performed with a modular megaprosthesis. Implants were connected with a modular rod that was stuck through the femoral canal to preserve as much bone as possible. In both patients 6 months results showed good results. We recommend total femoral replacement with a modular megaprosthesis through a two incision technique where soft tissue damage is minimized and as much bone stock as possible can be preserved.

Bone loss management in difficult primary and revision total knee surgery

Boris Žulj, Saša Rapan, Zoran Zelić, Vjekoslav Kolarević

University Hospital Osijek_ Department of Orthopaedic Surgery, Croatia

Thanks to great functional results and survivorship rate there is great increase in total knee surgery around the world during past two decades. Now we are facing growing number of knees that has to be revised as a result of loosening, implant failure or infection. Total knee revisions are becoming more and more almost everyday procedure with lots of challenges to overcome as a result of bone loss and patient's expectations to have fully functional and painless knee. Bone loss management is also often issue in primary total knee implanting especially when we are dealing with patients with rheumatoid arthritis or posttraumatic osteoarthritis. The goal of this presentation is to show difficult cases and examples and educate how can we deal with bone loss using modern revision implants from our own experience.

Hook of hamate non union presented and initially mistreated as ulnar nerve compression

Mario Josipovic, Ivan Bohacek, Tomislav Smoljanovic, Ivan Bojanic,

Department of Orthopaedic Surgery,
University Hospital Centre Zagreb,
University of Zagreb, School of
Medicine, Croatia

Hamate hook (HH) stress fractures are rare often presented with misleading symptoms and thus easily overlooked or misdiagnosed. These fractures occur frequently in individuals participating in sports activities involving racquets bats or clubs. Symptoms are non-specific and often mimic other clinical conditions such as ulnar nerve entrapment or ulnar vessel thrombosis - year-old tennis player with no history of trauma presented with dominant hand weakness together with pain and paresthesia on ulnar side which exacerbated with tennis play. Patient was treated for ulnar nerve compression with activity cessation and rest for months. After months of persistent symptoms patient underwent open Guyon tunnel release albeit preoperative EMNG revealed no signs of nerve damage and bone scans showed small area of increased uptake in hypothenar region. Postoperatively symptoms resumed and patient reported to our Department for second opinion. We have reconsidered preoperative diagnostic findings and performed clinical examination which revealed point tenderness over HH hypothenar muscles hypotrophy paresthesia hand weakness and pain with ulnar deviation of hand and flexion of distal phalanges of ulnar two fingers HH fracture was suspected CT scan revealed fractured HH and patient underwent surgical treatment for hook excision One - month postop pain intensity reduction together with improvement in function and strength were observed while - months postop patient was pain-free and returned to tennis Preop - and - month postop DASH scores were and In patients involved in racket sports with pain in hypothenar and paresthesia of ulnar side of the hand HH fracture should be suspected. Special emphasis should be put on patients ' history and clinical examination Symptoms can mimic ulnar nerve entrapment since HH forms Guyon ' s tunnel - therefore irritation and swelling of surrounding tissue in chronic cases can compress ulnar nerve Treatment.

Arthroscopic capsulolabral reconstruction in posterior glenohumeral instability facing various intraarticular pathology

Nenad Medancic, Nikola Cicak, Hrvoje Klobucar

SB Akromion, Croatia

Hypothesis

Posterior shoulder instability is less common than anterior instability, and its arthroscopic treatment can be technically demanding. Weather the amount of damaged tissue, intraarticular pathology, weather it happens in athletic or non-athletic population there are different reconstruction techniques.

Material and Methods

In our hospital we treated 20 patients for posterior instability (16 athlete injuries, 2 car accident injuries and 2 hyper laxity syndromes) by using anchors performing posterior labrum fixation with or without capsular plication. In total there were 14(70%) men and 6(30%) women, mean age 24 (from 15 to 31), 17 right and 4 left shoulders including one patient with the bilateral operation. There were 16(80%) athletes (13 overhead athletes), with 11 posterior labrum ruptures, 9 SLAP lesions, 4 partial supraspinatus lesion, 6 of them with normal capsule and 10 with redundant capsule. 4(20%) non-athlete patients had had both labral and redundant capsule. Different operation techniques were used and combined depending of the pathology. We performed 2 reoperations, one because of the early postoperative shoulder injury and one in patient with hyper laxity syndrome performing the anterior stabilization in the revision operation.

Results

Evaluation was performed using the Oxford instability score. According to the Oxford instability score there were significant improvements in stability, pain, and function in all patients. Overall, all patients were able to return to sport, with 95% of patients able to return to the same level postoperatively.

Conclusion

There are various intraarticular pathologies in people suffering from glenohumeral instability, some of them need to be fixed and some of them don't, depending on patients symptoms as well as on their profession. Arthroscopic capsulolabral reconstruction is an effective, reliable treatment for posterior glenohumeral instability.

Reverse total shoulder arthroplasty in patients with rheumatoid arthritis – current concepts and our experience

KBC Zagreb, Croatia

Danijel Matek

Objective

Reviewing recent literature and presenting our experience in treatment of patients diagnosed with rheumatoid arthritis and rotator cuff deficiency and reporting their outcomes following reverse shoulder arthroplasty.

Methods

We performed a systematic review of the literature to evaluate the functional outcome of patients with rheumatoid arthritis treated by reverse shoulder arthroplasty. Secondary outcome measures of range of movement, pain scores and complication rates were also monitored. In the period 2008-2015 we treated and evaluated eleven patients (twelve shoulders) with rheumatoid arthritis and advanced stage rotator cuff deficiency by reverse shoulder arthroplasty. None of them had prior shoulder surgery. Patients were followed for a minimum of 18 months (average, 29 months). All patients had preoperative radiographs, MR and/or CT for evaluation of muscular and bony deficiency. Patients were evaluated for loosening and scapular notching by performing radiographs.

Results

In the observed studies majority of measured outcomes (ASES, SST, VAS pain scores, VAS function scores, elevation, abduction, external and internal rotation) improved significantly. Complications were statistically less common than in patients with other causes of glenohumeral arthroplasty. Main reason was instability due to glenoid erosion. Out of eleven patients (twelve shoulders) we treated and evaluated, two had a revision operative procedures, instability due to glenoid erosion and the second one for glenoid notching.

Conclusions

Patients with rheumatoid arthritis and advanced stage of rotator cuff deficiency can benefit from reverse shoulder arthroplasty by significant improvement in function and decreased pain. Usually, there is a high rate of component lucency observed, but revision procedures are fairly uncommon.

An overview of periprosthetic fracture management after shoulder arthroplasty

Christoph Knoth

Kantonsspital Frauenfeld, Switzerland

Worldwide the numbers in primary shoulder arthroplasties due to demographic changes and success rate of shoulder arthroplasty are rising. Therefore more periprosthetic fractures occur in the upper limbs around the shoulder and represent an increasing challenge in the clinical practice in orthopaedics. With an ageing but very active population and factors such as multimorbidity and osteoporosis the complexity of periprosthetic fractures increases steadily. As the prosthesis may be implanted cementless or cemented and multiple designs exist, different fracture patterns can be found and different treatments are required. Especially intraoperative fractures, the majority of periprosthetic fractures in shoulder arthroplasty, require immediate treatment. Therefore a long stem prosthesis has to be on offer when a primary shoulder prosthesis is implanted. We use the classification by Worland and its recommendations for management of periprosthetic fractures. Treatment options include implantation of a cemented long stem, open reduction and internal fixation with locking plates with polyaxial fixed-angle screws and conservative treatment. We recommend the algorithm suggested by Worland and demonstrate its use in several cases of our own collective in periprosthetic fractures (cemented/ non cemented stem, comminuted/simple fractures/ glenoid fracture) after shoulder arthroplasty.

Modified Eden Lange procedure for trapezius palsy; A case report

Tomislav Tabak, Nikola Čičak

Akromion Special hospital for Orthopaedic Surgery, Croatia

Insufficiency of the spinal accessory nerve lead to paralysis of trapezius muscle. Patients with chronic paralysis of trapezius, as a result of nerve palsy, have painful shoulder, reduced range of motion, weakness of active elevation and asymmetry of the shoulder. Most common reason of accessory nerve palsy are surgical procedure on the neck, external trauma and sometimes it may occur without any known aetiology. Incorrect initial diagnosis is very often and diagnosis is usually delayed. We are presenting the patient, male, 34 years old. He injured right shoulder 2 years ago in traffic accident. He complains on pain and weakness in right shoulder. Until now he was treated with physical therapy, without success. Clinical examination show; asymmetry of the shoulders and neckline, atrophy of the right trapezius muscle. Active flexion in shoulder is full, abduction is feasible until 85°, during the motion there is no rotation of scapula. The medial edge of the scapula is moving away laterally – winging scapula sign is positive, but classical wall test is negative. Weakness of the right hand during flexion and abduction. Ultrasound showed that trapezius muscle on the affected side is 4 mm thick; on another side it is 13 mm thick. EMNG showed lesion of the accessory nerve. We performed modified Eden Lange procedure, transposition of the rhomboideus major in the fossa infraspinati; rhomboideus minor to the spine of the scapula and levator scapulae to the acromion. Eight months after operation patient doesn't have any pain in shoulder, full range of motion is present, winging scapula sign is negative, during elevation scapula moving laterally. Crease of the levator scapulae is in very good shape. The Eden-Lange procedure is known like very good treatment of accessory nerve palsy and paralysis of trapezius. In our case modified Eden Lange procedure also has very good result.

Longitudinal versus Transversal incision in the DeQuervain disease: a comparative study

Miguel Frias, Tiago Pinheiro Torres, Ricardo Santos Pereira, Daniel Saraiva, Pedro Canela

Centro Hospitalar de Vila Nova de Gaia Espinho, Portugal

The DeQuervain disease is a tenosynovitis of the first extensor compartment. Its surgical treatment was first described by Fritz de Quervain. The use of longitudinal or transverse incision has been described in many studies. The ideal incision should allow a good visualization of the radial aspect of the wrist and an easy extension in case of an unforeseen situation such as the presence of anatomical variations. The purpose of this study was to compare the clinical results of the use of longitudinal incision with transverse incision in the surgical treatment of DeQuervain disease. We retrospectively evaluated 88 patients (92 wrists) surgically treated to a DeQuervain tenosynovitis from March 2005 to March 2013. Most of the patients were female and the mean age was 55.7 years with a mean follow-up of approximately 7 years. The right wrist was operated in most cases. A longitudinal incision was used in 58% of the cases and a transverse incision in the remaining. The total percentage of complications was 9%, with 43% of cases affecting patients with longitudinal incision and 57% patients with transverse incision. This difference was not statistically significant. The most common complications were the development of painful neuroma, palmar subluxation and paresthesias in the territory of the sensory branch of the radial nerve. Of patients with complications, 50% required surgical reintervention. The average QuickDash score was 27.3 in patients with longitudinal incision and 28.4 in patients with transverse incision. There was no statistically significant difference between the two scores. In the presented series there were no statistically significant differences between the two incisions with respect to post-operative complications and scores.

Acceleration of healing of long bone fractures in patients with concomitant severe head injuries

Fathy G. Khallaf, Elijah O. Kehinde,
Sundus Hussein, Sameh I. Al Shinawy

Department of Orthopaedic Surgery,
Jahra Hospital, Ministry of Health,
Kuwait

Background

The regulation of bone healing after long bone fractures is subtle and there is clinical evidence to suggest that fractures heal more rapidly in patients with head injuries.

Aim

The primary aim of this controlled prospective study was to compare the healing potentialities of long bone fractures in head injury patients. The secondary aim is to investigate the mechanism of possible accelerated osteogenesis.

Material and methods

Patients were recruited into Group (A) with severe head injuries Group (B) with severe head injuries with long bones fractures Group (C) with long bones fracture only and Group (D) of healthy subjects. Union time maximum thickness of union callus and union rate were calculated for fractures in groups B and C. Blood was extracted to measure the level of parathyroid hormone growth hormone corticosteroids adrenalin noradrenaline and leptin hormone growth factors (IGF - II PDGF VEGF and Activin A), and cytokines I - L. Results fractures in patients were in group (B) in which MUT was range (-) weeks MTUC was range (-) mm and MUR was range (-) mm week fractures in patients were in group (C), fractures (%) united and (%) went into atrophic non - union. The MUT in this group was range (-) weeks. The MTUC was range (-) mm. The MUR was range (-) mm week. Patients in groups A and B showed higher levels of parathyroid hormone and growth hormone and normal corticosteroids levels ($p <$). Patients in group C showed higher level of noradrenalin and adrenalin hormones compared to patients in groups A and B ($p <$). PDGF VEGF Activin A and cytokines I - L showed higher levels during the weeks of follow - up in patients of group B ($P >$). IGF - II showed subnormal level in the same patients ($P >$).

Conclusions

Accordingly we can conclude that long bone fractures in head injury patients heal more expectedly faster and with exuberant callus with a possible combined neuro - hormonal mechanism to explain this accelerated healing.

A new locking plate and dynamic screw system for internal fixation of intracapsular hip fractures; results for the first 530 patients treated

Daniele Pili

GVM Mangioni Hospital Lecco, Italy

The Targon Femoral Neck Hip Screw has been designed to improve the fixation of intracapsular hip fractures. Fracture healing complications after internal fixation occur in approximately 10% of undisplaced fractures and 30-50% of displaced fractures. The new implant consists of a small plate with six locking screws. The two distal holes are used to fix the plate to the femur. Three of four screws are passes through the proximal holes and across the fracture site. These 6.5mm screws are dynamic to allow for collapse of the fracture across the femoral neck. A jig is used to aid insertion of the device with minimal surgical exposure of the femur. For the first 518 patients treated with this implant at the first centre to use this implant, the mean age of the patients was 76 years, 58% were female. The mean length of surgery was 46 minutes and the mean length of anaesthesia 59 minutes. The median length of institutional stay till discharge home was 9 days (mean 13 days, range 1-107). Four telescoping screws were used in 55% of patients, three in 44% and two in 1% of patients. Follow-up of patients at present is a minimum of six months. For the 185 undisplaced fractures there have been six cases of non-union and six of avascular necrosis. For the 233 displaced fractures (Garden III and IV) there have been 42 cases of non-union, 25 cases of avascular necrosis and five cases of plate detachment. In addition there was one deep wound sepsis treated by girdlestone arthroplasty. The results to date show an incidence of fracture healing complications is about a half that which is to be expected with a parallel screw method. This new implant may be a significant advance in the treatment of this difficult and common fracture.

„Bio-logical“ carbon fiber –peek intramedullary nailing for humeral shaft fractures - international multi-center experience

Nikša Kojić

Poliklinika Marin Med Dubrovnik,
Croatia

Traditional metal alloys used in IM implants have a Young modulus - times greater than surrounding bone which may be causative to delayed union non union and re - fracture of the bone. A newly designed implant CFR - PEEK IMN „ Piccolo “ humeral nail (Carbo - Fix Orthopaedics Ltd) is made of % continuous (endless) carbon fibers embedded in % Polyaryl - Ether - Ether - Ketone (PEEK) matrix. Mechanical testing showed that CFR - PEEK implant to be as effective as metal devices in provision of intramedullary stability however due to low elastic modulus similar to cortical bone it is expected to lessen the degree of stress shielding therefore expedite bone healing and lower the incidence of non – union and re - fracture. Due to it \ ' s radiolucency CFR - PEEK implant allows superior radiographic visualisation both intraoperatively and at later follow up or during CT or MRI imaging. This work demonstrates cumulative multicenter experience gained since „ Piccolo “ CFR - PEEK nail was introduced in June. Multicenter study comprised patients with humeral shaft fractures and in all patients „ Piccolo “ nail was implanted using standard antegrade approach. Mean operative time was minutes and mean x - ray exposure time during surgery was sec. No intra - operative complications were recorded. Healing of fracture sites was observed through callus formation progress stated as no callus fair callus and good callus „ fair “ callus was observed at \pm days (range to), and to show progression to „ good “ callus \pm days (range to). Regardless of relatively small cohort of this study and it \ ' s retrospective design promising data were generated through observed ease and safety of implant use and appropriate fracture.

Male sexual dysfunction after pelvic fracture

Ana Čizmić, Margareta Bajsić Beljak,
Ivan Karlak

University Hospital Centre Sestre
milosrdnice Zagreb, Croatia

Male sexual dysfunction after fracture of the pelvis is more common than previously supposed with rates as high as 30 % reported when the complaint is specifically sought. With the increased in survival from major injuries the long-term consequences of the trauma are being seen with increasing frequency. Erectile dysfunction has been defined as the inability to achieve or maintain an erection adequate for sexual satisfaction. Sexual dysfunction can be due to urethral, vascular, neurologic and psychogenic injuries. In men, disruption of the posterior urethra in association with pelvic fracture has been shown to result in impotence, with the incidence rate as high as 50 %. In our survey we looked for the male patients who had the injuries of the anterior and posterior wall of the pelvis. They answered the questions about the effects of their erection problems given in IIEF (The international index of erectile function). The clinical interpretation was due to total score from severe dysfunction to no dysfunction.

Painful Nonunion After Missed Juvenile Tillaux Fracture In An Athlete - Description Of New Fixation Technique With Soft Suture Anchor

Ricardo Santos Pereira, Daniel Saraiva Santos, José António Campos Lemos, André Sarmento

Centro Hospitalar Vila Nova de Gaia / Espinho, Portugal

Introduction

A juvenile Tillaux fracture is a relatively uncommon avulsion fracture of the anterolateral corner of the distal tibial epiphysis that occurs in adolescents. Surgical treatment is recommended in acute cases with more than 2 mm displacement. There are no published reports on the management of nonunion after a missed juvenile Tillaux fracture in an athlete.

Objectives

We aim to present a case of a 14 year old female competitive basketball player that was initially diagnosed with a mild ankle sprain after sustaining a forced external rotation type of injury. Because of persistent ankle pain and inability to return to her sporting activity the patient was referenced to our institution where radiographs and CT-scan showed a small minimally-displaced Tillaux fracture. A course of conservative treatment with 6 weeks non weight-bearing in a short-leg cast followed by a progressive rehabilitation protocol were unsuccessful in returning the athlete to full sporting activity. At 6 months after the initial injury another CT-scan was performed showing nonunion of the fracture and operative treatment was decided.

Methods

The patient was treated with open reduction and, because of the small size of the epiphyseal fragment, soft anchor fixation was preferred over the more common lag screw fixation. The anchor was placed immediately medial to the anterolateral fragment and anatomic reduction was maintained with a braided suture strand passed in a figure-of-eight manner through the antero-inferior tibiofibular ligament. Results: The patient was full weight-bearing by the 10th week and returned to her previous sporting activity level with no complaints by the 14th post-operative week.

Conclusion

Suture anchor fixation of a Tillaux fracture may be a viable option when the anterolateral physeal fragment is too small for lag screw fixation.

Do patients with hip fractures admitted over the weekend have worse outcomes compared to those admitted on weekdays; a retrospective case control study.

S.Kechyn, H. Noureddine, J. Peck, M. Dadras, S. Suleiman

William Harvey Hospital, United Kingdom

The concerns about patients having worse outcomes if they were admitted over the weekend are not novel, and multiple reports have looked into that. The authors have elected to specifically target the patients admitted with hip fractures, as they commonly are elderly with multiple comorbidities, and keen pre-operative and post-operative care is prudent for them. We have undertaken a retrospective comparative study, in which we identified a cohort of 64 patients admitted with hip fractures over the weekends of the period extending between August 2013 and May 2014, and retrospectively compared their outcomes in terms of length of hospital stay, inpatient mortality, and destination of discharge, to those of a randomly chosen cohort of 64 hip fracture patients admitted over the weekdays of the same period. The results revealed that the length of hospital stay was similar in both groups, however there was a statically significant increase of in-hospital mortality, and decrease in the number of patients discharged directly from the hospital to their homes among the weekend group in reference to the the weekdays group. In conclusion our data suggest that patients admitted with hip fractures over the weekend are likely to have worse outcomes compared to their weekdays counterparts, yet we accept that our cohort sizes are relatively small and further work should ensue.

Frequency of infections in politraumatized patients after operating treatment

Sandra Slabe, Ivan Dobrić

University hospital center Zagreb,
Croatia

This study is performed by a theatre scrub nurse about frequency of infections in polytraumatized patients. Primary aim of the study was to evaluate the incidence of wound infections and infections of urinary tract, pneumonia and sepsis in polytraumatized patients treated at the Department of Surgery in University Hospital Center Zagreb and in the operating unit of the department in one year period. Secondary goal was to assess the quality of nurses' work and care in the operating unit and to evaluate possibilities for improvement. Results of the study confirmed that frequency of infections is not dependent on quality of our work and care but on numerous associated risk factors in these critical patients; but there are still some possibilities for improvement which nurses can implement to improve standards of work and care in the operating theatre. **KEY WORDS:** politrauma, infections, operating treatment, theatre scrub nurses

The effect of induced brain injury and spinal cord injury on the union of femoral osteotomy in rabbits

Fathy G. Khallaf, Elijah O. Kehinde,
Sundus Hussein, Sameh I. Al Shinawy

Department of Orthopaedic Surgery,
Jahra Hospital, Ministry of Health,
Kuwait

In prospective controlled study, we tested the effect of induced brain injury and induced spinal cord injury on healing of femoral fractures in animals. 12 rabbits with brain injury and femoral osteotomy fixed with k-wire group (A) and 12 rabbits with dorsal spinal cord injury with femoral osteotomy and fixation group (B) were followed-up radiologically 3 and 6 weeks and compared to control group of 12 rabbits with femoral osteotomy and fixation only group (H). 24 rabbits with femoral osteotomy, fixation and 1 ml serum allograft from brain injury rabbits on a carrier in 12, group (C) and from spinal cord injury in 12, group (D) compared to control groups of 48 rabbits in groups (E) to (H). Group (A) and (B) rabbits showed early union callus in 3 weeks in 20 rabbits (83.3%) and all osteotomies united in 6 weeks with abundant callus, while group (H) rabbits showed 6 nonunion (50%). It was found that sera from rabbits with inflicted brain or spinal cord injury have no osteogenic effect on femoral osteotomy of other rabbits. We concluded that central nervous tissue damage enhances bone healing and serum from rabbits with brain or spinal cord injury has no osteogenic effect.

The impact of the Irish economic recession of 2008_ and the evolution of spinal surgery in the West of Ireland_ 2005 2013.

Michael O'Sullivan,

Galway University Hospitals, Ireland

The impact of the Irish economic recession of 2008, and the evolution of spinal surgery in the West of Ireland, 2005-2013. Background To determine the impact The Irish Economic Recession of 2008 and the associated service restrictions, in the short and long term, on the trends within the practice of spinal surgery in Galway University Hospitals (GUH) over a 7 year period, January 2005- January 2013. Methods A retrospective review of all spinal cases conducted in both GUH hospitals was recorded for the years 2005, 2006,2008,2009,2012 and 2013 respectively. Characteristics of the spinal surgery performed where recorded. They included, Anatomical Region, the use of instrumentation, the number of levels spinal accessed , and pathology treated. Statistical Analysis was performed using R and Excel Statistical Analysis for graphs. Poisson regression was used for absolute numbers. Chi-squared test was used for trends in ratios. Two-tailed tests used with p value<0.05 considered for statistical significance. Results On analysis of the trends in spinal surgery during the study period we found that there has been statistically significant (p<0.05) increase in all aspects of spinal surgery with the exception of surgeries for single level ,lumbar and infection pathology respectively. Conclusion The volume and complexity of spinal surgery has increased during the study period. Trends towards multilevel and instrumented spinal surgery is undeniable. Based on these results spinal surgery appears to be refractory to economic recession in the West of Ireland.

PLIF and Unilateral transpedicular fixation

Saša Rapan

KBC Osijek, Croatia

Introduction

The goal of this paper is to evaluate clinical and radiological results after the PLIF method using only unilateral transpedicular fixation with polyaxial screws.

Material and methods

8 men and 13 women (51,12 years old, 37-67) were operationally treated with the PLIF method and the implantation of carbon CAGE filled with spongiosis, got by resection of lamina, facet joint and processus spinosus, contralateral posteromedial spondylosis with allograft and ipsilateral transpedicular fixation. 13 patients(61,9%) were non smokers. 18 operations on L4-5 level and 3 procedures on L5-S1 level. The aproximative duration of the procedure was 105 minutes. The clinical and radiological report was recorded before and 6 months after the procedure.

Results

On the VAS scale the recovery of 7,7 (back) and 7,2 (leg) was recorded, on 2,1 and 1,8 (p<0,0005). Six months later, fusion was recorded in 19 patients (90,4%).

Conclusion

PLIF with unilateral fixation and contralateral posteromedial fusion is successful method in treating mechanical back pain.

Is there a place for minimal invasive and endoscopic surgery on the lumbar spine – Are there any advantages for the future?

Stefan Hellinger

Isar Klinikum Munich, Germany

At the end of the 80ies the technology for endoscopes made a step forward what led to a recovery for the neuroendoscopy. On the spine surgeons like Kambin, who made the first working channel scope for disc herniations, gave it a new input. This step was made by the confrontation with disadvantages of open surgery and the goal to minimize the surgical morbidity by using the new techniques of visualisation and surgery. We can demonstrate this on the MRI measurement of muscle damages compared to open microdissectomy. The endoscopic surgery of the spine allows a minimal surgical trauma on the approach, to do surgery only in the region of pathology even under local anaesthesia, avoids postaggressive metabolism and gives a fast recovery to the patient. At all it is a minimal aggressive surgery. To do these techniques special skills, trainings and knowledge are required. Also the use of the new technical possibilities must be learned. Meanwhile exist a lot of different endoscopic techniques on the lumbar and cervical spine. Especially the different approaches, transforaminal, interlaminar, translaminar on the lumbar spine as well as the anterior or posterior on the cervical spine must be common for an endoscopic surgeon. This demands often a shallow learning curve. Nowadays all kinds of discal pathologies beside stenosis can be treated by endoscopy. The value of these techniques has been proofed in a lot of scientific papers. Randomized controlled studies are available beside our daily experience Here is not only the outcome, without any inferiority of the endoscopic surgery, an important parameter. The endoscopic surgery of the spine today is a less traumatic and effective option for the surgery of the spine beside the classical microsurgery.

4 Years outcome after microtubular disc decompression with radiowave disc treatment for herniated discs

Stefan Hellinger

Isar Klinikum Munich, Germany

Purpose

A high - frequency radiowave system which combines with a manual microtubular nucleotomy for the treatment of degenerative disc disease and herniations of the lumbar spine has been developed. In this investigation we have collected clinical data on efficacy and safety of high radio frequency ablation in conjunction with a manual discectomy of the lumbar intervertebral disc over a year period.

Methods

Patients with radicular pain syndromes due to a contained herniated disc were enrolled in this prospective clinical study. Patients underwent a spinal procedure during which the disc herniation was treated with a manual discectomy and high radio frequency ablation using a microtubular approach. Outcomes were assessed at weeks months year years and years postoperatively by using the VAS score for back and leg pain the McNab index and SF

Results

Year clinical results on patients (% follow Up) were available for evaluation. According to the VAS Scale back pain improved from a total of to and leg pain from to % of the patients were very satisfied or satisfied with the outcome of the surgery. The quality of life score showed that % were satisfied with their current quality of life SF McNab also showed very good postoperative results. After years the long - term reoccurrence rate was %.

Conclusions

The clinical results after years with high radio frequency ablation during manual discectomy for herniated disc are encouraging.

Decompression coupled with Interspinous Process Device for Degenerative Lumbar Spinal Stenosis

Nino Mirnik

General Hospital Celje, Slovenia

Purpose

This study prospectively analyzed the success rates of DLSS patients treated with decompression and implantation of a soft IPD at one or two levels. We compared the results with a historic group of patients treated with traditional surgical decompression with or without PL fusion at one or two levels.

Methods

In the DIAM group outcomes were measured with the Zurich Claudication Questionnaire, Oswestry Disability Index (ODI) and the Short Form Health Survey (SF-36) completed preoperatively and at 1, 3, 6, and 12 months postoperatively. In the historic group outcomes were measured with the ZCQ preoperatively and at 1, 3, 6, and 12 months. The two groups were compared in ZCQ results preoperatively and at 1, 3, 6, and 12 months.

Results

The operating time was (\pm) minutes in the DIAM and (\pm) minutes in historic group. The blood loss was (\pm) ml in the DIAM and (\pm) ml in the historic group. The hospital stay was (\pm) days in the DIAM and (\pm) days in the historic group. The narcotic use was (\pm) days in the DIAM and (\pm) days in the historic group. In overall ZCQ results % () in the DIAM group and % () of the patients in the historic group were considered to be clinically successful. In the DIAM group the ODI and SF-36 results significantly improved on follow-up at 1, 3, 6, and 12 months and continued to improve to a 12-month observation period.

Conclusion

Overall the adjunct of a soft IPD to the interspinous decompression has not provided patients with better results in comparison to traditional surgical methods. The main advantages of interspinous decompression coupled with soft IPD implantation for DLSS are less operating time, less blood loss, and less narcotic use, which may make this surgical method potentially usable in older, debilitating patients.



FREE PAPERS
Friday

Enhanced Recovery After Surgery (ERAS) Protocol in Total Joint Arthroplasty

Tomaž Silvester, Eva Černe

General Hospital Jesenice, Slovenia

Introduction

As the general population is ageing there is growing number of total joint arthroplasty procedures for degenerative joint diseases. On the other hand the financial resources for healthcare budgets are limited or even shrinking. The ERAS protocol can decrease patients' in hospital length of stay (LOS) without compromising quality of treatment thus being beneficial for patients as well as for hospital budget. We investigated whether the goals of implementation of ERAS protocol were achieved at normal (general), not specialized orthopedic department in regional hospital.

Materials and Methods

All patients to whom primary total hip or knee arthroplasty was performed in year were included in this study. Patients were divided in two groups with regard to implementation of ERAS protocol in. Group there were patients operated on before implementation (patients) and in Group patients treated according to ERAS (patients). The analyzed outcome measures were in hospital LOS and readmissions in first days after discharge.

Results

A total of patients were included in the study of them went through "normal" clinical treatment whereas patients were treated according to enhanced recovery protocol. Both groups were comparable with regard to age gender and comorbidities distribution. Mean LOS in Group was days and was significantly shorter than in Group (days). On the other hand there were no significant differences in readmission rate in first days after operation.

Discussion

The enhanced recovery protocol was successfully and effectively implemented at our department with LOS significantly reduced without increased mortality. This was achieved with several multidisciplinary organizational changes before and during hospitalization with peri and postoperative optimization of blood management (regular use of tranexamic acid) and pain control (multimodal opioid sparing local infiltration analgesia), and especially with optimization in physiotherapy.

How to improve non original acetabular liner stability after revision surgery?

Ivan Bohacek, Tomislav Smoljanovic, Domagoj Delimar, Goran Bicanic

Department of Orthopaedic Surgery, University Hospital Centre Zagreb, University of Zagreb, School of Medicine, Croatia

Depending on well-defined radiological and clinical criteria, acetabular liner (AL) replacement in cementless hip endoprosthesis is frequently indicated and routinely performed. However, an important issue occurs when cementless acetabular component shows excellent stability and worn liner was discontinued in production during relatively long time span since the primary total hip arthroplasty (THA). Additional problem may occur when stable cementless acetabular component has diameter smaller than 48 mm and cemented polyethylene acetabular component cannot be implanted into cementless acetabular component because of its size, which exceeds such small diameter. The only solution in those cases is to implant cementless AL with layer of bone cement underneath. Here, we present two patients who underwent primary THA without any complications. After 19 years - Pt1 and 10 years - Pt2; AL became worn and replacement was indicated. Intraoperatively, in both patients acetabular components showed excellent stability, while original AL were discontinued in production. Since acetabular components were too small, use of cemented polyethylene acetabular component couldn't be cemented into cementless acetabular component. Therefore, cementless AL was used instead, with layer of cement underneath. In Pt2 1 year after, liner got detached from layer of cement, while in Pt1 liner became worn after 4 years, without signs of instability. Second liner replacement was performed in both patients, this time with roughening of the convex side of the cementless acetabular liner in order to prevent liner detachment and luxation. Currently, there are no complications present in those patients. According to our experience, we may conclude that in complex cases when original liner is not available and acetabular component is too small for cemented acetabulum to be implanted, cementless acetabular liner can be implanted with convex side roughened in order to provide adequate stability and prevent AL slippage and luxation.

Primary THR in cases of coxarthrosis with high luxation of the hip

Željko Jovičić

Institute of Orthopaedics, physical medicine and rehabilitation Dr. Miroslav Zotović, BiH

Introduction

Anatomic features of bones and soft tissues which are present in high luxation of the hip (HHL) require a different surgical logic when performing THR surgery. Anatomical changes are: insufficient muscles, shortened neurovascular fascicle, deformed femur, extended diaphysis, narrowed femoral canal, underdeveloped acetabulum.

Objectives

To show the possibilities of surgical treatment of coxarthrosis with HHL with primary total hip endoprosthesis. **Materials and methods:** Percent of HHL is 1,9% (3302/63). 49 patients had CHD and 14 patients developed luxation as a consequence of the postnatal septic osteoarthritis. An average discrepancy in leg length was 5,75 cm. Surgical technique includes surgical reposition of the luxated hip up to the equalization, restitution of the natural centre of hip rotation, subtrochanteric osteotomy and THR. We used cementless straight stem with distal fixation in 46 patients, cementless modular rounded stem in 16 patients and 1 cemented stem.

Results

For follow-up we used clinical tests, radiological and functional scores (HHS, Womac). The leg length equalization was achieved in 44 patients while shortening of 1 cm remained in 19 patients. Complications we encountered were longitudinal femur fractures, non-united femur osteotomy.

Conclusions

Early results in patients with HHL who were treated according to the described protocol confirm that the leg length equalization is possible. Results also prove that restitution of the anatomic centre of hip rotation is both the most decisive and the most predictive factor for good clinical and radiological result of the surgery. This surgical procedure is followed with more complications than standard primary THR.

Direct anterior approach

Tiago Pinheiro Torres; Daniel Saraiva, André Sarmento, André Costa, David Sá, Ricardo Santos Pereira, Miguel Frias, Sara Macedo, Rolando Freitas

Centro Hospitalar de Vila Nova de Gaia / Espinho, Portugal

The direct anterior approach is an alternative to conventional transmuscular approaches for performing total hip arthroplasty. We present a retrospective study evaluating the results of 60 total hip arthroplasties performed by direct anterior approach, divided into 40 primary hip arthrosis and 20 femoral neck fractures. The mean follow-up in the group of primary arthroses was 15.5 months (6-24 months) and in the group of neck fractures was 14.2 months (7-21 months). There was a significant improvement in the functional evaluation scores between the preoperative and the first postoperative month in the group of primary arthroses, with a slight improvement in the first postoperative month for 6 months postoperatively. In the group of fractures there was a clear improvement in the first postoperative month for 6 months postoperatively. This study confirms the direct anterior approach as a safe procedure for all patients, with precise placement of components and low complication rates. With this intermuscular approach, the patient must recover only for the surgical procedure, but not for the approach itself, which allows early recovery without restriction of movement or loading permission distinct benefit for directly focused outcomes in patients.

Modified lateral approach in dysplastic hip arthroplasty

Goran Bicanic, Ivan Bohacek, Ana Aljinovic, Domagoj Delimar

Department of Orthopaedic Surgery,
Clinical Hospital Centre Zagreb,
University of Zagreb, School of
Medicine, Croatia

Purpose

We present a modification of the direct lateral approach to the hip that provides excellent exposure to both, femur and acetabulum. Such approach allows adequate shortening of the proximal femur and further leg length equalization in dysplastic hip without necessity for trochanteric osteotomies, transverse cuts or detachment of abductor muscles.

Methods

Two groups of patients with dysplastic hips were compared: a) test group - Crowe 3 and 4 patients, which underwent THA using modified lateral approach; and b) control group - Crowe 1 and 2 patients which underwent THA using direct lateral approach. ROM, strength and balance board testing together with general functional assessment scores were examined before surgery and 6 months after surgery.

Results

ROM, strength and balance board testing were significantly improved postoperatively in both, test and control groups. There was no significant difference between the groups, except in some specific (combined) motions: reduced flexion and internal rotation in test group; and reduced extension, abduction, and external rotation in control group. General functional assessment scores demonstrated significant improvement after surgery in both groups, while there was no significant difference between the groups.

Conclusion

We may conclude that the use of modified lateral approach in patients with Crowe 3 and 4 dysplastic hips allows equal functional result compared to Crowe 1 and 2 patients that underwent same procedure with use of standard approach. Therefore, we recommend the use of modified lateral approach in patients with severe hip dysplasia undergoing THA.

Advantages of the modified cotyloplasty technique in dysplastic hip arthroplasty - results of 5 year follow up

Delimar Domagoj, Bohacek Ivan,
Barbaric Katarina, Aljinovic Ana, Bicanic Goran

Department of Orthopaedic Surgery,
Clinical Hospital Centre Zagreb,
University of Zagreb, School of
Medicine, Croatia

Purpose

Our modification of cotyloplasty technique consists of acetabular reaming up to the medial wall, subsequent controlled fracture of the medial wall and stabile acetabular component fixation with superolateral screws. Our technique does not require any grafting technique of the acetabular bottom.

Methods

We prospectively analyzed 21 THA in patients with hip dysplasia and insufficient bone stock at the level of the true acetabular roof. In all patients modified cotyloplasty technique was performed.

Results

Patient's average age at the time of surgery was 53.4 ± 10.3 years and average follow up was 5.7 ± 2.3 years. Average acetabular size was 48, acetabular angle was $41.3^\circ \pm 8.5^\circ$, acetabular anteversion was $17.5^\circ \pm 6.0^\circ$, cup medialization was 6.6 ± 2.9 mm in average. In average $46 \pm 20\%$ of the total acetabular surface was protruding in the pelvis. In 4 cases superolateral acetabulum was not completely covered with bone (lateral cup placement was 6.5 ± 3.7 mm in average). In one case (medialization of 9.6mm) primary instability occurred and cup was replaced with another cementless cup and generous spongioplasty of the acetabular bottom.

Conclusion

Cotyloplasty is used in cases of insufficient bone stock at the level of true acetabular roof. It removes necessity to use any augmentation of the acetabular roof. It seems that primary stability can be achieved with as low as 25% of contact area between the bone and acetabulum (since when even 77% of the acetabulum protrudes in the pelvis, good primary stability is achieved). Preserved medial lamina and periosteum heal and thus provide secondary (long lasting) cup stability.

First results after four years AMIS® surgery. A radiological follow up.

Matthias Leitner

Krankenhaus der Elisabethinen, Austria

In our hospital, EKH Klagenfurt Department for Orthopaedics, the anterior minimal invasive approach (Smith-Petersen) has been performed since 2008, the overall number is over 1000 and in late 2010 we started implanting a modified AMIS® stem. This work gives a radiological follow up (loosening and stress-shielding of the stem and the socket) depending on age at the date of implant, sex and Dorr type. Furthermore the rate of revisions is emphasized. This study includes patients from late 2010 till late 2011, up to 150. The standard Xrays are performed between three month, one and three to four years after surgery, beside clinical aspects in an ambulant standardised follow up program. matthias.leitner@ekh.at

Ceramic BIOLOX delta in Total Hip Replacement

Pavel Dufek

Schon Klinik Neustadt, Germany

Long term results of THR depend on the tribology of the contact bearing surfaces. The PE wear is the general problem of the hip arthroplasty. We report about our experience with the ceramic articulation in THR. Material: Since 2005 we use in the hip arthroplasty of biologic active patients till age of 70 years the ceramic-ceramic or ceramic-hcl PE articulation. In the period till 2012 we used the combination cer/ cer n: 2734, the combination hclPE/ cer n:1950- the combinations 36/36 and 32/32 mm. We measured the clinical results acc. Staffelstein Score in the time of discharge from the rehabilitation clinic, the number of dislocation prospectively. Results: The best clinical results achieved in the group cer/ cer kombination 36mm- the best range of motion, no dislocation. Complications: Squeaking 5x, malposition of ceramic insert 3x, breakage of the ceramic head 1x. Conclusion: Ceramic Biolox delta insert with combination of ceramic head 36 mm are very stabile, have better range of motion and the risk of long term wear is excluded.

Range of motion and muscle strength improvement using elastic resistance and kinesiotaping after operative treatment of the fractures in the elbow field.

Nikolova A., Benkin M., Baltov A., Rangger C.

Military Medical Academy, Sofia

Bulgaria

The posttraumatic contractures and muscle strength of the elbow complex represent a serious medico-social problem. The functional insufficiency leads to inability of independently performing of basic daily activities and sports. The elbow joint is the most complicated big joint. By 50% restrictions of the elbow function may result up to 80% difficulties of the upper limb movements. The post traumatic contractures are flexion-extension or combined. The extension is more frequently affected, and its recovery is more difficult. Main cases for decreased ROM and muscle strength are postoperative immobilization, pain and the increased muscle tones of m. biceps brachii and m. triceps brachii. Material and Method: The elastic resistance and kinesiotaping methods were applied to 20 patients with fractures of the elbow, of which 15 men and 5 women treated surgically in the Department of Orthopaedic, Traumatology and Reconstruction Surgery, Military Medical Academy, Sofia, and Nord-West Krankenhaus, Frankfurt in physiotherapy department. For evaluation of the functional results were used the following methods: Manual Muscle Testing, VAS for pain, goniometry. Specialized exercises with Elastic resistance and kinesiotaping were included in the physiotherapy program which started on 7th postoperative day. Results and Analysis: The analysis of the data from the last follow up demonstrated excellent functional results (statistically significant) in terms of muscle strength, range of motion and elbow complex. Conclusion: The specialized exercises with elastic resistance and kinesiotaping are integral part of modern methods of physiotherapy supporting the rapid functional recovery of the patients, due to its diversity, possibilities varying in the degrees of elastic traction and financial affordability.

Primary malignant tumors of the pelvis: about 8 cases

Fourat Farhat, Rafik Elafram, Rim Boussetta, Ismail Jerbi, Sami Bouchoucha, Walid Saied, Mohamed Nabil Nessib

Tunis children's hospital, Tunisia

Introduction

Primary malignant tumors of the pelvis in children are rare. They present a diagnostic problem and complex management. The purpose of this work is to analyze the medium-term results of surgery.

Method

This is a retrospective study of 8 patients a period from 1995 to 2012. Results: The mean age was 12 years. The diagnosis was made on average period of 3 months from the beginning of a non-specific symptoms. The diagnosis was suspected in radiology and confirmed by the histological examination. The staging included a CT scan, MRI and bone scintigraphy: 2 patients had lung metastasis. 5 patients underwent a protocol combining: resection-reconstruction and chemotherapy. One patient had a local recurrence.

Discussion

The management of primary tumors of the pelvis is complex because of the difficulty of early diagnosis, and surgical removal of the tumor. The surgery results in a disruption of the pelvic continuity.

Conclusion

Primary malignant tumors of the pelvis remains a complex issue as the delay in diagnosis and surgical resection. The difficult reconstruction showed good result but still delicate surgery with a prognosis worse than tumors of long bones.

Računarsko modeliranje nadlaktice i tumorske endoproteze zgloba ramena

Jovan Grujić

Grujić&Grujić, Serbia

Pojava malignih promena na proksimalnom delu nadlaktice (humerus) se hirurškom metodom može sanirati odstranjivanjem obolelog dela koštanog tkiva i nadomesti transplatom, koštanim graftom ili ugradnjom implantata, tumorske endoproteze zgloba ramena „custom made“. Na osnovu posmatranja malignih promena na koštano zglobnom sistemu čoveka učestanost ove promene na proksimalnom delu nadlaktice iznosi 15%. Primena tumorske endoproteze u rekonstrukciji proksimalnog dela nadlaktice omogućuje očuvanje gornjeg ekstremiteta i estetski i funkcionalno a pri tome omogućuje dovoljnu komfornost bolesniku u toku daljeg lečenja. Za korektno određivanje neophodnih geometrijskih parametara za dimenzionisanje koštane mase i nivoa resekcije nadlaktice a time i geometrijske parametre tumorske endoproteze, pored kliničkog pregleda neophodna je i logistika uređaja za medicinsku dijagnostiku uređaja za kompjuterizovanu dijagnostiku (CT i MRI). Tako se dobija niz digitalizovanih slika koji opisuju poprečne preseke kosti. Uz pomoć odgovarajućih softvera digitalizovani elementi slike pikseli se prevode u prostorne elemente voxele i formira računarski model kosti. Na osnovu geometrijskih parametara koštane mase određuju se geometrijski parametri računarskog modela tumorske endoproteze zgloba ramena, koji je pogodan za: simuliranje ugradnje, simuliranje biomehaničkih uslova prisutnih u zglobu ramena, brzu izradu prototipa, primenu CAD/CAM tehnologije pri izradi fizičkog modela endoproteze. Primena računarskog modeliranja kao i uređaja za kompjuterizovanu tomografiju omogućuje poboljšanje nivoa komunikacije između bolesnika i lekara. Obezbeđuje se dovoljna tačnost i skraćenje vremena izrade proteze. Time se smanjuje rizik od promene geometrijskih parametara usled napredovanja malignih promena

Direct 3D titanium alloy selective laser sintering made implant used for personalized pelvic reconstruction

Cengic Tomislav, Sabalic Srecko, Petrovic Tadija, Kodvanj Janos, Kolundzic Robert

University Hospital Centre Sestre milosrdnice Zagreb, Croatia

Introduction

Comprehensive portfolio of standard traumatology and orthopedic products in some case is not sufficient enough for a successful reconstruction. This is a case of 62 years old female patient, with the diagnosis of pelvic chondrosarcoma.

Method

The basis for specially designed implant was patient MSCT data based on which three-dimensional (3D) models were built. The final stage of the reconstruction process included creating of CAD (computer-aided design) model of the pelvis based on which we started with the process of implant design. After the model of the implant was designed, it was imported into the series of patient CT data in order to validate implant design. After the validation methods have shown that the design of the implant is in accordance with the requirements, biomechanical testing of the implant was made using finite element method (FEA).

Results

After the risk assessment process was completed the implant was released into the production using direct 3D titanium alloy selective laser sintering printing machine. Once the implant was printed, it was scanned using the 3D scanner and analysis of deviations compared to the default CAD model was done. The surgery was performed using standard T incision with preserving surrounding soft tissue. The tumor was extirpated including surrounding tissue and reconstruction was made with 3D printed implant and autologous bone. In one year follow up there were no signs of the disease. The patient has full weight bearing with support of one crutch.

Conclusion

The introduction of more complex surgical procedures requires an interdisciplinary approach and personalized implant design for successful reconstruction of bone defects.

Strategy and results in dwarfs lengthening

Daniele Pili

GVM Mangioni Hospital Lecco, Italy

Between 1982 and 2007, 128 patients with achondroplasia were treated. 100 of these were treated with sequential bilateral limb lengthening and seven with crossed lengthening. The average tibial lengthening was 14.1 centimeters (range: 6 to 19 cm.). The average femoral lengthening was 9.8 centimeters (range: 8 to 12 cm.), and the average humeral lengthening 8.3 centimeters (range: 8 to 12 cm.). The duration of treatment from initiation of lengthening to removal of the apparatus was 12.8 months in the tibia, 7.8 months in the femur, and 8.3 months in the humerus. The consolidation index (days per centimeters of lengthening) was 27.5 days in the tibiae, 23.8 days per centimeter in femora, and 30.6 per centimeter in the humeri. The average age at beginning of treatment was 13.5 years. The complications were classified as minor, moderate, and severe. Minor complications were those requiring only modification of the same external fixator. Twenty-three percent of the lengthenings required some modification of the frame during treatment. Moderate complications, 42%, were those requiring additional procedures. Finally, severe complications, 21%, were those requiring further surgery following the treatment or had lasting sequelae of the treatment. The most common complication was equinus contractures of the ankle which required treatment by Achilles tendon lengthening. Two patients developed pulmonary embolism following percutaneous Achilles tendon lengthening. One patient died as a result of this complication. Despite the significant complication rate, the handicap due to short stature suffered by patients with dwarfing conditions justify this treatment. All patients were satisfied. The appropriate motivation of the patient and skill of the surgeon are important factors to overcome the difficulties presented by these long and potentially risky procedures.

Mid-term results of treatment in children with OCD of the talus

Damjan Dimnjaković

KBC Zagreb, Croatia

Osteochondritis dissecans of the talus (OLT) is rare in child age, but is nevertheless seen in children with open physes. Unfortunately there are no guidelines of conservative or operative treatment in that age. The aim of this report is to show our mid-term results of arthroscopic bone marrow stimulation with microfracturing for treatment of OLT in children with open physes. Since 1999, in our Department, arthroscopic bone marrow stimulation with microfracturing has been the method of choice in treatment of patients with OLT. By searching the operation logs we identified all patients who were operated due to OLT from 1999 until 2013. From all of these patients we have identified children, guided by the age limit according to Karrholm (oldest age of 16 for boys and 15 for girls). During that period we operated 13 children (7 boys and 6 girls) with an average age of 14 (13-16) years at the time of the operation. Patients were evaluated by an independent examiner, who was not involved in the treatment process, using the AOFAS score and several subjective scores which are used for postoperative evaluation in patients with OLT. MRI of the operated ankle was also performed at the final follow-up. Average follow-up was 5,6 (3,8-13,6) years. The postoperative AOFAS score showed an improvement of an average 30 points compared to the preoperative results. The SF-36 score also showed good results, while SANE score showed excellent or good results in 11 patients and satisfactory results in two. Berndt and Harty score, as well as Martin score, were satisfactory or good in all patients. According to our mid-term results, it is clear that arthroscopic bone marrow stimulation with microfracturing is a successful method in treatment of OLT in children with open physes.

Management of proximal tibial osteoepiphyseolysis and patellar ligament avulsion with LCP plate

Slaven Simon, Antun Sumanovac,
Kresimir Majdancic

Vinkovci General Hospital, Department
of orthopaedic surgery, Croatia

Introduction

Osteoepiphyseolysis of proximal tibia associated with patellar ligament avulsion is a rare injury in adolescents. Such injury in both extremities is extremely rare.

Materials and methods

A 14-year old male athlete presented to our emergency ward with deformity of both legs following injury that occurred upon reception after jump. Ogden classification type IV (left extremity) and type V (right extremity) was confirmed using x-ray imaging. Physical examination did not show any neurovascular damage. After radiological and physical examination the patient underwent immediate surgery. Left extremity was managed with LCP plate and patellar ligament repair. Right extremity was also managed with LCP plate and patellar ligament reconstruction using anchor. Following surgery the patient underwent physical therapy.

Results

After one week we allowed full weight bearing on left extremity. After four weeks the patient walked normally without crutches.

Conclusion

Open reduction and internal fixation using meticulous surgical technique enabled fast recovery and excellent early results.



FREE PAPERS
Saturday

Tendoscopic treatment of posterior tibial tendon insufficiency

Damjan Dimnjaković

KBC Zagreb, Croatia

Posterior tibial tendon insufficiency (PTTI) is nowadays considered to be the main cause of adult-acquired flatfoot deformity (AAFD). Symptoms develop with time from nondisturbing swelling and occasional pain to hardly correctable deformations of the foot like collapse of the medial arch, hindfoot valgus and forefoot abduction. Depending on the stage of the disease, various modes of treatment are suggested, varying from nonoperative treatment like bracing to open surgery which includes diverse osteotomies of the hindfoot. We would therefore like to present our results for cases where tendoscopic treatment of PTTI was indicated. During the year 2014, twelve patients were diagnosed and treated for early stages of PTTI in our Department by performing tendoscopy of the tibialis posterior tendon (TP). We found isolated synovitis inside TP sheath in 6 patients, partial rupture of the tendon in 5 patients and a complete rupture of the tendon in a single patient. Tendoscopy as a solitary procedure was performed in 8 patients in which synovectomy and / or debridement of the ruptured tendon were performed. In the 4 remaining patients additional procedures were acquired, i.e. open tubularisation of the tendon in 2 patients, anterior ankle arthroscopy in one patient due to anteromedial ankle impingement and FDL transfer in another patient. At followup, results were good in 8 patients, satisfactory in 3 and unsatisfactory in a single patient with complete TP rupture. In this patient we performed additional procedure (FDL transfer) as a second stage surgery. Related with tendoscopic procedure, no complications were reported. Tendoscopy of TP is a useful and beneficial procedure when indicated at earlier stages of PTTI. It is a technically demanding procedure that requires extensive experience in arthroscopic management of small joints and excellent knowledge of regional anatomy.

The "peg" arthrodesis of the interphalangeal joints of toes

Andrej Prlja

General Hospital Jesenice, Slovenia

Introduction

The pin fixation of the interphalangeal joint arthrodesis of the toes was golden standard of the treatment of the static toe pathology. Loosening infection and poor compliance of the elderly patients are reasons for searching new ways of fixation. One possibility is the "peg" arthrodesis.

Materials and methods

Between September and November patients (male women feet), age range - years average were operated in this manner refused the procedure had " peg " only on toe on two and on three toes females were operated on both feet patients had previous correction of the hallux. On occasions " peg " was combined with other procedures on the toes. DIP joints were fused in patient PIP in male had posttraumatic deformation of the nd toe male had post infection nd toe deformation after the Homman procedure with pin fixation. All others had degenerative deformations patients had major cardiovascular disease diabetes hypertension hypercholesterolemia but none had complications during the procedure. All patients were treated on the outpatient basis all but two in local anaesthesia. Those two preferred general anaesthesia. The "frog mouth" skin incision was made over the contracted and painful joint the extensor tendon transversely cut and the joint opened. The "peg" was formed from the head of the proximal and "socket" in the basis of the distal phalanx of the involved joint. The "peg" was inserted into the "socket" and secured with the extensor tenodesis. Skin was closed with stitches X rays were made. The toe was bandaged with adjoining toes for weeks. Patients were instructed about the drappings mobilisation of the toes and burdening of the foot. Draping changes and suture removal were done by general practitioner. Follow up was from months to years.

Outcome of ankle arthrodesis with circular frames in post traumatic osteoarthritis.

Daniele Pili

GVM Mangioni Hospital Lecco, Italy

The main indication of ankle arthrodesis is pain due to post traumatic osteo arthritis. This is often accompanied with deformity, instability, infection and stiffness. The intent of the procedure is to obtain a plantigrade foot with a pain free ankle. Arthrodesis is achieved by resection of the articular surfaces, correction of the deformity and restoring the mechanical axis in the frontal and sagittal plane in order to obtain maximum residual functionality. In literature in quoted a very high rates of complications spanning through the different techniques among which is to be noted a 20% non-union rate. Re-operation rates for failed fusions have been quoted to range from 50% to 70%. We present in this paper our experience in the treatment of ankle arthrodesis using circular frames, describe the surgical technique and analyse the results of a of 37 patients, treated from (1982-2008). In this series 13 patients aged > 65 years with leg length discrepancy up to 2.5 cm we used a monofocal procedure (no osteotomy). In infected cases, we proceeded to a thorough resection of infected and necrotic bone in the tibia and talus, in order to remove the source of infection. The resection ranged from 4 to 16 cm. The bone loss was addressed with bone transport, the arthrodesis was achieved in the same procedure. The deployed technique in these cases was of a bi or trifocal (respectively one or two osteotomies). The arthrodesis was obtained with or without autologous bone grafting. In our series fusion was achieved in all but three patients (91.9 %) with the first procedure. In two cases we reapplied the external fixator eventually reaching bone healing, while in one case, no further surgical treatment due to severe diabetic kidney disease on dialysis was carried out.

Dual role of peroneal tendoscopy in the treatment of ankle disorders

Goran Bičanić

KBC Zagreb, Croatia

Aim

Endoscopy of the peroneal tendon sheath or peroneal tendoscopy, is a surgical technique that allows for visualization of peroneal tendons from the myotendinous junction to the peroneal tubercle. It provides dynamic evaluation of their movement inside the sheath, while preserving the anatomical soft structures involved in tendon physiology. According to the literature, peroneal tendoscopy is commonly presented as a solitary procedure. Based on our clinical experience, we would therefore like to add and emphasize the dual role that peroneal tendoscopy may have in the orthopaedic armamentarium.

Methods

Thirteen patients with clinically diagnosed peroneal tendons disorders were operated during the year 2013 in our hospital. All patients had additional radiological assessment performed. Peroneal tendoscopy was performed in a standard manner before any other arthroscopic or open procedure in all patients. Postoperative management was performed depending on specific type of pathology that was treated.

Results

In thirteen patients we found three peroneus brevis tendon partial tears, four cases of a low-lying peroneus brevis muscle belly, five cases of tenosynovitis and one intrasheath peroneal tendon subluxation. Peroneal tendoscopy was performed as an independent procedure in five patients, while in remaining eight it was performed as an accessory procedure - together with either anterior or posterior ankle arthroscopy, combined posterior and anterior ankle arthroscopy or open surgery. All patients were without any symptoms at one-year follow-up.

Conclusion

Intra- or extra-articular disorders of the ankle often require more than one operative procedure and peroneal tendoscopy should not be presented exclusively as an independent procedure. In addition, whether performed as a solitary or an accessory procedure, peroneal tendoscopy appeared to be a safe and successful surgical technique.

Hip Arthroscopy In The Treatment Of Femoroacetabular Impingement

Tiago Pinheiro Torres, André Costa, Daniel Saraiva, André Sarmento, David Sá, Francisco Costa Almeida, Filipe Lima Santos, Ricardo Pereira, Sara Macedo, Rolando Freitas

Centro Hospitalar de Vila Nova de Gaia / Espinho, Portugal

Introduction

The femoroacetabular conflict is recognized as a cause of hip pain in young patients . It occurs due to repetitive contact between the proximal femur and the acetabular rim usually in the presence of structural abnormalities of the hip . It probably represents the most common mechanism leading to early development of labral and chondral injury. Treatment leads to significant clinical improvements and may prevent the progression of these lesions Objectives: Revision of 42 patients who underwent hip arthroscopy due femoroacetabular conflict.

Methods

Patients were followed for 30 months. In the evaluation , the functional scores Non Arthritic Hip Score (NAHS) and Modified Harris Hip Score (MHHS) pre and post operatively were used .

Results

There was a positive clinical evolution of 73.75 NAHS (mean) having a pre -operatively and post -operatively and 92.5 MHHS 27 and 34 in the preoperative postoperatively . There was a favorable radiographic outcome with a centre edge angle of 35 and an alpha angle of 43 . Discussion : Conventional arthroscopic techniques can produce favorable results in pain relief and correction of deformity associated with femoroacetabular conflict. There is no data available in the literature demonstrating the results of conservative treatment in symptomatic patients . The successful intervention relies on early detection and correction of mechanical complete what can be achieved by arthroscopy.

Conclusion

Arthroscopy may be an effective method for treating deformity related to femoroacetabular impingement.

Doha Agreement meeting on terminology and definitions in groin pain in athletes

A. Weir, Z. Vuckovic et al.

Aspetar - Qatar Sports Medicine and Orthopaedic Hospital, Qatar

Background

A lack of agreement on groin pain terminology is a major obstacle to advances in the field, so experts in this field aimed to resolve this problem during the " Doha agreement meeting on terminology and definitions in groin pain in athletes" held in Aspetar in 2014. The results of this meeting and proposed treatment options are presented here.

Methods

Prior to the meeting all members of the group completed a questionnaire on the diagnosis of clinical cases. In total 17 different terms were used for the first case and 24 terms for the second. During the meeting the main focus was on long-standing groin pain and "groin pain in athletes" was the preferred umbrella term. Groin pain in athletes was divided into three major categories: 1. Defined clinical entities for groin pain: adductor, iliopsoas, inguinal and pubic-related groin pain, 2. Hip-related groin pain, and 3. Other causes of groin pain in athletes. The system is based on history and physical examination to categorize groin pain in athletes, making it simple and suitable for both clinical practice and research. The group discussed and chose not to use a number of terms that have been used previously, including terms used by several members of the group such as sports hernia and osetitis pubis.

Conclusion

The Doha Agreement Meeting on terminology and definitions in groin pain in athletes reached unanimous consensus on a clinically based taxonomy. Treatment options: All athletes should have standardized history and examination prior to treatment. First line treatment is an exercise based rehabilitation protocol for at least 4 weeks. In case of lack of progression or persistent symptoms we propose Muschaweck repair for inguinal - related groin pain, and adductor longus tenotomy for adductor - related groin pain.

Clinical comparison of the Quadriceps and the Hamstring Tendons for primary reconstruction of an isolated ACL tear: a matched pair analysis

Guido Wierer, Damjan Dimnjaković, Elmar Herbst, Caroline Hepperger, Hoser Christian, Peter Gföller, Christian Fink

Department of Traumatology and Sports Injuries, Paracelsus Medical University Salzburg, Austria

Introduction

The purpose of this study was to evaluate the clinical results after primary anterior cruciate ligament (ACL) reconstruction using either quadriceps or hamstring tendon autograft.

Methods

All patients who underwent primary ACL reconstruction between and were prospectively recorded in our register. Inclusion criteria for this study were an isolated ACL tear a minimal follow-up of months and a quadriceps or hamstring tendon autograft. Those patients who met these criteria were assigned to two groups according to the used graft (group quadriceps tendon group hamstring tendon). Patients from group and were matched by age In group a total of patients (women men) were available Hereby the quadriceps tendon was harvested with a standardized minimally invasive technique. For group a total of patients were included The IKDC (Knee Examination Form)-, Lysholm -, Tegner - and VAS - score were collected preoperatively and months postoperatively. In order to compare the matched samples the Wilcoxon - Signed - Rank - Test and t - test were applied ($p <$)

Results

Patients with a mean age of years (range - years) were matched At follow-up (months) there was no significant difference between both groups according to the scores. The mean Lysholm score was (range -) in group compared to (range -) in group. The mean Tegner score was (range -) compared to (range -). The VAS status for pain was (range -) compared to (range -). However the Lysholm score was significantly higher for group () than for group () months postoperatively ($p =$).

Conclusion

The quadriceps tendon graft shows comparable results to the hamstring tendon graft However patients treated.

Day case anterior cruciate ligament reconstruction: A study of 69 patients.

Srdjan Dojcinovic, Renaud Maes, Sladjan Marinkovic, Vladicin Han, Mirko Kovacevic

Clinique Générale, Switzerland

Daycase ACL reconstruction is commonly performed under general anaesthesia with a patella tendon graft. We report our experience with hamstring reconstruction under regional anaesthesia. Over a 12-month period, 69 daycase arthroscopic ACL reconstructions were performed by one surgeon and one anaesthetist. All operations were performed under spinal anaesthesia with a femoral nerve block. Patients were discharged with oral analgesia, and a cryocuff. 69 patients were prospectively evaluated with a IKDC chart. 95). IKDC score was 40% A, 50% B, 8%C, 2 %D. 100% patients were happy to be discharged on the same day. 1 patient was admitted from the daycase unit for infection. A second presented a rupture of ACL reconstruction. The mean visual analogue pain score was 1.0 at discharge, 1.8 in the middle of the first night, and 2.1 on the first post-op day. Patients experienced significantly more pain the day after surgery than the evening of surgery ($p=0.04$). We conclude that hamstring ACL reconstruction under regional anaesthesia is well tolerated by patients as a daycase procedure.



E-POSTER

Association of IL6 and TGFβ1 polymorphisms with developmental hip dysplasia (DDH): a case-control study in adults with severe osteoarthritis with and without DDH

Tomislav Čengić, Trkulja V, Pavelić SK, Ratkaj I, Markova-Car E, Mikolaučić M, Kolundžić R

Department of Traumatology,
University Hospital Centre Sestre
milosrdnice, Croatia

Introduction

Developmental dysplasia of the hip (DDH) is a congenital malformation that increases the risk of severe adult hip osteoarthritis (OA). Just like OA, DDH has a strong genetic component. Transforming growth factor-β1 (TGF-beta1) and interleukin-6 (IL-6) are two pro-inflammatory cytokines included in pathogenesis of OA. In this study we investigated the association of TGFβ1 and IL6 single nucleotide polymorphisms with DDH. Methods To test the hypothesis that the two polymorphisms are associated specifically with DDH, in the current case-control study 68 consecutive adult patients with secondary hip OA due to DDH (cases) and 152 consecutive adults with primary hip OA not related to DDH (controls) were genotyped at these loci.

Results

With adjustment for sex and genotype at the concurrent locus, cases were around 2.34 times more likely ($p=0.036$) to be transition homozygous at TGFβ1 locus 29 and around 7.80 times more likely ($p<0.001$) to be transversion homozygous at IL6 locus -572 than the controls. Cases were also 13.6 times more likely ($p<0.001$) than controls to carry one of the three genotypes combining transition/transversion homozygosity at both loci, or transition/transversion homozygosity at one and heterozygosity at the concurrent locus. Take home message These data suggest that TGFβ1 and IL6 might be valid DDH-susceptibility genes and indicate a possibility of TGF-beta1 and IL-6 interaction in DDH pathogenesis.

“Same Day” ex vivo regional gene therapy: The optimization of the human skeletal muscle transduction with recombinant adenoviral vectors

Eduard Rod

Sv. Katarina, Croatia

Introduction

The conventional, two step approach, ex vivo gene therapy is expensive and time consuming procedure. Successful clinical applications needs ex vivo gene therapy protocol in which all procedure would be performed in operating theatre during surgical procedure.

Aim

To optimize the transduction of grafts of human skeletal muscle with a recombinant adenoviral vector constructed to carry the luciferase reporter gene (Ad.Luc 2) in vitro. Adenoviral vector expressing osteogenic inducer BMP-2 (Bone Morphogenetic Protein) will be used to evaluate the effectiveness of the developed protocol.

Material and methods

The ideal concentration of adenoviral particles, transduction time and influence of lanthanum chloride and/or calcium chloride on improvement of transduction was determined by luciferase report assay and the BCA protein assay. AdBMP-2 was used to evaluate the effectiveness of developed protocol. Quantitative PCR was done on day 0, 7 and 14 to confirm the expression of DMP1 (dental matrix protein) and BSP (bone sialoprotein). Results: The ideal concentration of adenoviral particles for transduction of human muscle graft was 10^9 PFU/mL. The optimal time of contact between human skeletal muscle graft and adenovirus concentration 10^9 PFU/mL was 30 minutes. There was no statistically significant difference between pure viral titer applied and supplemented viral titer applied to the muscle grafts. Effectiveness of the developed protocol was evaluated with comparing relative mRNA expression of BSP and DMP1 on day 0, day 7 and day 14 for adenoviral vector expressing osteogenic inducer BMP-2 (Bone Morphogenetic Protein) and osteogenic induction medium.

Conclusion

This research, we have optimized protocol for in vitro transduction of grafts of human skeletal muscle with a recombinant adenoviral vectors.

The amount of hydroxyapatite within the scaffold affects bone formation

Lidija Pribolšan

Faculty of Science Zagreb, Croatia

The amount of hydroxyapatite within the scaffold affects bone formation Lidija Pribolšan, Anamarija Rogina, Igor Matic, Andreja Vukasovic, Inga Marijanovic, Hrvoje Ivankovic and Alan Ivkovic Regenerative orthopedics seeks to establish a successful protocol for the healing of severe bone damage. The existing methods have a number of disadvantages and the goal of tissue engineering strategies is to develop a new scaffold that is biocompatible, biodegradable, non-immunogenic and has osteoinductive properties. For that purpose, we propose a new model of bone graft engineering using human mesenchymal stem cells (hMSCs) as a cell source, composite scaffold based on chitosan and hydroxyapatite (HA) and osteogenic media in combination with the perfusion force as a osteoinductive environment. The main aim of this study was to compare the influence of the amount of hydroxyapatite (HA) within the scaffolds on osteogenic differentiation of hMSCs in a U-CUP perfusion bioreactor (Cellec Biotek). We used and compared scaffolds with 0% HA, 10%, HA 30% and 50% HA. Bone grafts were analyzed after 14 and 21 days by histology and qPCR. Bone graft analysis after 14 and 21 days of culture showed that cells and connective tissue are present within the graft. qPCR analysis of bone markers, bone sialoprotein (BSP), dentin matrix protein 1 (DMP1) and osteocalcin (OC), confirmed osteogenic differentiation of cells within the bone graft. We conclude that composite scaffold made of chitosan and 30% HA resulted in homogenous cell attachment and new tissue formation with the highest expression of osteogenic markers.

Isolated Microorganisms from Allograft Femoral Head and Bone Chip Samples

Krešimir Crnogača, Goran Bicanic, Domagoj Delimar

1. University of Zagreb School of Medicine Clinical Hospital Centre Zagreb Department of Orthopaedic Surgery, Zagreb Croatia

Femoral heads as allografts are routinely obtained from living donors during total hip arthroplasty (THA) and are a valuable source of bone grafts in everyday orthopaedic surgery. However, all these allografts need to be assessed for bioburden before transplantation. Aim of this study is to identify the most common microorganisms responsible for allograft contamination. Records of femoral head and bone chip banking between 2011 – 2013 were reviewed retrospectively. A total of 215 living donors, 115 females and 100 males (mean age 60.2 years; range 25-83 years), donated 200 femoral heads and 205 bone chips. They were all harvested during THA for primary or secondary osteoarthritis. Tissue samples of femoral heads and bone chips were separately obtained for bacterial and fungal bioburden testing. Microbiological growth was obtained from 24% of femoral heads and 11.7% of bone chips. We discarded 61 femoral heads and 55 bone chips. Fifty-seven femoral heads and 53 bone chips were discarded because of microbiological contamination and 4 femoral heads and 2 bone chips were discarded because of technical issues. The predominant microorganisms isolated were skin commensals like coagulase-negative Staphylococci found in 45 tissue samples followed by *Corynebacterium* species and *Bacillus* species in 6, and *Streptococcus viridans* in 4 tissue samples. Other microorganisms were only sporadically encountered. Isolated skin commensals and the fact that less than 1% of the femoral and bone chip donors eventually develop periprosthetic hip joint infection showed that contamination during handling, obtaining tissue samples and packaging rather than precedent local infection or transient bacteriemia is the main cause of allograft contamination. Decontamination methods could be applied during bone processing and could potentially decrease the contamination of the final bone products, but cost/effectiveness analysis should be performed first.

Bioreactor-engineered cartilage graft for osteochondral knee lesion – study in sheep

Andreja Vukasovic, Petar Kostesic, Maja Pusic, Drazen Maticic, Damir Hudetz, Davor Jezek, Marko Pecina, Alan Ivkovic

University of Zagreb, School of Medicine

The aim of this study was to apply bioreactor engineered tissue graft for the treatment of osteochondral defects in sheep stifle joint, thus enabling cartilage and subchondral bone restoration. 8 sheep were assigned to 4 treatment groups. All sheep underwent two surgical procedures. During the first procedure, chondral defects 4 mm in diameter were created on the weight bearing surfaces of both condyles of the right femur. After six weeks, all chondral defects were converted to osteochondral defects 6 mm in diameter and 5 mm deep. In groups NC (n=2) and AC (n=2) autologous three-dimensional osteochondral grafts engineered in perfusion bioreactor from bilayered scaffolds and nasal septum chondrocytes or articular chondrocytes respectively were implanted in the defect. In the CFS group (n=2) only bilayered scaffolds were implanted while CTR group (n=2) underwent defect conversion only (negative control). Three months after treatment surgery, all sheep were sacrificed and tissue blocks were obtained for histology analysis. The samples were fixed in 4% buffered paraformaldehyde and decalcified in 15% EDTA. Paraffin blocks were sectioned at 5 µm and stained with hematoxylin-eosin, safranin O and picosirius Red. Immunohistochemistry was performed against collagen type I, II and aggrecan. Histology was evaluated with ICRS II histological score. Overall results showed that cartilage restoration was the best in NC group. Matrix staining, ICRS II parameter, scored superiorly in NC group ($p < 0.05$). The research leading to these results has received funding from the European Union's Seventh Framework Programme (FP7/2007-2013) under grant agreement n°278807.

3D model visualization and analysis using Finite Element Method and 3D printing in medicine

Petra Bonačić Bartolin

Polytechnic of Zagreb, Croatia

The power of advanced medicine is one of the great stories of modern science, built on a long succession of discoveries and technological breakthroughs. Medicine development lies in technology development. Modern manufacturing of medical supplies and medical diagnostics today can not be imagined without the use of modern tools such as computer programs for 3D modeling (SolidWorks, Pro/Engineer), simulation (Abaqus, Ansys), animation and devices for Rapid Prototyping (3D printer). This paper presents a simplified model of intravertebral artificial disc Charite, which is modeled in SolidWorks software package. The model is discretized tetrahedral finite element mesh of the second order, and the simulations were performed for four different loads in Abaqus. Using 3D printing, which is the base of 3D modeling, such a type of implants and prostheses will be produced in a very short time with a much lower costs, which will bring revolution and medical advances.

Cytokine expression in synovial membrane of sheep knee treated with tissue engineered osteochondral graft

Maja Pusic 1, Andreja Vukasovic 1, Petar Kostesic 2, Drazen Maticic 2, Damir Hudetz 3, Davor Jezek 1, Marko Pecina 4, Alan Ivkovic 3, 5

1 University of Zagreb, School of Medicine, 2 University of Zagreb, Faculty of Veterinary Medicine, 3 University Hospital Sveti Duh, Department of Orthopaedics, Zagreb, 4 University of Zagreb, School of Medicine, Zagreb 5 University of Rijeka, Department of Biotechnology, Croatia

The aim of this study was to apply bioreactor engineered tissue graft for the treatment of osteochondral defects in sheep, thus enabling cartilage restoration, and examine tissue reactivity to this type of treatment. 8 sheep were assigned to 4 treatment groups. All sheep underwent two surgical procedures. During the first procedure, chondral defects 4 mm in diameter were created on the weight bearing surfaces of both condyles of the right femur. After six weeks, all chondral defects were converted to osteochondral defects 6 mm in diameter and 5 mm deep. In groups NC (n=2) and AC (n=2) autologous three-dimensional osteochondral grafts engineered in perfusion bioreactor from scaffolds with nasal septum and articular chondrocytes respectively were implanted in the defect. In the CFS group (n=2) only scaffolds were implanted while CTR group (n=2) underwent defect conversion only (negative control). 6 weeks after treatment surgery, all sheep were sacrificed and tissue blocks were obtained for histology analysis. The samples were fixed in 4% buffered paraformaldehyde and decalcified in 15% EDTA. Paraffin blocks were sectioned at 5 µm and stained with hematoxylin-eosin and against TNF- α . The amount of TNF- α , IL-1 β and IL-6 mRNA expressed in synovial membrane of treated and contralateral knees was measured with qRT-PCR. Results showed moderate expression of all three cytokines with no significant difference among groups. The research leading to these results has received funding from the European Union's Seventh Framework Programme (FP7/2007-2013) under grant agreement n°278807.

The Fellowship examination of European Board of Orthopaedics and Traumatology (EBOT)

Andrej Radić

Sv. Katarina, Croatia

For Youth day Since 2001 when was established by the board of all European Union National Orthopaedic Societies (section of the Union Europeenne des Medecins Specialistes), EBOT exam was held annually in different European cities. Since the knowledge of orthopedic surgeons in the EU is rather unequal, EBOT exam will be final qualification that would guarantee that all fellow members of the board have uniform knowledge. It also means that it would be safe to practice orthopaedics anywhere in Europe. Every year, more applicants are encouraged to take this exam and get this prestigious qualification, which surely can help in progress of their careers. In the future, EBOT Exam will also aim to address not only knowledge, but also skills. The EBOT Exam is a prestigious qualification that is a valuable addition to every orthopaedic surgeon CV! EBOT exam consists of written and oral examination. The written section is completed online and consists of 100 multiple choice questions (MCQs) in the single correct answer format [SCA] during 3 hours. It is held in the different examination centers in Europe usually in June. The oral examination consists of five sessions of 30 minutes each, two examiners 15 min each. It is organized in one major European city usually in October. Number of participants for written exam is not limited but for oral exam is restricted to 80. After successfully completing EBOT exam candidate gets title: Fellow of the European Board of Orthopaedics and Traumatology (FEBOT). After oral presentation at SEEFORT Youth day, a questionnaire will be distributed with questions about interest for possible Comprehensive Review Course (CRC) that can be organized in the future.

The use of vacuum in reinfusion drain systems can increase postoperative blood loss after total hip replacement surgery

Matevž Topolovec, Simon Kovač

Ortopedska bolnišnica Valdoitra,
Slovenia

In elective surgery, such as knee and hip arthroplasty, most orthopedic surgeons routinely insert drains for draining wounds. Now days, postoperative autologous blood reinfusion systems represent an alternative to homologous, banked blood transfusions. The purpose of our prospective study was to determine the role of vacuum in reinfusion drain systems in hip arthroplasty patients. In both groups we used reinfusion drainage system Ortho PAS. In one group we used a vacuum (40 cm H₂O), in the other group we did not use any vacuum. We found that the use of vacuum drainage significantly affect the amount of blood loss during the first 4 hours in total hip arthroplasty.

Upper Limb Infections In Diabetic Patients

FM Effendi, MI Ibrahim¹, ZMZ Zukiz

¹University of Technology MARA,
Sungai Buloh, Malaysia

²Hospital Sungai Buloh, Sungai Buloh,
Malaysia

Aim

Patients with Diabetes Mellitus have an increased risk of infection due to immunopathy and it carries a significant morbidity if it involves the hands. This study is to investigate the clinical characteristics and surgical outcomes of upper limb infections in patients with Diabetes Mellitus.

Method

One year retrospective review of patient with diabetes admitted to our orthopaedic ward for upper limb infections requiring intravenous antibiotics and/or surgical intervention.

Results / Discussion

Twenty one patient fits the inclusion criteria of whom majority are woman (71%) with average age of 50 years old. More than quarter (29%) out of them were newly diagnosed diabetes. Patient with established diabetes had average duration of 5.5 years after initial diagnosis. The average Glycosilated Hemoglobin (HbA1C) level was 11%. On average, patient had onset of symptoms of 10 days before presenting to the hospital. Upon presentation, only one patient (5%) had fever with majority (67%) of site affected involving the hands. For patients requiring operative intervention, the average waiting time was 2.2 days and average hospital stay was 8.8 days. Three patients required radical intervention i.e amputation or disarticulation due to uncontrolled infection and delayed presentation. Culture studies did not yield any causative organism in 31% of patients.

Conclusion

Serious morbidity of the upper limbs can be caused by unawareness and delayed presentation of infections involving upper limbs in diabetic patients. This study further highlight the importance of good glycemic control and patient education regarding the condition.

Dorsal closing wedge calcaneal osteotomy for the treatment of insertional achilles pathology. 5 years follow up.

Dimitris Georgiannos

**424 Military general hospital-
Thessaloniki, Greece**

Purpose

Aim of this study is to prospectively evaluate the efficacy of the dorsal closing wedge calcaneal osteotomy in athletes with chronic insertional Achilles pathology after failure of the conservative management.

Methods

Between 2007-2010, 64 dorsal wedge calcaneal osteotomies were performed in 52 athletes diagnosed with insertional Achilles pathology treated conservatively but unsuccessfully for 6 months. A lateral approach was used and the osteotomy was fixed with 2 staples. AOFAS and VISA-A scores were used preop and 1year postop. Results: Average age was 35y (range 19-52y). All patients were followed-up for a mean 5 years. AOFAS score was improved from 58points preop to 92points postop ($p < 0.05$) and the VISA-A score from 67p to 94p ($p < 0.05$). Clinical results were considered as excellent in 83% of the cases, good in 14% and fair in 3%. Complications included wound problems (5), recurrent retrocalcaneal bursitis (2) and nonunion of the osteotomy in one case which treated with bone grafting and revision of fixation.

Conclusion

Dorsal wedge calcaneal osteotomy is a safe and efficient method for the treatment of chronic insertional Achilles tendinopathy after failure of conservative management in athletes. It is dramatically improves symptoms and allows athletes to return to their previous sport activities.

Treatment of osteochondral lesions of talus with osteochondral transplantation of autologous graft. 5 year follow up.

Dimitris Georgiannos

**424 Military general hospital-
Thessaloniki, Greece**

Purpose

Bone marrow stimulation procedures (microfractures/drilling) are considered the gold standard for the primary treatment of osteochondral talar lesions. In the literature, there is lack of evidence about the appropriate treatment in cases of failure of these procedures. A technique of osteochondral autologous transplantation of talar graft was used. It was hypothesized that this is a successful method with good results and low complication rates.

Methods

Between 2004 and 2007, 46 patients (37 males, 9 females), with OLT for which arthroscopic treatment with curettage and drilling or microfracture had failed, underwent osteochondral transplantation with an osteochondral graft harvested from the ipsilateral talar articular facet. A medial malleolar osteotomy or a distal tibial wedge osteotomy was used to access the talar dome defect. RESULTS: The median follow-up time was 5.5 years (range 52-75 m). 34 lesions were located in the central talar dome in the coronal plane, while 26 and 19 lesions were located in the lateral and medial aspect of talar dome in saggital plane, respectively. The overall improvement between the preoperative and post-operative AOFAS and VAS FA score was 35 points ($p < 0.001$) and 39 points ($p < 0.001$), respectively. Clinical results were considered as good in 43 patients (93.4 %) and fair in three patients (6.5 %). No complications occurred at the site of the malleolus osteotomy or tibial osteotomy and the donor site at the talus.

Conclusions

The midterm results suggest that the technique of osteochondral transplantation of autologous talar graft for osteochondral lesions of talus after failure of primary treatment with bone marrow stimulation can be safely and successfully used. It demonstrates excellent post-operative scores including improvement of pain and function and does not yield complications experienced with other procedures.

Proximal opening wedge metatarsal osteotomy for the treatment of moderate to severe hallux valgus deformity.

Dimitris Georgiannos

424 Military general hospital-
Thessaloniki, Greece

Purpose

Hallux valgus is a complex deformity of the first metatarsophalangeal joint, with varus angulation of the first metatarsal, valgus deviation of the great toe and lateral displacement of the sesamoids and the extensor tendons. The aim of the surgery is to achieve correction of the varus deviation of the 1st metatarsal which is considered by some as the primary intrinsic predisposing factor to hallux valgus deformity.

Methods

We retrospectively reviewed 85 patients (107 feet) who underwent an opening wedge osteotomy of the 1st metatarsal for correction of moderate to severe hallux valgus and metatarsus primus varus. A medially applied anatomic pre-contoured locking plate was used for fixation of the osteotomy. RESULTS: The mean IMA was decreased from 15.8 (range 12-22) degrees to 7.8 (range 0-12) degrees. The mean pre-operative HVA was 39 (range 21-52) degrees and the mean postoperative HVA was 11.8 (6-19) degrees. The pre-operative AOFAS score was 52 (SD 3.1) and the postoperative score was 85 (SD 5.2).

Conclusion

The proximal opening wedge metatarsal osteotomy is a safe, effective and reproducible technique for correction of moderate to severe hallux valgus deformity. The use of a locking plate provides enough control at the fragments, enhancing healing of osteotomy and maintenance of the correction even with a violated proximal lateral cortex.

Dysfunctional 1st MTP joint fusion converted to interposition arthroplasty in relatively young unsatisfied patients. 3 years follow up

Dimitris Georgiannos

424 Military general hospital-
Thessaloniki, Greece

Aim

Arthrodesis of the 1st MTP joint for the treatment of osteoarthritis is a safe method with low complication rate. Patient dissatisfaction with mobility difficulties is rare complication difficult to treat. The aim of this study is to evaluate the conversion of dysfunctional 1st MTP joint fusion to interposition arthroplasty and to report our results in 6 cases with 3 years follow up.

Methods

6 patients who were unsatisfied and complaining of mobility difficulties after 1st MTP joint fusion for OA, were treated surgically with conversion of the fusion to interposition arthroplasty. Fascia latta allograft was used and interposed in the excised 1st MTP joint space. Results: At a minimum follow up of 3 years the patients' AOFAS score was improved at a mean of 24 (13-38) points due to improvement of function and pain. Satisfied with the outcome and were willing to consider the procedure again. The mean postoperative ROM before subluxation of the allograft was 63° of dorsiflexion and 21° of plantarflexion which was considered excellent by all patients. No complications were encountered.

Discussion

Converting dysfunctional 1st MTP joint fusion to interposition arthroplasty could be considered a safe alternative solution with promising results in selected cases especially in relatively young population.

Neuropathic Arthropathy of the Knee secondary to Familial Amyloid Polyneuropathy

Zico das Neves

Centro Hospitalar Tondela Viseu, Portugal

Arthrodesis is a fallback option to obtain a stable and painless knee when joint damage is not subject to reconstruction. The main indications for knee arthrodesis are arthroplasty failure, malignancy, post-traumatic osteoarthritis, irreparable injury to the extensor apparatus, chronic infection and neuropathic arthropathy. This work aims to show the clinical case of a patient with Familial Amyloid Polyneuropathy, which started unilateral knee pain with progressive worsening and with in less than a year of evolution, culminated in knee arthrodesis. A 47 years-old female, with Familial Amyloid Polyneuropathy, obese, hypertensive, transplanted liver and under immunosuppression, referred for outpatient orthopedics for left knee pain of sudden onset and not associated with trauma. Imaging study conducted and therapeutic procedures as viscosupplementation and arthroscopy. Having regard to unfavorable clinical course was held arthrodesis with a locked, long intramedullary nail, entering in the piriformis fossa with autologous bone graft. Arthrodesis of the left knee in 10° of valgus and 15° of flexum with good clinical evolution and radiological signs of progress toward fusion, walking with support of crutches. Diffuse pain complaints, without neurovascular or soft tissue injury. Gradually resumed activities of daily living. Faced with a patient with neuropathic arthropathy of the knee secondary to Familial Amyloid Polyneuropathy, highly disabling and with such fast evolution, this option allowed the definitive treatment in a single surgical procedure without complications. This option for arthrodesis allows better mobility in the postoperative period (without external mechanisms), early loading and a success rate that is up to 95%. The treatment options for a neuropathic neuropathy are reduction of activities, orthoses and in advanced cases immobilization with arthrodesis, arthroplasty is contraindicated. With this method, the treatment was possible in a single surgical procedure without complications and gradual return to activities of daily living.

Ellis Van Creveld Syndrome Bilateral Genu Valgus Correction

Zico das Neves

Centro Hospitalar Tondela Viseu, Portugal

Ellis Van Creveld syndrome (EVCS) or chondroectodermal dysplasia is an autosomal recessive disease extremely rare and that results from mutation of EVC and EVC2 genes. It is characterized by cardiac malformations polydactyly ectodermal dysplasia and chondrodysplasia of long bones. We present a case of bilateral genu valgum EVCS surgically corrected with femur and tibia osteotomies.

Material

We present the case of a year - old caucasian female referred to the outpatient by persistent bilateral knee pain and lower limb deformity which conditioned gait limitation. At physical examination she has low height (cm), chest tightening bradidactylia tooth and nail hypoplasia alopecia and bilateral genu valgus. History of cardiac surgery (congenital heart disease - atrioventricular communication) and correction of polydactyly C

Methods

The patient underwent correction of bilateral genu valgum the left in May and the right in December. The procedure was a distal femur. Coventry osteotomy and tibial external addition with bone autograft D Results – Good clinical course without knee pain improved gait pattern standardization of functional mechanical axis of the lower limbs osteotomy consolidation and patient satisfaction E

Discussion

The diagnosis of EVCS is essentially clinical From an orthopedic point of view it is necessary to correct the genu valgum condition because it leads to early osteoarthritis. The combined osteotomies (tibiofemoral) are indicated for severe deformities in which the simple proximal or distal osteotomy to the joint would be insufficient. Genu valgum is common in children (physiological). However in some cases such as EVCS the deformity correction is needed. Among the different options osteotomies are probably the most common method for correction of angular deformities In this case a high level of satisfaction was achieved both aesthetically and clinically and an.

ACL revision surgery Case report

João Morais, Tiago Rebelo, Zico Gonçalves, José António Gomes, Francisco Agostinho, Manuel Sousa

Centro Hospitalar Tondela Viseu, Portugal

Introduction

The reconstruction of the anterior cruciate ligament (ACL) is a common procedure held by most orthopedic surgeons. This procedure provides high success rates. However, despite the development of surgical techniques, failure rates are shown ranging from 3 to 15%, according to the literature. Failures occur most often due to technical errors, and may also be associated with repetitive injuries, concomitant injuries, among other causes.

Material

We present the case of a 38 years old patient, with a total rupture of right ACL in 2006, and at the time was reconstructed with bone-tendon-bone technique. Referred to outpatient orthopedics by instability and pain at the right knee, with positive Lachman test. The patient was operated in February 2013. It was observed by arthroscopy: ligament rupture, femoral tunnel with too posterior position and fracture of the internal meniscus. Carried out ACL repair with hamstrings tendons and internal partial meniscectomy. Results: The patient fulfilled rehabilitation program in the postoperative period, subject to a month and a half after surgery, walks without support, claudication, joint effusion, instability or changes to the active and passive mobilization of the knee.

Discussion

Of all the possible causes of failure, technical errors are the most common, accounting for 77% to 95% of cases of ACL ligament failure. The most common error with respect to the non-anatomical positioning of the tunnels, being the position of the origin of the femoral tunnel in most cases. The femoral tunnel is positioned too anterior often resulting in loosening of the graft in flexion and extension.

Conclusion

ACL ligament review is a challenge for the surgeon, is associated with worse outcomes than primary reconstruction. Performing a ACL ligament revision requires a preoperative planning to identify the cause of failure and avoid repeating the same mistakes in revision surgery.

Ankle Pigmented Villonodular Synovitis Arthroscopic Resection

Tiago Rebelo, Frederico Paiva, Nuno Simões, Zico Gonçalves, Francisco Agostinho, Eduardo Mendes, Manuel Sousa

Centro Hospitalar Tondela Viseu, Portugal

Introduction

Pigmented villonodular synovitis (PVNS) is a rare proliferative disorder of the synovium, which affects young and middle-aged adults. This condition may be locally destructive and involve the muscles, tendons, bursa, skin and bones. The incidence of SNVP in the ankle joint is approximately 2.5%. Patients are frequently presented with pain, swelling and joint effusion.

Material and Methods

Female patient 45 years old with pain, swelling and joint effusion of the right ankle with 4 weeks of development unrelated to trauma. Underwent ankle arthroscopy, which verified the presence of synovial lesion and an osteochondral lesion of the talus. Excision of synovial injury was done and the injured cartilage of the talus removed and microfractures were performed. Results: The patient started full weight bearing at 8 weeks after arthroscopy without new episodes of pain or hemarthrosis. Presents total ankle mobility, having resumed work without restrictions. At last follow-up visit 1 year after diagnosis and treatment, has no imaging evidence of local recurrence.

Discussion

Magnetic resonance imaging is a useful non-invasive means of diagnosis based on hypodense, diffuse infiltrative lesion involving soft tissue structures in T1 and T2. The ideal treatment of PVNS is surgical excision. A complete synovectomy is the preferred treatment for PVNS. The incomplete removal likely results in recurrence of the lesion. Its recurrence rate is up to 46%. Moderate dose external radiotherapy can improve the probability of local control in recurrence cases. Take Home Message A combination of clinical, radiological and histological correlation is needed for the diagnosis of PVNS. Treatment consists of complete synovectomy and the recurrence rates are high.

Overuse syndrome of foot in school aged children and the use of orthopaedic insoles

Tadija Petrović

KBC "Sestre milosrdnice", Croatia

We analyzed the use of orthopedic insoles based on a sample of 250 school-aged children (age 7-16 years) due to foot pain induced by sports and other physical activities. Most patients (84%) complained of pain due to sports activities. Pain was most frequently associated with basketball (34.7%) and least frequently with volleyball and martial arts (2.4%). Most children used orthopedic insoles whole day (58%). The mean level of pain at the first examination was 4.4±1.37. At the control examination 82% of patients reported having no pain, while in the remaining 18% of patients the level of pain reduced to 1.7±0.87. Most children rated their orthopedic insoles with "very satisfied", while the lowest rating they gave in their evaluation was "neutral". The use of orthopedic insoles is extremely important in treatment of foot pain, whether it was induced by flexible flat feet, overuse foot syndrome and/or some other conditions.

Intraoperative gamma hand held probe navigation in resection of osteoid osteoma tumor report of two cases

Tomislav Čengić, Čorluka S., Petrović T., Baranović S., Kovačić K., Kolundžić R.

KBC "Sestre milosrdnice", Croatia

Introduction

We would like to present two cases with osteoid osteoma tumor (OO), and report our early experience of intraoperative gamma probing to localize OO at surgery. The concept of radioguided surgery was developed 60 years ago and the application of gamma detection probe technology for radioguided biopsy and/or resection of bone lesions dated from the early 80s. Bone scintigraphy is very important for initial diagnosis of OO with almost 100% sensitivity. The bone scan finding is specific – so called double density appearance; very intense accumulation of radiopharmaceutical in nidus and therefore great difference between the nidus and surrounding healthy bone, which made possible to treat this lesion with probe guided surgery.

Method

Three phase bone scintigraphy and SPECT (single photon emission computed tomography) was conducted in our patients for initial diagnosis of OO. A second bone scintigraphy was performed before surgery. The surgery followed 12 – 15 hours later by intraoperative nidus detection with hand-held gamma probe. Gamma hand-held probe is system that detects gamma photons. The count rate in the nidus area at the day of surgery was 3 to 4 times higher than the healthy bone area. The drilling was performed until the counts decreased to the level of the counts of surrounding bone, thereby confirming complete excision. Take home message This is the method of choice because of minimizing bone resection, the risk of pathological fracture, need for bone grafting and because of shortening the period of reconvalescence. Evidence of the treatment efficiency is the pain disappearance after surgery.

Knee stability after arthroscopic anterior cruciate ligament reconstruction using the middle third of the patellar ligament and quadrupled hamstring tendons grafts a two year follow up

Wertheimer Vjekoslav, Zelić Zoran, Saša Rapan, Egon Biuk, Boris Žulj

**Department of orthopaedics
University clinical hospital center
Osijek**

Knee stability after surgical anterior cruciate ligament (ACL) reconstruction using quadrupled hamstring tendons graft (gracilis and semitendinosus) and the middle third of the patellar ligament was compared. All subjects participating in this study had ACL rupture diagnosed by clinical examination and MRI and underwent identical surgical procedure apart from the choice of graft. Total of 112 patients with either patellar ligament or quadrupled hamstring tendons graft were evaluated during 24 months after the surgery. Patients were similar according to age, sex, activity level, knee instability level and rehabilitation programme. Clinical tests and a measuring instrument KT-1000 arthrometer were used to evaluate the knee stability after the reconstruction. During the 24-month study there were no significant differences in clinical stability of the knee and the use of both grafts resulted in satisfactory knee stability. The difference between the groups according to the graft was noticed 6 months after the reconstruction when the results obtained by a measuring instrument showed that knee stability was significantly higher in patellar ligament graft (Fisher's exact test).

Autologous spongioplasty and cell free scaffold assisted femur lateral condyle stage IV avascular necrosis repair

Eduard Rod

Sv. Katarina, Croatia

Background and purpose

The subchondral bone and the calcified cartilage are continuous and are crucial supportive structures involved in load transmission. Understanding of interactions between articular cartilage and subchondral bone continues to evolve. Treatment options for stage IV avascular necrosis of femoral condyle depend on the extent and location of the osteonecrotic area, patient age, and level of activity. One of the surgery options for such advanced cases is bone grafting and one step call free scaffold assisted cartilage repair.

Materials end methods

A 35-year-old female patient underwent arthroscopic surgery of the knee for a stage IV AVN of the lateral femoral condyle. Clinical outcome scores and knee MR were recorded pre-operatively, after 6 weeks and after 6, 10 months postoperatively. At 3 months after implantation of a cell-free type I collagen matrix, the patient was again treated arthroscopically for a contracture of same knee. After diagnostic arthroscopy the cell-free scaffold size 25x20x6 mm (CaReS-1S®, Arthro-Kinetics, Austria) was implanted according to the manufacturer's recommendation. The underlying subchondral bones defect was prepared and fulfilled with autologous spongioplasty. The postoperative rehabilitation program was carried out according to a standard protocol.

Results and conclusion

The patient is satisfied with the results of the operation and is able to carry out everyday activities. The clinical results were favourable and an improvement in function and a decrease in pain were evident from preoperative values. On knee MR 10 months postoperatively the previous chondral defect showed good implant integration, no dislocation and just mild signs of inflammation. One step cells free scaffold based procedures for cartilage repair simplify and further improve regenerative techniques. The resorbable scaffold builds up a nature 3D environment which optimises cell migration and ingrowths.

Saphenus nerve block and sciatic nerve block in the perioperative pain management for arthroscopic anterior cruciate ligament reconstruction

Ira Skok

Sv. Katarina, Croatia

One of the most often arthroscopic procedure in orthopaedic surgery is anterior cruciate ligament reconstruction and for sure one of the most painful. Most of those patients are young and healthy and are expecting rapid recovery and early mobilization. To optimize pain control in the perioperative period is quite challenging in such patients. We tried to provide an optimal pain control with focus on procedural anatomy, by blocking two relevant nerves with low dose of local anesthetic. We follow up 100 patients ASA I underwent arthroscopic anterior cruciate ligament reconstruction. Ethical committee approval was obtained. First group of 50 patients (group A) got preoperative blockade (ultrasound-guided) of saphenus and sciatic nerve with the same dose of local anesthetic mixture: 0.375% levobupivacaine with 4 mg dexamethasone and unilateral spinal anesthesia. Second group (group B) just got unilateral spinal anesthesia which was an usual technique for this procedure in our Clinic. After the surgery group B received intravenously Tramadol and metamizole for postoperative analgesia. Intraoperative and postoperative pain control was measured using visual analog scale (VAS), postoperative nausea, iv. fluid intake, early mobilization and patient satisfaction was also measured. Intraoperative VAS was similar in both groups. Postoperative VAS was lower in A group compared to group B. Early mobilization was found to be worse in group B as well as nausea and patient satisfaction scores. Greater iv. fluid intake was found in group B, while group A could take fluid orally as well as food. The use of peripheral nerve blocks in orthopedic surgery should be a mainstay of perioperative pain control. We propose this technique and dosage for such procedures.

Medical School Never Covered This: Why Patients Do And Don't Choose A Surgeon Why Patients Do And Don't Choose A Surgeon

Isabella Guajardo

University of California San Francisco, USA

Background

Needing orthopedic surgery is a stressful and scary time for a patient. It is no surprise, then, that patients shop around to find the right surgeon.

Methods

But what do they want? A survey was administered to a random cross-section of American adults to find out. Z-tests and Pearson's r correlations were analyzed.

Results

Among many other intriguing findings: Prospective patients rated the importance of 24 factors on a 1 to 10 Likert-type scale. Eleven factors averaged above an 8 ($p < .0001$). Besides being board certified and experienced, patients strongly want a surgeon with whom they feel rapport. The data showed that one of the most powerful methods for creating rapport is for the surgeon to promise to "fight for" the patient to the patient's insurance company. Other critical factors involved trusted referral sources, competent staff, and being able to make appointments within a month. The most trusted referrals come from primary care providers (selected by 30%) and family and friends (24%). If their primary care provider recommended a surgeon, patients were unlikely to choose a different surgeon ($p < .05$). Other factors were unimportant to prospective patients.

Conclusions

This data helps clarify what information surgeons should emphasize and what is irrelevant.

Osteosclerotic bone phenotype is stably imprinted in subchondral mesenchymal stromal cells in hip and knee osteoarthritis

Daniel Bianco Adames

University Hospital Basel, Switzerland

Purpose: Subchondral bone sclerosis in OA is characterized by an increase of bone material that is hypomineralized, caused by a dysregulated osteoblast phenotype. This increased bone anabolism suggests the involvement of mesenchymal stromal cell (MSC) recruitment and their differentiation into osteoblasts. In this study, we investigated whether the properties of these osteoprogenitors have changed in nonsclerotic and sclerotic OA subchondral bone.

Methods: Knee tibial plateaus and femoral heads were obtained from patients undergoing total knee and hip arthroplasty. Subchondral bone tissues from nonsclerotic and sclerotic regions were digested and nucleated bone marrow cells were isolated. Osteogenic (CFU-O) and total number of colonies (CFU-f) were counted after alkaline phosphatase (ALP) and methylene blue staining, respectively. Confluent cultures were subjected to osteogenic differentiation for three weeks and evaluated using ALP staining, quantitative ALP assays and qualitative analysis of mineralization by Alizarin Red staining. Results: CFU-f counts, was $20.1 \pm 2.2\%$ in nonsclerotic and $17.0 \pm 3.5\%$ in the sclerotic subchondral tissue, without statistical differences between regions. Osteogenic potential of MSCs from knee joints was very high without significant differences between nonsclerotic ($91.8 \pm 1.6\%$) and sclerotic ($91.6 \pm 3.4\%$) tissues. Significant statistical differences were also absent for the hip comparing nonsclerotic ($69.8 \pm 5.6\%$) and sclerotic ($56.0 \pm 19.1\%$) tissues; but their osteogenic potential was significantly reduced ($p < 0.05$) when compared with the knee. Osteogenic differentiation was efficient demonstrating a 5.4- and 4.2-fold increase of ALP activity in nonsclerotic and sclerotic MSCs, respectively. Five out of six donors had significant differences in ALP activity between nonsclerotic and sclerotic MSCs. In vitro mineralization was absent in nonsclerotic MSCs. Sclerotic MSCs demonstrated strong mineralization only in one donor.

Conclusions: Our findings suggest that MSCs derived from OA subchondral tissues adopt an aberrant osteoblastic phenotype upon osteogenic induction. Differential ALP activity and hypomineralization, characteristics of OA subchondral bone sclerosis, appear stably imprinted in tissue-resident osteoprogenitors.

Proximal Femoral Nailing vs Dynamic Hip Screw in Intertrochanteric Fracture in elderly people.

Neritan Myderrizi

Service of Orthopaedy and Trauma.
Regional Hospital Durres, Albania

Background

The aim of this study was to compare the results of proximal femoral nail (PFN) and dynamic hip screw (DHS) in treatment of intertrochanteric fractures.

Material/Methods

63 patients were treated by a dynamic hip screw and proximal femoral nail in Service of Trauma in Regional Hospital Durres during 2012-2014. Fractures were classified under AO. Patients were operated under X ray intensifier control. Functional outcome, duration of operation, blood loss, rate of union, amount of collapse were studied and statistically evaluated for both of groups.

Results

The average age of our patient is 77.3 (57-95) years. 15/48 male/female. Fractures were classified under AO, 23.8% A1, 58.7% A2 dhe 17.5% A3. The average operating time for the patients treated with PFN was 49.3 min as compared to 72.3 min in patients treated with DHS. The average of intraoperative blood loss was 85.4 and 122.2 ml in PFN and DHS group, respectively. The patients treated with PFN had better Harris Hip Score in the early period (at 1 and 3 months) and earlier ambulation, but in the long term (at 6 and 12 months) both the implants had the same functional outcomes.

Conclusions

The current evidence indicates that PFN may be a better choice than DHS in the treatment of intertrochanteric fractures.

Solitary exostosis of the foot and ankle

Rafik Elafram, Mourad Zarea, Rabhi Safouane, Jerbi Ismail, Dridi Moez, Annabi Hedi, Hadj Salah Mehdi, Mbarek Mondher

Burn and traumatology centre of Ben Arous, Tunisia

Purpose

Osteochondroma represents the most common benign bone tumor and occurs most frequently in the proximal humerus, tibia, and distal femur. The bones of the foot and ankle, by comparison, are less commonly involved. We tried to describe the epidemiological, clinical particularities of this tumor and its prognosis.

Methods

A retrospective study of 11 patients (06 males and 05 females, mean age 23 years 15 to 38 years). There are 07 osteochondroma in the ankle (04 in the fibula and 03 in the tibia). 04 osteochondroma of the foot: 02 in the metatarsal, 01 in the third toe and 01 in the calcaneus. Results: The diagnosis delay was 05 years (04 months to 18 years). The mean diameter in the ankle was 2.8 cm and in the foot was 1.5 cm. We reported 05 cases of traumatism. The X-rays were usual in 09 cases. All our patients had surgical removal of the osteochondroma and histological study. No case of recurrence was reported.

Conclusion

Surely we present a heterogeneous study, we tried to make a profile of this rare localization of the osteochondroma in order to better deal with this entity.

Ewing's sarcoma of the foot and ankle: limb salvation Vs limb amputation

Rafik Elafram, Mourad Zarea, Jerbi Ismail, Rebhi Safouane, Annabi Hedi, Hadj Salah Mehdi, Mbarek Mondher

Burn and traumatology centre of Ben Arous, Tunisia

Purpose

Ewing's sarcoma (ES) of the foot and ankle is a rare condition whose treatment is controversial. There are no large series covering this issue. Some authors advise amputation as the "gold standard" treatment. We report 04 cases of Ewing sarcoma. The authors report 03 cases of amputation and 01 case of limb salvation. Methods: Our study is about 04 cases: 02 occurs in the fibula, 01 in the third metatarsal and 01 in the navicular. The mean age was 22 years (18 to 28 years) 02 females and 02 males. The mean delay was 10 years (06 to 12 years).

Results

The mean diagnosis delay was 01 year (06 months to 14 months). The diameter was 04 to 05 cm in the ankle and 03 to 05 cm in the foot. All the patients presented pain and swelling. All the patients had X-rays, CT scan and MRI. They have shown images that helped the diagnosis. All the patients had biopsies that confirmed the diagnosis. In all the cases, the patients had preoperative chemotherapy. 03 patients (01 with the ankle localization and 02 in the foot) had amputation. In 01 case we opted for surgical extirpation of the tumor and tibiotalar arthrodesis. We don't report any case of recurrence.

Conclusion

Chemotherapy and resection with reconstruction of the foot yielded excellent results in ES cases. Survivorship of ES in distal locations seems to be better than for proximal ones. Even in many cases amputation is a solution. We can try to save the limb as often as possible.

Juxta-cortical chondroma of the foot and ankle

Rafik Elafram, Mourad Zaraa, Jerbi Ismail, Rebhi Safouane, Annabi Hedi, Hadj Salah Mehdi, x Mbarek Mondher

Burn and traumatology centre of Ben Arous, Tunisia

Purpose

Juxta-cortical chondroma is a benign, slow-growing cartilaginous tumor that typically occurs at the metaphysis of long tubular bones beneath the periosteal membrane. It is a rare localisation in the foot and ankle. By this work, we tried to study the characteristics of the juxta-cortical chondroma.

Methods

We report 03 cases of juxta-cortical chondroma, 02 occurring in the foot and 01 case in the distal tibia. The mean age was 20 years (15 to 27 years). 02 males and 01 female.

Results

The size of the chondroma in the foot was between 1.5 and 03 cm, in the ankle it was 05 cm. There were no history of traumatism. All the patients were operated and have surgical removal of the tumor. A histological study was performed confirming the diagnosis of periosteal chondroma. With a delay of 07 years, there were no recurrence.

Conclusion

Periosteal chondroma represents a distinctive benign cartilage tumor, apparently originating in the periosteum. It is a rare lesion, particularly in the foot and the ankle. The treatment is a surgical extirpation and an anapathological study.

Our experience of achilles tendon repair, absorbable vs non-absorbable suture repair

Muhammad N Baig

Kerry general hospital, Ireland

Background

We retrospectively studied our Achilles tendon acute rupture cases done over past 2 years and reviewed the outcome and complications.

Methods

We studied 57 consecutive patients who came to our hospital with acute Achilles rupture. We did open end to end repair. We retrospectively collected their bio-data, medical history and mode of treatment. We followed them over up to 6 months with regards to outcome and complications using boydens score.

Results

Out of 57, 4 were treated conservatively because of their medical co-morbidities, age and functional requirements. 53 were operated using ethibond, ethibond and pds or only pds. About 6 surgical infections of the operative site and 3 complications over longer period came as thickening and stiffness. Conclusion- We came with this outcome that in majority of patients the functional outcome results were good to excellent. We observed that a particular technique of repair was related to infection rate as all of them who got infection were repaired using non-absorbable ethibond. We also observed that DVT prophylaxis should be regularly given to the patients.

Arthroscopic Meniscus Repair

Marko Labaš, Ana Magdalenić, Jasenko Mandić, Boris Lukić, Stanislav Mlakar

Department of Orthopaedics and Traumatology General Hospital Varaždin

Injuries of the meniscus are one of the most common injuries in knee joint. Development of arthroscopic technique and also better understanding of osteoarthritis mechanisms have shown the important role of meniscus in prevention of secondary osteoarthritis. Meniscus is a connective - cartilagenous tissue. In cross-section it is wedge - shaped. It is divided in three zones red zone is vascularized zone, red - white zone is the transitional one and white zone is the inner avascular part of meniscus which gets its nurture by diffusion. Meniscal laesion is a result of trauma or degeneration. It can be isolated or combined with other injuries of the knee joint (e. g .ACL rupture). Indications for meniscus suturing are age (<40), time elapsed from injury (< 3months), laesion characteristics (longitudinal laesion in red or red - white zone" bucket handle tear ") and also associated injuries (ACL rupture). There are three basic suturing techniques, outside - in, inside - out and all-inside. For successful repair fine surgical technique and knowledge of all three techniques is required. In Department of Orthopaedics and Traumatology at The General Hospital Varaždin from March to April there were 248 arthroscopic procedures of the knee. In 15 patients were performed arthroscopic meniscal repairs by suturing (14 male, 1 female patient). Thirteen of these were medial meniscus laesions, two were lateral meniscus laesions Also five of these cases were associated injuries of ACL and thus ACL reconstruction and meniscus suturing were done at the same time. Outside-in and all-inside (OMNISPAN) techniques were used. On average, patients were monitored for six months afterwards. As a complication we had four rerupture. Two of them with rerupture of lateral meniscus and two with medial meniscus rerupture.

Our experiences with knee tumor megaendoprosthesis and total femur reconstructions

Šimić Marijana, Jurina Petra, Đinkić Maja, Ribičić Tomislav, Kolundžić Robert

Children's Hospital Zagreb, Clinic of Traumatology, University Hospital Centre "Sestre Milosrdnice" Zagreb

Introduction

Functional reconstruction following large tumor resections are challenging especially in growing children and require experienced orthopedic surgeon. The aim of this work is to show our experiences with large metal allografts replacing lower extremity long bones in pediatric and adult patients.

Materials and methods

In period between 2009 and 2015 we operated 11 patients with malignant bone tumors, aged from 9 to 68. Seven of them were younger than 25. In 4 cases the bone deficit was made up by total femur and knee tumor endoprosthesis (Johnson&Johnson or Stryker), and in 7 cases by knee tumor megaendoprosthesis.

Results

Pediatric patients had leg length discrepancy 3 to 9 centimeters. Two patients underwent reoperation because of trauma caused periprosthetic fracture, which occurred about 5 years after primary reconstruction. One patient still has Proteus caused infection problem and one died two years later as a consequence of a tumor disease.

Discussion

Tumor knee alloarthroplasty and total femur replacement are good reconstructive solutions in limb salvage procedures, especially in conditions of human bone allograft deficit although are burdened with complications such as infections, bone fractures and implant breakage. Mechanical complications occur more frequently in active children and young adults, representing additional problem to solve.

Tibial plateau fractures - Epidemiology and its surgical management in a Grade I Trauma Center

Miguel Frias, Rafael Portela Silva, Ricardo Santos Pereira, Tiago Pinheiro Torres, André Sarmento

Centro Hospitalar de Vila Nova de Gaia Espinho, Portugal

The tibial plateau fractures account for 2% of all fractures, with this percentage increasing in the elderly population. Epidemiological studies are essential tools for understanding their occurrence. The most widely used classification was introduced by Schatzker and divides it into 6 types. Its primary treatment is crucial in the prevention of late complications. Each fracture pattern leads to different types of surgical treatment. In this study 92 cases of tibial plateau fractures surgically treated in a grade I trauma center were retrospectively analyzed from January 2009 to December 2013. Were taken into account the gender, age, type of trauma and associated injuries, fractures classification, type of surgical used and its complications. Functional assessment was evaluated according to the Knee Society Score. We analyzed 34 women and 58 men with an average age of 49 years, being the leading cause of injury road traffic accidents with the left knee being the most affected. The most and the least type of fracture seen were respectively types II and IV. Open reduction and internal fixation with plate, screws and graft placement was the most used. Complications were recorded in 4% of patients, and 2 of them required a total knee arthroplasty. Functionally, 84% had good to excellent results, and the vast majority returned to daily and sport activities prior to the occurrence of the injury. As the knee is one of the main load-bearing joint, timely and appropriate surgical treatment of fractures of the tibial plateau plays a key role in the restoration of the articular surface and prevention of late complications, preventing the progression to post-traumatic arthrosis and promoting reestablishment of a normal joint function.

Chromosome abnormalities in parosteal osteosarcoma and differential diagnosis

Abdülkadir Bilgiç, Dilek Gün Bilgiç, Yunus Demirtaş, Hasan Acar, Özdamar Fuad Öken, Ahmet Özgür Yıldırım, Ahmet Uçaner

Ankara Numune Training and Research Hospital

Parosteal osteosarcoma is a slow growing tumor usually revealed by the appearance of a painless mass. It is the most frequent form of low - grade osteosarcoma and represents 4 % of all osteosarcomas. The prognosis varies depending on the risk of local recurrence after inadequate resection and dedifferentiation. Its diagnosis sometimes can be confused with fibrous dysplasia. In the literature there is not enough information about low - grade osteosarcoma genetics. Previous studies demonstrated changes in cytogenetics and molecular genetics in parosteal osteosarcoma involving marker chromosomes which contain amplification of the 12q13-15 region including CDK4 and MDM2 genes. Two studies demonstrated that by coupling of immunohistochemical stains for CDK4 and MDM2 for at least marker was amplified in 87% to 100% cases of parosteal and low - grade central osteosarcoma while other benign mimickers were rarely positive representing a valuable tool in differential diagnosis. A 34 year-old female patient was admitted with painful solid mass in her right knee for 2 years. In her physical examination there was a 15x10 cm in size solid irregular mass. Radiological examination revealed a contrast enhancing lesion on distal diaphyseal-metaphyseal segment level that destructing the bone cortex and containing intramedullary and extraosseous components consistent with osteosarcoma. Histopathological examination of the lesion in two different centers revealed fibrous dysplasia. Due to the inconsistent the clinical and radiological findings with histopathological findings we performed FISH analysis with centromere 12 probe and found presence of extra chromosome 12. We performed biopsy again Histopathological examination revealed grade 1 parosteal osteosarcoma in two different centers. Than we performed wide excision and tumor resection arthroplasty. Low grade osteosarcoma can be misdiagnosed as benign lesions like fibrous dysplasia. It is important to distinguish it from mimicking lesions because of their different treatment modalities.

Endoscopic Calcaneoplasty in the treatment of Haglund's disease

Ricardo Santos Pereira, Tiago Pinheiro Torres, Miguel Frias, Daniel Saraiva, José Campos Lemos, Andre Sarmento

Centro Hospitalar de Vila Nova de Gaia Espinho, Portugal

Haglund's disease, also referred to as "pumpbump," is defined as the complex of symptoms involving the presence of an enlarged posterolateral border of the calcaneus, retrocalcaneal bursitis, and superficial Achilles tendon bursitis. After failure of the conservative treatment, operative treatment - surgical bursectomy and resection of the calcaneal exostosis - is indicated by many authors. Open surgical procedures are effective but a relatively high incidence of complications has been described - skin breakdown, painful or non-cosmetic scars, infection, avulsion of the Achilles tendon, or persistent pain due to inadequate bone resection. Recently, several authors have reported good results and less morbidity with an endoscopic technique through posterior portals for the treatment of patients with a calcaneal exostosis. We aim to present our technique and results with endoscopic calcaneoplasty in 8 patients (9 ankles). Follow-up ranged from 5 to 18 months (mean 10.2). All patients showed clinical improvement - There were two good and seven excellent results measured by the Ogilvie-Harris score and the mean preoperative AOFAS score improved from 52.6 in the pre-operative period to 88.2 at final follow-up. One patient complained of paresthesias in the sural nerve territory that spontaneously resolved by the first post-operative month. There were no other intra- or postoperative complications. Even though further comparative studies are necessary, endoscopic calcaneoplasty appears to be a good alternative to open resection for the treatment of Haglund's disease. It is safe, minimally invasive and allows a fast functional recovery.

Modified inside-out to all in meniscus repair technique for treatment of longitudinal tear of lateral meniscus in popliteal hiatus: a case report for treatment of longitudinal tear of lateral meniscus in popliteal hiatus_ a case report

Starcevic Damir, Trsek Denis, Tabak Tomislav, Haspl Miroslav

Special Hospital for Orthopaedic Surgery "Akromion"

Introduction: It is well known that injury of lateral meniscus significantly alters the load transmission pattern across the knee, resulting in higher contact stresses, decreased contact area, and an increase in the contact pressure and shear forces across the articular surfaces. All that changes can lead to accelerated cartilage wear and osteoarthritic changes. Lateral meniscus tears in area of popliteal hiatus are not suitable for repair with inside-out and outside-in technique, because sutures cannot be placed onto joint capsule or on to popliteal tendon. For that reason we modified inside-out technique.

Aim: The aim of this study is to present modified technique for repair of longitudinal tear of lateral meniscus in popliteal hiatus. Methods Eighteen year old male football player underwent arthroscopic repair for isolated lateral meniscus tear. We used modular cannula to reach desired place on lateral meniscus in region of popliteal hiatus. Two long needles loaded with nonabsorbable suture were pushed through cannula, meniscus, beside popliteal tendon, and through joint capsule and skin. Both suture ends were found between meniscus and capsule, and brought back in to that joint and pulled out of the joint through anterolateral arthroscopic portal. Suture was secured inside of the joint, behind the base of meniscus with sliding arthroscopic knot, using the knot pusher, thus leaving lateral meniscus mobile.

Results: After arthroscopic repair patient worn adjustable knee brace for 6 weeks with full weight bearing. Postoperative Lysholm score was 95 after postoperative rehabilitation, Tegner activity score was 7, same as before operation, and patient returned to playing football.

Conclusion: Rapid deterioration of the lateral compartment after meniscal injury and/or meniscectomy suggest that repair of lateral meniscus should be done whenever possible. This technique is effective and economic procedure that can help us preserve important function of lateral meniscus.

Treatment of Pantrochanteric Hip Fractures in Elderly Patients: Internal Fixation Using Proximal Femoral Nail or Bipolar Hemiarthroplasty

Hongman Cho

Busan veterans hospital, Republic of Korea

Purpose

To perform comparative analysis between the results of internal fixation using proximal femoral nail system and bipolar hemiarthroplasty in pantrochanteric hip fracture in elderly patients.

Materials and Methods

From January 2006 to February 2012, we reviewed 43 patients, who were treated surgically for pantrochanteric hip fractures, with a minimum of 2 years follow up. The patient's age was older than 70 year old. The patients were divided into three groups and evaluated, retrospectively. The fracture reduction were regarded as satisfactory in S-OR-IF group(17 cases) and unsatisfactory in US-OR-IF group(9 cases) and the other group was treated with bipolar hemiarthroplasty (BHA group, 17 cases.)

Results

At 24 months post-operation, S-OR-IF group had higher Harris scores, less pain, and better walking ability than S-OR-IF and BHA group. Six patients in the internal fixation group (one with S-OR-IF and five with US-OR-IF) had got reoperation.

Conclusion

For pantrochanteric fractures of old-aged patient over 70 years old, bipolar hemiarthroplasty has few of severe complications which needs reoperation. However, satisfactory reduction and internal fixation makes better clinical results in long term follow-up.

Snapping Shoulder Clinical case

Zico Gonçalves, João Moreno Morais, Tiago Rebelo, Francisco Agostinho, Manuel Sousa

Centro Hospitalar Tondela Viseu, Portugal

Shoulder microinstabilities are a group of disorders with multifactorial etiology, which may be divided according to their traumatic or atraumatic origin. These are a diagnostic and therapeutic challenge, because they often occur with normal physical examination and diagnostic tests. A 22 year-old caucasian male, bodybuilder. Is admitted to our hospital with complaints compatible with snapping shoulder, and the feeling of instability in the limits of external rotation in abduction, particularly when associated with load. Physical examination shows limitation in external rotation, with positive apprehension test for anterior instability. The patient underwent arthroscopy of the shoulder and we have indentified a fragment of cartilage from the posterior border of the glenoid, a posterior labrum injury with pedicle intraarticular fragments, as well as a detachment of lambrum. The fragment was excised and the anterior labrum was fixed with two anchors. The patient was discharged on the same day, and started or active mobilization of the shoulder, unloaded for a 4 week period. He was seen periodically in consultation with resolution of initial symptoms soon after surgery. After the initial discharge, he resumed training with progressively increasing load. At 3 months after surgery he is asymptomatic, without any limitation. This type of pathology has an initial presentation difficult to characterize, and often, can only be better defined after careful arthroscopic evaluation. In this case, the authors admit that the injury has been traumatic, associated with the load exerted on the limits of the shoulder mobility during intensive practice of bodybuilding. The arthroscopy allows the identification and treatment of lesions that would otherwise be difficult or impossible to identify and treat. The advantages of the arthroscopic technique is also associated with the reduced morbidity and a short recovery period.

Klippel Feil Syndrome Diagnosis in Adulthood

Tiago Rebelo

Centro Hospitalar Tondela Viseu,
Portugal

Introduction

Klippel-Feil Syndrome (KFS) is a rare genetic disorder, first described in 1912 by Maurice Klippel and Andre Feil. Its main feature is the fusion of two or more cervical vertebrae due to anomalies in segmentation between the 3 to 8 weeks of embryonic development. The KFS translates into complex visceral and bone changes including the classic triad of short neck, decreased neck movements and low-set hair.

Material and Methods

We report the case of a patient of 49 years-old female, referred to outpatient orthopedics for chronic cervical pain with recent deterioration and irradiating to the left arm. There is a history of congenital deafness and mild mental retardation. We performed clinical history, physical examination and musculoskeletal imaging studies.

Results

Physical examination reveals the presence of the classic triad of KFS, short neck, little neck mobility and low-set hair. It is also possible to observe facial asymmetry. Imaging study showed spinal fusion C2 - C3 and C6-C7.

Discussion

KFS occurs in 1 of 42,000 births, approximately 60% of patients are female. There are described three types of KFS : Type I (40%) : complete cervical fusion ; Type II (45%) : fusion of 1 or 2 vertebral interspaces ; usually C2 - C3 or C5-C6 ; Type III (12 %) cervical fusion and low thoracic or lumbar fusion . Other clinical changes KFS are dorsal kyphosis , facial asymmetry, deafness, lower line of the nipples, cardiac anomalies , Sprengel deficiency , respiratory disorders , gastrointestinal disorders , among others. Take Home Message The main feature in KFS is cervical spinal fusion. The diagnosis is clinical, usually carried out in childhood due to the typical physical characteristics.

Latarjet: 9year follow up of 123 cases

Benjamin Marjanovič

Ortopedska bolnišnica Valdoltra,
Slovenia

In our study group we used modified open (Congruent - Arc) technique in patients (shoulders), males and females average age of years for anterior glenohumeral instability between January and January All shoulders had some osseous deficiency of the anterior glenoid rim or had at the same time relaxation after previous arthroscopic surgery The results of all hundred - twenty - three shoulders were reviewed Six shoulders (%) redislocated after repeated trauma due to epileptic seizures (two) or hypoglycemia (two) in one diabetic patient Two patients had repeated sports trauma shoulders (%) were subjectively graded as excellent or good Dissatisfaction was associated with persistent subluxations (%), persistent pain and inability to compete in sports at the pre - injury level The mean Rowe score was (range -). The overall short - term complication rate was % . We divided complications into four groups intraoperative infection recurrent instability and neurologic injury Intraoperatively there was a fracture of the coracoid process during fixation in one shoulder (%); additional resorbable anchors were used to stabilize coracoid fixation A superficial (above deltopectoral split) infection developed in one shoulder (%); the infection was successfully treated with debridement and antibiotics Two shoulders (%) developed recurrent glenohumeral subluxation these shoulders were treated with arthroscopic capsuloplasty and or remplissage One procedure (%) resulted in transient motor neurapraxia of musculocutaneous nerve which persisted for two months Modified open Latarjet procedure is safe and effective surgical technique for restoring glenohumeral stability Indication for surgery should be limited in drug - resistant epilepsy.

Subscapularis arthroscopic repair

Tiago Pinheiro Torres; Andr Sarmento;
Pedro Louren o, Andr Costa, Daniel
Saraiwa, Jos MArinhas, Miguel Frias,
Ricardo Pereira, Sara Macedo, Rolando
Freitas

Centro Hospitalar de Vila Nova de Gaia
Espinho, Portugal

Objectives

The aim of this work was to evaluate the results of arthroscopically treated patients with isolated subscapularis tendon tears.

Patients and Methods

Ten patients with isolated tears of the subscapularis muscle tendon arthroscopically sutured between 2010 and 2014 were evaluated. Eight had traumatic lesions. Seven patients were male. The period of pre-operative symptoms ranged from three days to 72 months. Six had complete and four had partial tendon tears. There was 33,3% of associated lesions of the long head of the biceps tendon.

Results

The mean range of motion of the patients has improved from preoperative to final evaluation from 120° to 145° of forward elevation, from 60° to 70° of lateral rotation and a medial rotation from T12 to T9. Six patients returned to their pre-injury level of sports activity. Using the UCLA score, 8 patients had excellent or good results.

Conclusion

Surgically treated isolated tears of the subscapularis tendon lead to good results and patients satisfaction.

Elbow dislocation with ipsilateral distal radius fracture

Rafik Elafram, Mourad Zaraa, Ismail
Jerbi, Safouane Rebhi, Hedi Annabi,
Mehdi Hadhij Salah, Mondher Mbarek

Burn and traumatology centre of Ben
Arous, Tunisia

Introduction

Fracture dislocations around the elbow joint are common and usually involve proximal radius or ulna. Posteromedial elbow dislocation with associated distal radius fracture is a rare entity. Only few cases of elbow dislocation with ipsilateral distal radius fracture have been reported in the literature. We report 04 cases of elbow dislocation with ipsilateral radius dislocation. Methods : We reported 04 cases of elbow dislocation associated to ipsilateral distal radius dislocation. The mean age was 45 years. We reported 03 males and 01 woman.

Results

In our serie, there were 03 postero lateral elbow dislocation and 01 posteromedial. The distal radius fracture were posteriorly displaced. All our patients had reduction with general anesthesia. The distal radius fracture was stabilized by pinning. The limb was immobilized by supine cast. The patient judged the elbow motion satisfactory.

Discussion

Elbow dislocation with ipsilateral distal radius fracture is a rare injury pattern. An extensive search of the literature showed that only few such cases with this combination are reported. The cases already reported are either compound fracture/ dislocation or have occurred in children. This is the first serie of 04 patients reported in the littérature. Most probable mechanism to produce this type of injury would be a fall on the outstretched hand. First, the distal radius fracture occurred due to direct contact of wrist with the ground. This dorsal force would hyperextend the elbow causing dislocation.

Conclusion

We recommend that in every case of elbow dislocation, wrist joints be assessed clinically as well as radiologically for any associated injury. A high index of suspicion of distal radius fracture should be kept in every patient of elbow dislocation.

Orthopaedic Medical Software

Petra Bartolin

Polytechnic of Zagreb, Croatia

The rapid development of technology and collaboration and interaction of different occupations and professions just as the fact that we live in the information age, resulted in great progress in medicine. One of the technology is use of software for biomedical engineering. Today's medical systems, models and devices are controlled by this software that processing medical images and creating 3D models uses 2D cross sectional medical images such as from computed tomography (CT) and magnetic resonance imaging (MRI) to construct 3D models, which can then be directly linked to rapid prototyping, CAD, surgical simulation and advanced engineering analysis. The paper presents a summary structure of the software that are currently in use and their features and applications in orthopedics.

Cephalomedullary nail breakage after trochanteric hip fractures

Ricardo Santos Pereira, Tiago Pinheiro Torres, Miguel Frias, Marcio Oliveira, David Sa, Andre Sarmento

Centro Hospitalar de Vila Nova de Gaia Espinho, Portugal

Trochanteric fractures of the femur are common in elderly individuals with osteoporosis and usually require surgical treatment to facilitate early rehabilitation. Due to their inherent biomechanical advantage, the use of intramedullary nails is increasing, especially for the treatment of unstable trochanteric fractures. Mechanical breakage of cephalomedullary nail osteosynthesis is a rare but devastating complication usually attributed to delayed fracture union or nonunion. We present the cases of implant breakage in two female patients treated surgically for trochanteric fractures. After a period of good initial clinical recovery, both patients developed worsening hip and thigh pain and inability to bear weight a few months after the first surgery. In both cases, fatigue failure was observed at the junction of nail with the lag screw. One of the patients was treated with exchange nailing and autologous bone grafting and the other one with conversion to total hip arthroplasty using a modular, tapered, fluted stem. Both patients were able to partially recover their functionality and independence for the daily life activities with no pain. The results of this series demonstrate that both the described revision surgery options are able to provide good clinical and radiological short-term results in the rare cases of cephalomedullary nail breakage.

Complex Proximal Humeral Fractures - A Case Of Success After Revision Surgery

**Miguel Fria, Ricardo Santos Pereira,
Rafael Portela Silva, Tiago Pinheiro
Torres, Filipe Lima Santos, Pedro
Lourenço**

Centro Hospitalar de Vila Nova de Gaia Espinho, Portugal

Several surgical options are available on the treatment of proximal humeral fractures. A secure reduction and fixation may be difficult to achieve. The PHILOS plate has been developed with the aim of getting a better screw fixation on osteoporotic bone and minimize soft tissue dissection. However, postoperative complications still exist. Year-old woman high energy car accident presents to the emergency department with a fracture in parts of the proximal humeral with displacement of the posterior humeral head. Was subjected to ORIF with plate PHILOS by a delto-pectoral approach. At months postoperatively had a Constant Score of and radiologically an internal rotation of the proximal humerus with respect to the humeral shaft. Underwent further surgery at months post-fracture: a liberation of the sub-scapular was performed with the trochino fragment removal of the distal screws and a surgical neck osteotomy with rotation of the distal fragment re-fixation and reinsertion of the trochino reinforced with transosseous sutures. Passive mobilizations were initiated at days postoperative and active mobilization in the first month having a carefully targeted functional rehabilitation. At 1-month follow-up after the second surgery had a Constant Score of and the osteotomy fully consolidated. Despite the fastening system with PHILOS presents favorable results, postsurgical complications including malunion and desceaptation of osteosynthesis material may happen. In the literature this type of complication is described in approximately 5% of cases. The medium Constant Score at months is described in the literature whereby the overlapping is observed in this case after the second surgery. The fastening system with PHILOS is one of the available alternatives for fractures of the proximal humerus in most cases providing a stable fixation and early mobilization. However, although uncommon complications can occur, namely malunion and the failure of the

Glenoid fractures surgical management - a retrospective clinical study

**Miguel Frias, Ricardo Santos Pereira,
Filipe Lima Santos, Tiago Pinheiro
Torres, Andr Sarmento**

Centro Hospitalar de Vila Nova de Gaia Espinho, Portugal

Scapula fractures are rare, corresponding to less than 1% of the total fractures, and of these, 10% correspond to the glenoid cavity. They essentially occur after high kinetic mechanisms. The diagnosis is made by radiography; however, the use of CT may be required for evaluation of their various fragments. The most widely used classification is the one introduced by Ideberg, dividing it into 5 types. The treatment chosen is most of the times conservative. The indications for surgical treatment are controversial, but include intra-articular fractures with step-off exceeding 5 mm or involvement > 25% of the articular surface. It was evaluated between January 2009 to December 2013 5 patients, 4 males and 1 female, mean age 46 years, with glenoid fracture type II according to Ideberg classification undergoing primary surgical treatment with open reduction and internal fixation by anterior approach. In none of the patients was recorded any postoperative complication and the average Constant score was 85, with a mean follow-up of 26 months. Surgical treatment of fractures of type II Glenoid fractures is a viable option, presents satisfactory results and should be considered in properly selected patients.

Radial head arthroplasty after previously performed resection of the radial head

Barbaric Katarina 1, Starcevic Damir 2, Bojanic Ivan 1

1 Department of orthopedic surgery
Univerzitetni Hospitalni Centar Zagreb
2 Special Hospital for Orthopaedic Surgery
Akromion Krapinske toplice

Radial head arthroplasty (RHA) is often used method in treatment of multifragmentar radial head fractures. Best results achieved arthroplasty performed immediately after the fracture. In cases where radial head is irreparable, and there are no technical conditions for arthroplasty, resection of the radial head is available treatment option. With time, these patients develop different problems like: loss of strength, valgus instability and wrist pain due to proximal migration of the radius. Valgus deformity causes development of cubital tunnel syndrome. Elbow contracture occurs with time, manifesting in the form of a limited joint extension and flexion. Development of degenerative changes leads to the elbow pain appearance. In a one year period, in the Department of Orthopaedic Surgery in University Hospital Centre Zagreb we performed RHA in 5 patients in whom radial head excision, due to fracture, was already done. There were 3 male and 2 female patients, average age 51.2 years (from 44 to 57). RHA in these patients was associated with several problems. One of the problems we encountered was inability to perform the arthroplasty due to previous excessive resection of radial head. An additional problem was abundant scar tissue that caused elbow contracture and increased risk of interosseus posterior nerve injury due to changed anatomical relations. Preliminary treatment results showed a significant improvement in the functional status accompanied by marked reduction in symptoms in average follow up period of 11.2 months (from 3 to 15). Although RHA is conceptually attractive and sound in situations in which radial head excision is inadequate, clinical experience is still limited. Surgical treatment requires precise preoperative planning, while in the postoperative period a persistent and long-term implementation of adequate physical therapy with mandatory prophylaxis of heterotopic ossification are required.

Operative treatment of recurrent anterior shoulder dislocations in competitive level athletes

Danijel Matek

KBC Zagreb, Croatia

Objective

Presenting 7-year results and giving guidelines for operative treatment of recurrent anterior shoulder dislocation in competitive level athletes.

Methods

In the period 2008-2015, eighty one competitive level athlete with recurrent anterior shoulder dislocation were treated by arthroscopic or open shoulder stabilizing operative techniques. All patients were immobilized by shoulder-elbow orthosis for 4 weeks and were evaluated preoperatively and postoperatively by UCLA, ASES, Rowe shoulder scores.

Results

Mean age at the time of operation was 23.2 years and mean follow-up was 49 months (range 21-81 months). The average UCLA Shoulder score was 22.4 ± 2.6 preop, 33.3 ± 2.3 postop. Excellent results (34-35) were obtained in 69 patients, good (28-33) in 10 patients and fair/poor (27 or less) in 2 patients. The ASES score was 68.5 preoperatively, improved to 93.1 postoperatively ($P < 0.001$). The Rowe score for instability was 33.5 preoperatively, improved to 87.2 postoperatively ($P < 0.001$). In total, 72 athletes (88.8%) returned to preinjury sports activity levels. Four athletes (4.94%) experienced postoperative instability - three subluxations (3.7%) and one redislocation (1.23%). The mean forward flexion and abduction did not change from preoperative values and while there was certain loss of external rotation (averaging 72.3° preoperatively and 64.4° postoperatively) it was not statistically significant.

Conclusion

Operative treatment of recurrent anterior instability by arthroscopic or open operative techniques are reliable and reproducible procedures with respect to shoulder function and return to sports activities at preinjury level.

Vanishing bone disease (Morbus Gorham-Stout) of the proximal humerus - case report

Danijel Matek

KBC Zagreb, Croatia

Sixty four year old female patient came to our Department with severe pain and disability of the right shoulder, which lasted for 6 months, with no known trauma history. She came for a second opinion after being treated by general surgeon. On physical examination movements in right shoulder were severely reduced due to intolerable pain, without neurological deficit. An X-ray imaging was done, rapid bone loss was noticed. Laboratory studies showed slightly elevated levels of ESR and C reactive protein. Alkaline phosphatase level was normal. Laboratory studies revealed no evidence of metabolic, immunologic, neoplastic or infectious etiology. A bone biopsy was performed, at the edge of the remaining proximal humerus. Histopathologic finding revealed thickened bone of lamellar structure, with few fibroblasts and newly formed vascular channels. There wasn't any osteoblastic activity, only a few osteoclasts were noticed. The patient underwent a reverse total shoulder replacement. Intraoperative findings showed complete replacement of the humeral head space by fibrous tissue with severe destruction of rotator cuff - massive tear of supraspinatus and infraspinatus tendons. The diagnosis of vanishing bone disease (Morbus Gorham-Stout) is based on clinical examination, radiologic imaging studies, and histopathologic examination of the affected area. Thirty seven months after total shoulder replacement the patient is pain free, without neurological impairments, undergoing physical therapy with range of motion as follows: abduction 140°, forward flexion 155°, internal rotation 35° and external rotation 40°. Clinically and radiologically there was no further bone loss and no evidence of endoprosthesis loosening at 37 months followup. Constant score increased from 12 to 70.

Pedicle vascularized bone grafts for disorders of the carpus

Barbaric Katarina 1, Starcevic Damir 2, Wertheimer Vjekoslav 3, Delimar Domagoj 1

1 Department of orthopedic surgery
University hospital centre Zagreb
Zagreb 2 Special hospital for orthopedic surgery Akromion Krapinske toplice
3 Department of orthopedic surgery
University hospital centre Osijek

Pedicle vascularized distal radius bone grafts (VBG) offer a peculiar treatment option which can be used with other treatment procedures in the management of carpal disorders like: scaphoid nonunion, Preiser's disease, or Kienböck's disease. We present indications and different operative techniques for four patients treated in our Department because of various carpal disorders. Two male patients with scaphoid nonunion were operated using different VBG. A 29-year old male with proximal pole nonunion was treated with capsular-based distal radius VBG. A 26-year old male, after failed Matti Russe procedure, was treated with distal radius VBG using 1,2-intracompartmental suprarotational artery (1,2-ICSRA) and additional fixation with Herbert screw. The 1,2-ICSRA graft was also used for treatment Preiser's disease in 33-year old woman. Second stage of Kienböck's disease in 29-year old female was treated with combination of distal radius shortening osteotomy and revascularisation with 4,5 ICSRA VBG. In all operative procedures we used tourniquet but without exsanguination to facilitate identification of the vessels. The vascularity of the graft was confirmed during surgery with tourniquet release. Vascularized bone grafts have superior biological and mechanical properties resulting with faster and more reliably healing than nonvascularized grafts. They also bring osteogenic and angiogenic factors into site of avascular necrosis that facilitate revascularization and bone remodeling of the avascular segment or whole bone. VBGs therefore represent a unique option of biological reconstruction which can be used in a specific cases in order to preserve the integrity of the carpal bones and avoid salvage procedures, which are characterized by significantly poorer functional results, that can be extremely important in young, active patients.

Reconstruction of distal ulna and distal radiolunar joint after wide resection of giant cell tumor

Barbaric Katarina 1, Starcevic Damir 2, Smerdelj Miroslav 1

1 Department of orthopedic surgery
University hospital centre Zagreb
Zagreb 2 Special hospital for orthopedic surgery Akromion Krapinske toplice

A - year old man presented in our Department with pain in the distal part of his right forearm after fall and X - ray images that showed expansive formation in the distal part of the right ulna Detailed history revealed that he had pain in his arm months earlier Computed tomography magnetic resonance and bone scan followed by biopsy were performed in our Department Uncertain patohistological findings could not distinguish if it was GCT or tumor had an osteosarcomal component so we decided for two stage procedure First we performed en bloc resection of distal cm of ulna and temporary reconstruction with cement spacer Triquetrum and pisiforme bone were also excised because imaging methods showed their involvement with tumor After definitive pathohistological confirmation of GCT gradus I - II second stage reconstruction procedure was performed Distal part of ulna was reconstructed with free autologous fibular graft fixed with mm DC plate and screws Distal radiolunar joint (DRUJ) was reconstructed with palmaris longus tendon with modified Adams procedure In order to compensate triquetrum and pisiforme bone loss and stabilize the ulnar side of the wrist interposition arthroplasty using half of the extensor carpi ulnaris tendon was done Ten months postoperatively patient was feeling well had no pain and had satisfactory wrist range of motion Control X - rays showed adequate integration of fibular graft at the site of osteosynthesis with no signs of tumor recurrence DRUJ was stabile and pain free DASH score during one year follow up improved to compared to preoperatively GCT of the distal ulna is rare tumor classified as benign aggressive but carry a relatively high rate of recurrence Although difficult to manage anatomical reconstruction after resection around wrist joint especially in young active patients should be method of choice when ever is possible

Treatment of chronic transscaphoid perilunate dislocation of the wrist: A case report

Starcevic Damir, Klobucar Hrvoje, Medancic Nenad

Special Hospital for Orthopaedic Surgery Akromion

Introduction

Transscaphoid perilunate dislocation of the wrist is complex injury that occurs from extensive, high-energy dorsiflexion. Early open reduction and internal fixation of these injuries is required to provide accurate alignment and the option for ligament repair. Chronic cases are very rare and can lead to permanent and devastating consequences. Their treatment represent great challenge for surgeon.

Methods

A 19 year old man presented in our hospital with pain, swelling and limited ROM of the right wrist and tingling in first three fingers of right hand. Four months ago he was involved in car accident where he sustained fracture of his left collar bone, left forearm and right wrist. X-ray and CT showed dorsal transscaphoid perilunate dislocation, fracture of ulnar styloid, ulnar translocation of carpal bones and loss of carpal height. EMNG showed compression of median nerve in carpal tunnel. Decompression of median nerve in carpal canal was performed through volar approach. Dorsal approach through third extensor canal was used to expose carpus. A radially based, dorsal flap capsulotomy is performed, as it preserves dorsal ligamentous structures. Reduction of carpus and scaphoid was done and secured with Kirschner wires. Autologous cancellous bone graft from distal radius was interduced in to the fracture site of scaphoid and fracture was fixed with FRS compression screw. We also performed fixation of ulnar styloid with transosseal suture. Kirschner wires were removed after 10 weeks and physical therapy started.

Results

Eighteen months after operation scaphoid fracture is healed, patient has no pain with satisfactory ROM and wrist function.

Conclusion

Systematic approach to this complex injury with anatomic reconstruction can result in favorable outcome and it should be attempted even after four months, especially in young patients.

The algorithm for shoulder arthroplasty implant selection

Nejc Kunčič

Ortopedska bolnišnica Valdoltra,
Slovenia

The algorithm for shoulder arthroplasty implant selection Nejc Kunčič, Rihard Trebše Valdoltra Orthopaedic Hospital, Ankaran, Slovenia

Introduction There still is no consensus in the literature regarding indications for a particular type of implant in primary shoulder arthroplasty.

Objectives Algorithm for shoulder implant selection was introduced in 2000. Our aim was to choose the least invasive procedure for a particular situation and to avoid late complications:

1. Healthy patients up to 60 years old independently of the diagnosis: hemiarthroplasty, either stemmed or resurfacing,
2. Old patients primary arthritis: total shoulder arthroplasty.

In inflammatory arthritis and conditions that limited life expectancy or activity this indication was extended to younger patients,

3. Old patients cuff arthroplasty and acceptable function: hemiarthroplasty, stemmed or resurfacing,
4. Old patients poor function – pseudoparalysis – inverse shoulder arthroplasty.

Methods 183 shoulders were operated according to the protocol. The surgical approach was standardized deltopectoral. All patients had returned for at least 1 follow up visit (mean 5 years, range 1-13 years).

Results The CM score improved considerably from 24 points preoperatively to 74 at the last follow-up. There were no definite nerve lesions, and nobody suffered a major adverse event during hospitalisation. There were three revisions – 1,6% (early infection with *Staphylococcus conii*, posttraumatic dislocation and persistent pain).

Conclusions The algorithm proved to effectively select patients for appropriate implant giving high satisfaction rate and low revision burden.

Keywords: Shoulder, Arthroplasty, Primary, Algorithm

Clinical parameters after Fondaparinux vs Nadroparin thromboprophylaxis in total knee arthroplasty

Damjan Dimnjaković

KBC Zagreb, Croatia

Regarding the possible perioperative complications such as deep vein thrombosis or pulmonary embolism, the role of thromboprophylaxis in orthopedic surgery is extremely important. Fondaparinux, with no cases of HIT proven until today, is a direct Xa inhibitor which is indicated to be as effective as LMWH. The main goal of our prospective randomized control trial was to define if the thromboprophylaxis in patients undergoing TKA due to primary osteoarthritis of the knee, influences clinical parameters in the same manner in patients receiving Fondaparinux as in those receiving Nadroparin during the first 14 postoperative days. Unilateral TKA was performed by a single surgeon at our Department in sixty patients with primary osteoarthritis of the knee. Patients were randomized into two groups consisting of 30 patients each, receiving thromboprophylaxis with either Fondaparinux or Nadroparin. Comparison between groups was made regarding laboratory results (CBC, aPTT, PT, CRP, SE, D-dimers), duration of the operation, perioperative blood loss (intraoperative bleeding, postoperative autotransfusion, postoperative bleeding and postoperative allogotransfusion), and clinical evaluation of the edema of the operated leg during the early postoperative period. Regarding the average duration of the surgery or the perioperative blood loss, no statistically significant differences were found between the groups. Similar results were also found regarding the CBC, aPTT, PT or D-dimers as well as clinical signs of the edema of the knee and the lower leg. The only statistically significant difference was found between the groups regarding the level of urea, which was significantly lower in the Nadroparin group on the first and second postoperative day. No cases of HIT, DVT or PE were noted during this study. Our results show that both Fondaparinux and Nadroparin have the same influence on clinical parameters during the first 14 postoperative days in patients undergoing TKA.

Does the use of a tourniquet in total knee arthroplasty is necessary and the effects on functional and clinical outcome and on knee range of motion.

**Srdjan Dojcinovic Fribourg, Suisse
Renaud Maes, Bruxelles, Belgique
Sladjan Marinkovic, Vladicin Han, Serbia
Mirko Kovacevic, Beograd Serbia**

Clinique Gnrale

Patients and methods

140 patients were randomized into a tourniquet group (n=70) and non tourniquet group (n=70). All operations well performed by the same surgeon and follow up was for 1 year with the same TKA (XNOV). Primary outcomes were functional and clinical outcomes, as evaluated by KOOS and knee ROM. Secondary outcomes were intraoperative blood loss, surgical time, postoperative blood loss, surgical time and visibility, postoperative pain, analgesic consumption, transfusion requirements.

Results :

Patients in the non-tourniquet group showed a better outcome early knee ROM from surgery to week 6. No difference was detected at the 6 and 12 month follow-ups. Postoperative pain and analgesic consumption were less when tourniquet was not used. Surgical time was similar between two groups. Intraoperative blood loss was greater when not using a tourniquet, but no postoperative transfusions were required.

Conclusion:

This study shows that TKA without the use of tourniquet results in faster recovery in terms of better functional outcome and improved knee ROM. Furthermore reduced pain and analgesic use were registered and no intraoperative difficulties were encountered.

Does the anterolateral minimally invasive total hip arthroplasty have clinical advantage over classical lateral approach? A prospective three-year follow-up study.

Joško Jeličić

Anton Tudo 1 Lana Ružić2 Mirela Vučković 1 Tomislav Mađarević 1 Tomislav Prpić 1 Ivan Rakovac 1 Branko Šestan 1 Dalen Legović 1 Veljko Šantić 1 Joško Jeličić 3

1 University Hospital for Orthopaedic Surgery Lovran Lovran2 Department of Sport and Exercise Medicine School of Kinesiology University of Zagreb Zagreb 3 Orthopaedic Hospital Biograd nm

Introduction

The lateral conventional hip approach and the minimally invasive anterolateral (ALMIS) approach are very common in orthopaedic surgery across Europe.

Purpose

The main idea of this study was to compare functional clinical outcome of the patients operated by the anterolateral MIS approach (a muscle-sparing technique - modified Watson-Jones approach), and the patients operated by direct lateral approach without the muscle-sparing technique (conventional - Bauer Hardinge approach).

Methods

A total of 130 patients were randomly assigned to two groups: 68 in standard method (STAND) group and 62 in minimally invasive (MIS) group. Hip flexibility, patient mobility, strength of the hip abduction, pain scale, Harris hip score, duration of the hospital stay, and overall satisfaction were measured after seven days, three months, one year, and three years after the surgery. Response rate was 100% at the first three controls and 63% at the last.

Results

At first three follow-ups the statistically significant

differences were determined between the groups in hip abduction strength, passive and active hip flexion ability, where MIS group was better in all three follow - ups ($p < 0,05$). Patients in MIS group also suffered less pain, used crutches less, stayed in hospital shorter, and were overall more satisfied with the operation outcome . After three years we measured only parameters that were different at previous contols. There were no differences in perceived pain between STAND and MIS group. However MIS group still showed superior strength of the abductor muscles and took shorter time to walk 50m polygon.

Conclusion

We recommend ALMIS approach for total hip replacement therapy, especially for younger, active population.

Aseptic acetabular component detachment of total hip prosthesis with pelvic discontinuity

João Morais, Tiago Rebelo, Zico Gonçalves, José António Gomes, Francisco Agostinho, Manuel Sousa

Centro Hospitalar Tondela Viseu, Portugal

Introduction: With an aging population, and with the increase in obesity, the number of total hip arthroplasties tends to increase, thereby increasing the number of revisions. The literature shows that the most common causes for total hip arthroplasty revision are, regardless of the component, instability/dislocation and infection. The isolated revision of the acetabulum represents about 12% of all revisions, being the most frequent cause of loosening.

Material: We present the case of a 68 years old patient, with a right cemented total hip arthroplasty (THA) placed 16 years ago. Went to the emergency department in December 2011 by history of fall 1 week earlier, referring pain to the right hip during gait. Radiographic study showed acetabular component detachment and possible pelvic discontinuity (Paprosky IIIB).

Methods: The patient was operated in April 2012 and was carried out extraction of the acetabular cup and cement and was placed a screwed Kerboull ring with trabecular titanium acetabular cup without surgical complications.

Results: A good evolution in the postoperative rehabilitation progra. At 2 months revealed no pain and performed gait with crutches. A year after surgery walks without crutches, without limping and without pain complaints. Radiographic study shows prosthesis unchanged. **Discussion:** The treatment of the acetabular component of bone defects associated with detachment depends on the characteristics of the patient, the location and degree of defect and the presence or absence of pelvic discontinuity. The ultimate goal of acetabular revision is obtaining a stable fixation and restore the joint center.

Conclusion: The objectives of an acetabular component revision are replacing the primary implantation of an acetabular component ensuring functional capacity and lasting symptomatic relief. Regardless of defect found, there is a broad spectrum reconstruction options.

Cementless Hemiarthroplasty in Patients older than 70 years age

Hongman Cho

Gwangju veterans hospital, Republic of Korea

Introduction

The purpose of this study was to evaluate the clinical and radiographic outcomes of cementless proximally coated femoral stem in patients who were at least seventy years of age at the time of the operation.

Materials and Methods

A retrospective study was taken on patients that is hips aged years or older at the time of operation in hip fractures including femoral neck and intertrochanteric fractures. The average follow - up duration was five years - ranging from to years.

Results

Clinically the difference between preoperative and postoperative Harris hip score was points and the final follow - up points was on average - ranging - The Merle d ' Aubigne and Postel scale were and points respectively. The daily activity level was lowered approximately to grade by Kitamura methods one year after operations

Conclusions

Bipolar hemiarthroplasty using a cementless porous coated femoral stem in the elderly has been regarded as safe and effective treatment. However it is advised to take good care of the patients with dementia and adduction contracture in case of cerebrovascular stroke because this disease may be complicated dislocation.

Patient compliance after total hip arthroplasty

Mitrovic Hrvoje; Bitunjac Dragutin, Knezevic Nenad, Pitlovic Hrvoje, Kuduz Robert, Orlovic Katarina

General hospital dr. Josip Bencevic Slavonski Brod

The number of total hip arthroplasty carried out in our hospital rising yearly. The aim of out-patient follow up after THA is detection of early failure when revision surgery can be performed more easily and with better results. Our protocol includes review of patient every second year (on alternate years). We performed retrospective review of clinical follow up compliance for 520 patients who underwent total hip arthroplasty from 2002-2009. (FU 5-13 y). Overall compliance was 35%. Patients younger than 60 y, female patients and citizens of town where arthroplasty was performed had better compliance.

Metal – on – ceramic total hip arthroplasty can cause early debris with inflammatory response and pain? – a case report

Ćorluka Stipe, Čengić Tomislav, Kolundžić Robert

Department of Traumatology, University Hospital Centre Sestre milosrdnice

We are presenting 75 year old male patient who developed small particle disease as a result of tissue reaction on metal – on – ceramic type of hip implant. Patient underwent total hip arthroplasty (THA) procedure three years ago with metal – on – ceramic type of implant. Eight months after initial THA patient had accident and periprosthetic fracture was reported with instability of femoral component of implant. Second procedure included replacement of femoral component. Postsurgical procedure and rehabilitation went well and patient didn't have any complications. Seven months after second procedure patient reported severe pain in left leg, specially in hip region. Range of motion in left hip was reduced and painful and patient was referred to scintigraphy of the left leg. Scintigraphy found positive accumulation in left hip region so orthopaedic surgeon indicated extraction of existing implant. Intraoperative were found plenty of subacute inflamed fibrosed tissue and biofilm intramedullary while femoral component was extracted. Tissue samples were administered to pathohistological analysis and multiple examples were administered to cell culture analysis and antibiogram. Wound was treated with flow drainage for five days. All laboratory findings were negative on microorganism activity, cell culture showed small particle disease as a result of tissue reaction on implant. Two months after extraction of implant, the new THA was performed with metal – on – crosslinked polyethylene type of implant. Postoperative period went without complications, the patient didn't have pain in left hip region, after rehabilitation range of movements in left hip after second THA are satisfactory.

AMIS-What we learned In The Past 7 years

Stanislav Ovnič, Ivo Bricman, Jakob Merkač, Vasja Kašnik

General Hospital Slovenj Gradec, Slovenia

Anterior Minimally Invasive Surgery (AMIS) - What We Learned In The Past 7 Years

Introduction: Minimally invasive operative approaches for the hip surgery gained a lot of attention in the last decade. Anterior approach is one of them.

Objectives: Since May 2007 and until March 2014 in a regional hospital two orthopedic surgeons conducted 148 primary and 1 revision AMIS surgery. The operative technique had to be learned and the learning curve is slow. Are there any differences in operative technique, early postoperative ambulation, limb lengthening after 7 years of experience with AMIS technique? Methods: Retrospectively we analyzed all 149 patients, 47 male and 102 female. The following parameters were analyzed: operative blood loss, drainage from operative wound, volume of blood reinfusion by OrthoPAS® system, volume of blood transfusion, duration of surgery, duration of hospitalization, postoperative limb length equality and intra operative and post operative complications.

Results: The data showed reduced intra operative blood loss: 736 ml/ patient in 2007 compared to 307,27 ml/patient in 2014. The need for blood transfusion was significantly reduced: 365,71 ml of blood transfusion in 2007 compared to 31,5 ml of blood transfusion per patient in 2014. Duration of surgery (87,77 minutes in 2007 compared to 55,45 minutes in 2014) and duration of hospitalization (12,05 days in 2007 compared to 8,9 days in 2014) were diminished. Postoperative limb length discrepancy was 0,47 cm/patient in 2007 compared to 0,22 cm/ patient in 2014.

Conclusion: After learning curve and 7 years of experience with AMIS technique our results shows that the operative blood loss, need for transfusion, duration of operation and hospitalization and postoperative limb length discrepancy were significantly reduced. The main reason to continue with AMIS technique is the preservation of hip musculature and that for significant less postoperative pain, earlier rehabilitation and satisfied patients.

Use of reinfusion drains in Total Knee Arthroplasty a retrospective study of 200 cases

João Morais, Tiago Rebelo, Zico Gonçalves, Frederico Paiva, Eduardo Mendes, Manuel Sousa

Centro Hospitalar Tondela Viseu, Portugal

Total knee arthroplasty (TKA) is a procedure usually associated with substantial blood loss. Since allogeneic blood (AB) is an expensive resource, different methods avoiding ABT have been tested. One solution is the use of unwashed filtered shed blood from postoperative drainage. Despite the clinical benefits are well described, studies results are conflicting about effectiveness and cost-benefit of reinfusion drains (RD). This study aims to investigate whether the introduction of RD resulted in reduction of the number of units of AB transfused and if has resulted in cost savings. Retrospective study including 200 primary TKAs performed between January 2014 and October 2014; 100 cases with the use of vacuum suction drain (VSD), and 100 cases with use of RD. The criteria used for AB transfusion were the same in both groups. A set of demographic and clinical data was collected in all patients. Statistical analysis was carried out using appropriate tests. In the RD group, 44 were transfused AB units compared with 62 units transfused in VSD group ($p=0.2$). The hemoglobin count decreased on average 2,95g/dL in the RD group and 3,49g/dL in VSD group ($p=0.003$). The average hospitalization time was 8,54 days in the RD group and 9,91 days in the VSD group ($p=0.002$). The average volume reinfused in the RD group was 412,45mL. The direct costs associated with the drain and used for transfusion of AB when necessary, averaged 201,77€/patient in the RD group and 133,12€/patient in the VSD group. The introduction of RD did not resulted in increased side effects. In the RD group there was an increase in direct costs compared to the VSD group. However this study did not take into account clinical and financial benefits that are difficult to assess.

Surgical treatment of gonarthrosis associated with the proximal tibial stress fracture

Slavko Manojlović

Institute of Orthopaedics, physical medicine and rehabilitation Dr. Miroslav Zotović, BiH

Introduction

Proximal tibial stress fractures (PTSF) associated with gonarthrosis which require total knee arthroplasty rarely occur in practice. Patient usually does not give us information about the trauma. Objectives: To show the possibilities of surgical treatment of gonarthrosis with associated PTSF.

Materials and methods

In IOPMR "Dr Miroslav Zotovic" from June 2004. to December 2014. 1874 TKR were performed. The indication for surgery in 8 patients was severe bilateral gonarthrosis associated with unilateral PTSF (in all of these patients, we first operated knee with associated PTSF). None of the patients gave us information about the traumatic event. Modular total knee endoprosthesis was implanted to 6 patients: with the Küntcher's nail (2 patients), with a long tibial stem (4 patients), with AO plate (2 patients). After surgery all patients were involved in the early rehabilitation treatment according to the protocol of our institution. Results: In one patient, to whom Küntcher's nail was primary implanted, there was no union of fracture, nail was removed, apparatus Ilizarov was placed. Fractures of the proximal tibia healed in all patients. Also all patients had a good anatomical and functional recovery and they returned to daily living activities.

Conclusions

Surgical treatment is the treatment of choice in patients with stress fracture associated with osteoarthritis, which causes severe deformities. Modular total knee endoprosthesis with tibial extension is an adequate solution for gonarthrosis associated with PTSF, because it corrects the deformity, stabilizes the fracture and solves arthrosis.

Lateral approach in primary TKR

Slavko Manojlović

Institute of Orthopaedics, physical medicine and rehabilitation Dr. Miroslav Zotović, BiH

Introduction

In valgus deformity of the knee with angulation more than 10° there is a stretch of medial soft tissue structures (primarily MCL) and moderate or severe hypoplasia of the lateral condyle. In addition, there is a certain degree of lateralization of the patella, external rotation of the tibia, and internal rotation of the femur.

Objectives

To present the advantages of the lateral approach in TKR due to degenerative knee osteoarthritis associated with knee valgus angulation more than 10° , and with patellar dislocation or subluxation.

Materials and methods

The work included 41 patients (32 women, 9 men) who underwent surgery in IOPMR "Dr M. Zotović" during period May 2008 - December 2014. Surgical technique involved a lateral approach to the knee joint, which will be described in detail. Patients received standard antibiotic and thromboembolic prophylaxis, and they were included in the program of early rehabilitation with full bearing allowed on the operated leg first postoperative day. All patients were followed radiologically and functionally (HHS, Womac index).

Results

The approach itself performs a release and balance and this improves the stability and patellar tracking. In all patients we achieved the restitution of the lower extremity axis. We have not noted avascular necrosis of the patella, which is described in the literature as the most common complication with this approach.

Conclusions

The lateral approach because of its advantages is the technique of choice in TKR in gonarthrosis with valgus angulation of the knee of more than 10° degrees.

A Rare Case Report: *Achromobacter xylosoxidans* Infection Following Total Knee Arthroplasty

Abdülkadir Bilgiç; Özdamar Fuad Öken; Ahmet Özgür Yıldırım; Ahmet Uçaner

Ankara Numune Training and Research Hospital, Turkey

Achromobacter xylosoxidans is an opportunistic organism mainly causing infection in immune compromised hosts. Infections with *A. xylosoxidans* have included bacteremia meningitis urinary tract infections abscesses osteomyelitis corneal ulcers prosthetic valve endocarditis peritonitis and pneumonia. Only two case of periprosthetic infection by *A. xylosoxidans* has been reported. The patient in one of these cases was receiving high dose prednisone for rheumatoid arthritis. The other patient has reported with no medical history of immune suppression. Our patient is a 76 year old woman. After 19 years of knee arthroplasty she has operated with revision arthroplasty in external center for aseptic loosening. She has no medical history of immune suppression. After one month of operation wound dehiscence occurred on knee and hyperbaric oxygen therapy applied for 30 seance. When she admitted to us the tibial component was exposed and we planned two stage revision arthroplasty. At the first stage revision surgery for removal of implant we take culture and put antibiotic cement. Both preoperative and intraoperative specimen cultures revealed *Achromobacter xylosoxidans*. The bacteries are incubated in blood agar and EMB medium for three days on 37 Celsius degrees and defined with Bruker Maldi - Tof Biotyper. Antibiogram was performed with Phoenix system After this an eight week course of intravenous Piperacillin Tazobactam was started. The second stage of the revision was performed ten weeks after the first stage with two weeks of observation without antibiotic to confirm eradication of infectious microorganism. Clinically showed no external signs and biochemical findings of infection. Intraoperative culture was negative After three months of second stage surgery physical examination revealed no signs of infection. This case demonstrates that *A. xylosoxidans* is a pathogen capable of causing prosthetic joint infection and removal of implant thorough debridement and appropriate antibiotic treatment is essential for the success of revision.

Surgical Treatment of Dementia Patients Following Undisplaced Femur Neck Fractures

Jungryul Kim

Busan veterans hospital, Republic of Korea

Background

People with dementia have been reported to have poor mobility and discharge outcomes following hip fracture. Minimally displaced femur neck fracture (MDFNF) is treated with internal fixation by proximal femur antirotation (PFNA) or three partially threaded cannulated screws (i.e. multiple cannulated screw (MCS) fixation). The present study compared outcomes for these two fixation methods.

Methods

We retrospectively 22 MDFNF patients over 70 years of age who walked independently with a cane or crutches and who suffered moderate-to-severe dementia. They were divided into PFNA (11 patients) and multiple cannulated screw (MCS; 11 patients) groups and followed up on for two years. Revision, loss of fixation, complication, and Koval-grade outcomes were measured.

Results

In each group, there was one death two losses to follow-up. There was no statistically significant difference in radiological union or walking ability between the groups. One MCS patient required re-operation. Nonunion developed in two MCS patients and one PFNA patient. Avascular necrosis of the femoral head developed in two patients, one from each group.

Conclusions

This study found no difference in outcomes between PFNA and MCS in the treatment of MDFNF in a dementia population, though it also found that PFNA can provide an alternative to MCS fixation for MDFNF in patients with poor cognition as in cases of dementia.

Atypical femur fracture as a result of long term bisphosphonates therapy

Tiago Rebelo

Centro Hospitalar Tondela Viseu,
Portugal

Introduction

Bisphosphonates are a safe drug, well tolerated and with demonstrated efficacy. Regardless of that, there are increasing reports of atypical femur fractures (AFF) associated with long-term therapy with this class of drugs (over 5 years). It is thought that the lesion mechanism is related to the prolonged suppression of bone remodeling, changes in collagen pattern and bone vascularization alterations.

Material and Methods

The authors describe the case of a 72 years-old female, treated with alendronate for the past 8 years. The patient was taken to the emergency room for sudden pain in hip and thigh without associated trauma. X-ray showed a subtrochanteric fracture of left femur. Was treated with a short Gamma Nailing and suspended the treatment with alendronate. 3 years after the patient suffered minor trauma to the lower limbs which resulted in bilateral femur shaft fracture. The patient was treated with bilateral anterograde femur nailing.

Results

There were no complications in the immediate post-operative, the patient initiated physiotherapy and gait training with crutches in the 3th day after surgery and after 3 months the patient has no pain or functional impairment.

Discussion

Despite of the rarity of this type of fractures, they are becoming increasingly more frequent with the widespread of bisphosphonates therapy. The optimal duration of treatment with bisphosphonates remains controversial. There is no contraindication for the long-term therapy with bisphosphonates. Take home message AFF are relatively rare events, and the balance between patient efficacy and safety still favors bisphosphonate therapy for the treatment of osteoporosis, despite that a drug holiday period should be considered in patients who take bisphosphonates longer than 5 years.

Case Report: Man Versus Digger

Katherina Butler

John Radcliffe Hospital Oxford, United Kingdom

A 28 year old fit, healthy male sustained multiple injuries caused by blunt trauma from the scoop of a digger. He presented haemodynamically unstable with severe pelvic, abdominal and thoracic injuries. He was stabilised and further imaging found a traumatic hemipelvectomy, damage to the external iliac vessels, a diaphragmatic hernia and an abdominal wall hernia. He underwent emergency fixation of the pelvis with an external fixator and sacroiliac screws and was then admitted to the Intensive Care Unit which gave time for discussion and planning of the next step in his care. He later underwent a four compartment fasciotomy but unfortunately after days of treatment we had to proceed to an above knee amputation due to ischaemia and rhabdomyolysis. Acute tubular necrosis secondary to his rhabdomyolysis complicated his treatment as well as dietary intolerance. He had to start regular dialysis and required extensive amounts of rehabilitation. This is a severe polytrauma case with many unfortunate, but some predictable, complications. The discussion addresses the possible management plans and rationale behind the management of this patient and his injuries.

Our experience of Achilles tendon repair _ absorbable vs non absorbable suture repair.

Muhammad N Baig, Robert Din.

Kerry general hospital, Ireland

Background

We retrospectively studied our Achilles tendon acute rupture cases done over past 2 years and reviewed the outcome and complications.

Methods:

The inclusion criteria was acute rupture, 18 yrs or older and with complete Achilles rupture. 57 pts were included who completed the criteria ranging from 20 to 75. There were 38 male and 19 female patients. We did open end to end repair. We retrospectively collected their bio-data, medical history and mode of treatment. We followed them over up to 6 months with regards to outcome and complications. The boyden score was estimated at their follow up visits. Results:

RESULTS

Out of 57, 4 were treated conservatively because of their medical co-morbidities, age and functional requirements. 53 were operated using ETHIBOND Suture (a non absorbable, braided, sterile, surgical suture composed of Poly -ethylene terephthalate) and PDS (POLYDIAXANONE-monofilament synthetic absorbable suture) or only PDS. Complications- Intra-op and post op complications were recorded. The post op complications were divided on early and late complications. About 6 surgical infections of the operative site and 2 complications over longer period came as thickening and stiffness.

Conclusion

We came with this outcome that in majority of patients the functional outcome results were good to excellent. We observed that a particular technique of repair was related to infection rate as all of them who got infection were repaired using ethibond. We also observed that dvt prophylaxis should be regularly give in the patients.

Do vitamin D levels correlate with severity of hip fractures?

Yuet Peng Khor

National University Hospital, Singapore

Objectives

Osteoporotic hip fractures present a burden to health care. Hypovitaminosis D is a risk factor for fracture and osteoporosis. We hypothesise that the more severe the vitamin D deficiency, the more severe the hip fracture.

Materials and methods

We performed a retrospective study of patients above age 60 admitted to our institution over a 3 year period. Data was collected through review of electronic medical records and radiographs. Results 450 of 577 (76%) patients had their vitamin D levels checked. 10 patients were excluded (4 without radiographs, 2 pathological fractures, 4 wrong coding). Mean age was 79 (60-102). There were 332 female (74%) patients and 203 right hip fractures. 366 patients were chinese, 45 malay, 19 indian and 20 other race. 238 patients had neck of femur fractures and 202 had intertrochanteric fractures. 57 had Garden 1 or 2 fractures with a mean vitamin D level of 20.1 ug/L. 181 had Garden 3 or 4 fractures with a mean vitamin D level of 18.9. 99 patients had Jensen 1 or 2 fractures with a mean vitamin D level of 18.5. 103 patients had Jensen 3, 4, 5 or reverse obliquity fractures with a mean vitamin D level of 16.9.

Conclusion

The whole cohort had severe hypovitaminosis D and we were unable to determine whether this correlated with more severe fractures. More studies are required to determine whether treatment of hypovitaminosis D could aid in preventative strategies for hip fractures in our population.

Distal Femoral Fractures 5 Year Mortality And Secular Trends

Piers Turner

Newcastle University, United Kingdom

Introduction

Distal femoral fractures are 10 times less common than hip fractures. 12-month mortality has been reported as 25-30% but there is no longer-term data. In Northumbria hip fractures have a 5-year mortality of 68%. Objectives: To analyse 5-year mortality in distal femur fractures in the Northumbrian NHS trust, and identify risk factors for mortality. To compare the results to literature standards and Northumbrian hip fracture data.

Methods: This retrospective observational study included patients admitted with distal femur fractures (AO type 3.3), including periprosthetic fractures, between 01/01/05 and 31/12/07. Patient information, which included age, gender, co-morbidities and date of death, was collected through hospital coding and analysis of notes. Co-morbidity data was only available for 53 patients. Mortality rates were calculated, and stratified according to age, gender and co-morbidities. The results were analysed using backwards-multivariate linear regression to determine the significance.

Results: 83 patients (74 female) were identified and the population had a mean age of 80 years (range 60-102). The overall 5-year mortality was 72%. Mortality increased with age and being female may be a risk factor. Dementia and COPD were the only statistically significant predictors of mortality.

Conclusions

This study shows a 5-year mortality of 72% in patients over 60 with distal femur fractures. 1-year mortality rates (20%) are lower than the defined literature standards, showing the trust is performing well. 5-year mortality was higher than that of hip fractures in Northumbria, highlighting the vulnerability of this patient group.

Daily senior review and documentation in trauma and orthopaedic surgery – are the comprehensive unit-based safety programme toolkits useful? And orthopaedic surgery are the comprehensive unit based safety programme toolkits useful?

Alexandra Colby

University Hospital Aintree, UK

Background

Daily senior review is of paramount importance to provide optimal clinical care and facilitate timely discharge. Also, the General Medical Council state in Good Medical Practice 2013 that "work should be recorded clearly, accurately and legibly...containing relevant clinical findings, decisions made and actions agreed". This audit aims to evaluate whether all trauma and elective Orthopaedic patients at one unit receive a daily senior review, which is fully documented in the case-notes, and whether a Comprehensive Unit-based Safety Programme (CUSP) toolkit can better facilitate this?

Methods

Case-notes for all patients admitted under Trauma and Orthopaedics on three separate non-consecutive days during a two-week period were scrutinized, examining them for the presence of CUSP toolkits and whether these were adequately completed.

Results

71 case-notes containing 291 CUSP toolkits were analysed. 46.4% had a completed toolkit for everyday since admission; however for those that did not, over half (55.2%) did not have a senior review documented elsewhere for the missing days. Only 1.4% of case-notes had a full complement of up-to-date CUSP toolkits completed entirely correctly. For patients on Orthopaedic wards, most common errors were failure to document date and time (69.7% incorrect), ward and bed number (30.7% incorrect), patient alerts (70.7% incorrect) and overall compliance in documentation of required parameters such as MRSA status, investigations, observation and fluid charts (23% incorrect).

Conclusions

In conclusion, better education for clinical staff is needed to improve compliance both with daily senior review, CUSP toolkits and overall documentation to provide optimum patient care.

Acute correction of INR for patients requiring urgent orthopaedic trauma surgery – are we getting it right? Urgent orthopaedic trauma surgery are we getting it right

Alexandra Colby

University Hospital Aintree, United Kingdom

Background

Many orthopaedic patients admitted to hospital who require urgent surgery are also on Warfarin. Patients with an INR > 2 have an increased risk of bleeding complications during surgery; however delay to surgery due to a high INR has both clinical and financial implications. This audit aims to evaluate whether the appropriate management for correction of INR is employed as per local guidelines and, if not, whether this results in significant delay to operative treatment.

Methods

A retrospective and prospective audit was performed analysing all Orthopaedic trauma admissions admitted to University Hospital Aintree in a 5 month period. Only those solely on warfarin, who were not acutely bleeding and required urgent surgery in < 24 hours were included.

Results

A sample of 17 patients was obtained of which only 35.3% had correct INR reversal as per local guidelines. Errors that occurred included 81.1% not being given further Vitamin K at reassessment, 18.2% given too much Vitamin K, 9.1% given too little Vitamin K, 18.2% given Octaplex incorrectly and 9.1% not given Octaplex when indicated. Only 1 patient had a delay to their surgery directly resulting from incorrect INR reversal (total time to surgery being 33 hours 45 minutes).

Conclusion

In conclusion, better education for clinical staff on the local policy for INR reversal in patients requiring urgent orthopaedic surgery is needed. Local policy guidelines have been redesigned in light of this audit and a completion audit cycle is currently being performed, the results of which will be available at presentation.

Cartilage and ligament injury after patellar dislocation – diagnostics and treatment

Andrej Radić, Eduard Rod, Damir Hudetz, Igor Borić, Ira Skok

St. Catherine Hospital

Introduction

Even today, in many Croatian hospitals MRI scan is not standard diagnostic procedure after patellar dislocation. On rare occasions, small patellar flake fractures can be found on radiographs which indicate cartilage injury. Without MRI we can miss important accompanying cartilage injuries, usually located at medial patellar facet and lateral femoral condyle. Therefore, every patient with patellar dislocation should have an MRI. Beside cartilage injuries, bone edema as well as medial patellofemoral ligament rupture can be found on MRI scans. These injuries with verified loose bodies will be indication for surgical treatment. Materials and methods Our patient was 13 years old girl that had her first time patellar dislocation during jazz dance. On MRI scans we found osteochondral fracture of the lower part of the medial patellar facet, two free osteochondral fragments, incomplete rupture of the medial patellar retinaculum as well as bone contusion edema at lateral part of lateral femoral condyle. Damaged cartilage at medial facet patella was arthroscopically debrided and microfractures were performed. Subluxated patella was repositioned over femoral trochlea using Yamamoto procedure. Results After 4 months, on follow up MRI, cartilage patellar defect was replaced with fibrocartilage scar tissue and patella was over trochlea. Clinically apprehension test was negative. Discussion Not every patellar dislocation needs operative treatment. After MRI and analysis of injured elements we can decide about further treatment. In this case, indication was cartilage injury, medial patellofemoral ligament injury, loose body and lateral subluxation of patella over femoral trochlea. Take - home message Careful analysis of MRI scan and evaluation of injured knee elements can facilitate decision making for operative treatment.

MPFL reconstruction with gracilis muscle tendon

Jovicic Z, Cvijic P, Manojlovic S, Bijeljic S, Palija S, Kuzmanovic B, Miholjcic B, Jovanovic M

Institute of Orthopaedics, physical medicine and rehabilitation Dr. Miroslav Zotović, BiH

Introduction

The primary role of the medial patellofemoral ligament (MPFL) is in preventing of lateral dislocation of the patella. Indication for operative treatment is recurrent lateral patellar instability. Contraindications are skeletal immaturity, Q angle greater than 20°, patella alta and significant arthrosis.

Objectives

Monitoring of patients treated surgically after the reconstruction of the MPFL with m. gracilis tendon, and their return to normal activities Materials and methods: The analysis included 46 patients (17 men and 29 women) operated in our hospital from June 2011.–December 2014. Reconstruction of the MPFL was performed with m. gracilis tendon with arthroscopic control in all patients. Parameters were obtained with clinical examination before and after surgery.

Results

The average follow-up period was 12.6 months (10 to 24 months). Apprehension test was positive and MRI indicated a lesion MPFL in all patients preoperatively. Apprehension test was negative and there was no clinical hypermobility of the patella in all patients postoperatively. We had one complication due to graft tightened too much that we have solved with relaxation of the part of graft fibers. This complication was clinically manifested by pain in the operated knee during flexion.

Conclusions

Reconstruction of the MPFL with m. gracilis tendon is not a complicated procedure and has a low complication rate. Minimum of implanted material is necessary for this procedure. The most important moments of the operation are the positioning of the graft in isometric points and the determination of graft tension.

A rare clinical entity - unrecognized posterior dislocation of the shoulder: a case report

Željko Jeleč, Ana Vuković Pirkl, Zdenko Beck, Gordana Sunko, Biserka Mileusnić-Jovanović, Gordan Rujevčan, Dubravko Jančić, Tomislav Gjurašin

General Hospital Dr. Ivo Pedišić Sisak

Posterior dislocation of the shoulder is a rare clinical and radiological entity. It accounts for less than 2 % of all dislocations of the shoulder. Method of treatment is determined by the size of the defect and the duration of dislocation. We present a case of a 66-year old woman with unrecognized posterior dislocation of the shoulder after falling from a bicycle. Following a CT scan we performed an open reposition of the humeroscapular joint and transposition of the upper third of subscapularis tendon into the humeral head defect. Ten months after surgery we found a good range of motion and the patient is very satisfied with the final result of the surgical treatment. The treatment of unrecognized chronic posterior dislocation of the shoulder is difficult. We believe that after detailed clinical examination, a good diagnosis and accurate assessment of the defect on the articular surface of the humeral head and the correct selection of treatment methods, posterior shoulder dislocation can be treated successfully, not only in highly specialized orthopaedic clinics, but also in regional and general hospitals.

Isolated traumatic dislocation of the fifth carpometacarpal joint: a case report

Igor Krpan, Tadija Petrović, Maja Đinkić

KBC "Sestre milosrdnice", Croatia

Isolated ulnar dislocation of the fifth carpometacarpal joint without associated fractures is a rare injury and the scientific literature contains very few published reports of cases of this particular injury. The injury is frequently overlooked in the routine diagnostic X-ray. Timely and accurate diagnosis of the injury is crucial as the treatment is usually surgical. In this report, we present a case of isolated ulnar dislocation of the fifth carpometacarpal joint, secondary to an injury by a baseball bat, treated by reposition and percutaneous K-wire fixation which resulted in a satisfactory radiographic and clinical outcome.

Arthroscopically Assisted Double-Button Acromioclavicular Reduction, How Far Can It Resist?

Miguel Frias, Márcio Oliveira, Ricardo Pereira, Tiago Torres, Pedro Lourenço

Centro Hospitalar de Vila Nova de Gaia Espinho, Portugal

The acromioclavicular (AC) joint dislocation usually occurs in young adults as a result of direct high-energy trauma. There are several surgical options available, and the techniques associated with arthroscopically-assisted mooring systems with double cortical button is now an option with overlapping results to techniques traditionally used, with rare complications described. However, and despite its increasing use, its risks and benefits remain poorly clear. Adult male, 49 years old, physical education teacher, bicycle accident, appeared to the emergency department and was diagnosed with a left AC dislocation grade III (Rockwood classification). Taking into account the patient's activity it was decided to surgical reduction and fixation assisted by arthroscopy with dual button cortical system. At 7 months postoperatively he suffers another fall with fracture of the middle third of the same clavicle, group I according to Allman Classification. It was decided to treat nonoperatively with a figure-of-eight bandage for 4 weeks. At 6 months postoperatively had a Constant Index of 78, having returned to his previous active sporting life, with no surgical complications observed. After 4 months of the clavicle fracture, and 1 year after the initial AC dislocation, returned to the previous labor activity presenting a Constant Score of 82. After 2 years of follow-up the patient presented with a Constant Score of 94 and he was free of shoulder pain with no restriction on his work and sport activity. No loss of radiograph reduction or AC joint degeneration was observed. Currently, no clinical midterm results have been reported on arthroscopically assisted reduction of the acutely dislocated AC joint using double-button devices for fixation. However, it appears to be a reliable and robust system, with a favorable recovery and return to previous activities.

Clavicle fractures surgical management - a retrospective clinical study

Miguel Frias, Ricardo Santos Pereira, Filipe Lima Santos, Tiago Pinheiro Torres, André Sarmento

Centro Hospitalar de Vila Nova de Gaia Espinho, Portugal

The clavicle fractures account for about 2.5% of all fractures, its higher prevalence affects young male, and is usually associated with high kinetic trauma. The middle third fractures are the most common, followed by fractures of the distal third and, rarely observed, fractures of the medial third. In most cases the treatment is conservative. However, more recently the evidence suggests that conservative treatment, especially the middle third fractures with deviation or shortening, is not as favorable as previously thought, with rates of nonunion reaching 15% in some studies. Were studied retrospectively 36 patients from January 2009 to December 2013. The inclusion factors selected were a deviation or initial shortening greater than 20 mm or skin tenting undergoing primary fixation with plate. Of the total patients evaluated, most were male with a mean age of 38 years and a mean follow-up of 11 months. Of the aforementioned complications, it was found only one case of superficial infection of the surgical wound and four cases of material extraction due to a prominence of the plate. The mean Constant index was 85 points, with almost all of the patients satisfied with the results. Despite conservative treatment is still considered the treatment of choice, in appropriately selected individuals, surgical treatment may be safe and effective bringing with it favorable results.

Management of reversed bennett's fracture in university hospital centre „Sestre milosrdnice“ in time period from 2012 - 2014

Stjepan Ćurić, Petra Jurina, Mario Malović

University Hospital Centre "Sestre Milosrdnice"

Objectives

Dislocation fracture of the fifth metacarpal base is pathologically and radiographically similar to the Bennett's fracture of the thumb metacarpal, and it is known as a „Reversed Bennett“ or „Baby Bennett“. The aim of this study is to show our experiences with mentioned fractures and benefits of its surgical treatment.

Patients and methods

A retrospective study was conducted, consisting of 78 patients, 21 to 75 years of age, with intra-articular fracture of the fifth metacarpal base, between January 2012 and December 2014. 61 patients were conservatively treated with casting, while other 17 patients had indication for surgical treatment. Indication was set according to 5 degrees of angulation and 1-2 millimeters of dislocation. Surgical treatment included percutaneous K wiring (9), twin fix/mini Herbert screw (6) and AO screw (2).

Results

After a mean of 12 months, we reviewed 17 patients that were surgically treated. The overall results were satisfactory with all applied methods, since all patients had improved range of motions of metacarpophalangeal flexion and extension and showed significantly powerful grip. However, the best results reviewing postoperative abduction were noted with applied twin fix/mini Herbert screw.

Conclusion

Open reduction and internal fixation with K wires, twin fix/mini Herbert screw and AO screw are all good techniques for surgical treatment of intra-articular fifth base metacarpal fracture, when right indication is set. However, the debate between closed reduction with casting versus operative management continues. Until a large-scale study comparing these two treatment options is completed, a surgeon's personal preference will continue to be acceptable as a standard of care.

Operative fixation of the isolated 4th metacarpal shaft fracture in recreation athletes

Petra Jurina, Mario Malović

Clinic for traumatology, University Hospital Center Sestre milosrdnice Zagreb

Introduction

Metacarpal fractures are common injuries, which appear in general population, as well as in the population of athletes. The aim of this study was to present a series of isolated 4th metacarpal shaft fractures exclusively in the population of recreation athletes, which were surgically treated and time-frame of their return to every day activities according to applied measures of treatment and postoperative care.

Materials and Methods

A retrospective single center study was conducted, including patients with isolated 4th metacarpal shaft fracture, which occurred during the two-year period, from January 2010 to December 2011. Inclusion criteria were: isolated dislocated 4th metacarpal shaft fracture, acute injury with onset no longer than 10 days before admitting to hospital, recreation athletes and participants younger than 40 years of age. All patients were surgically treated. The choice of internal fixation was made between low profile plates and fixation with 2 or 3 mini-screws. All patients followed standard rehabilitation protocol with early mobilization. Results: The mean follow-up of the patients was 12 months. After completed physical therapy, range of motions of metacarpophalangeal flexion and extension was increased and early return to normal daily activities and sports practice was allowed. No complications were noted, all fractures healed, without any signs of infection, non- or malunion.

Conclusion

Surgical treatment of the 4th metacarpal shaft fracture with low profile plates and mini-screws is a good technique that represents rigid fixation and provides fast recovery to pre-injury range of movements. Quality of life is enhanced, due to fast recovery and return to normal daily, as well as sports activities. Such treatment indicates profitability, hence to a one-day surgery, decreasing treatment costs and resulting in high beneficial aspects for patients.

Parsonage–Turner syndrome after Anterior Shoulder Dislocation

Ricardo Santos Pereira; Tiago Pinheiro Torres; Miguel Frias; Fabiola Ferreira; David Sá

Centro Hospitalar de Vila Nova de Gaia Espinho, Portugal

Parsonage – Turner syndrome is an extremely rare and serious disorder of unknown etiology with asymmetric inflammatory involvement of the brachial plexus. Although the etiology of the syndrome is still unclear it is reported in various clinical situations including postoperatively, postinfectious, posttraumatic, and postvaccination. We aim to present a case of a 65 year old female woman who presented to our emergency room with an isolated anterior dislocation of her right shoulder after a simple fall. After adequate reduction she was immobilized with a Velpeau-type dressing and discharged with no neurovascular deficits. The patient was reevaluated on an outpatient basis three weeks after the fall and presented with drop arm and complete inability to mobilize the right upper limb. She also made reference to progressive shoulder and arm pain that had initiated a few days after the initial injury and resolved spontaneously by then. Detailed neurologic examination revealed severe right brachial plexus injury with motor weakness and abolished reflexes in the muscles innervated by C5 C6 and C7 right nerve roots. There was also hypoesthesia in the C5 C6 C7 and T1 dermatomes. Electromyography revealed severe axonal lesion with active denervation of all the upper limb muscles compatible with brachial plexus injury or severe neuropraxis due to entrapment. Brachial plexus MRI showed intramuscular edema and atrophy of the supraspinus, infraspinus, teres minor and deltoid with perineural edema of the brachial plexus. There were no indirect signs of avulsion of the nerve roots or any image of entrapment or compression of the brachial plexus from the cervical spine to the axillary region – these alterations were concluded to be a consequence of Parsonage-Turner type neuritis. To our knowledge this is the first case of Parsonage-Turner Syndrome described as a complication of shoulder dislocation.

Intramedullary fixation with a third generation nail versus the sliding hip screw for trochanteric hip fractures_ a randomised trial of 850 patients.

Daniele Pili

GVM Mangioni Hospital Lecco, Italy

The Sliding Hip Screw (SHS) is currently the treatment of choice for all trochanteric hip fractures An alternative treatment is the short femoral nail Earlier designs of these nails were associated with an increased fracture healing complication rate in comparison to the sliding hip screw The new designs of nails (third generation nails) may however be as good as or even superior to sliding hip screw fixation We conducted a large randomised trial to compare the Targon Proximal Femoral (PF) Nail (patients) and latterly the Targon Proximal Femoral Telescrew (PFT) Nail (patients) with the Sliding Hip Screw Patients with trochanteric hip fractures as per the AO classification (A1 - A3) were randomised to either implant All surgery was supervised by one surgeon All patients were followed up for a minimum of one year months by a blinded observer The mean age was years (range to years) , % were male Length of surgery was slightly increased for the PF nail but not the PFT nail in comparison to the sliding hip screw Intra - operative complications were more common with the PF nail but not the PFT in comparison to the sliding hip screw There was no difference in blood transfusion requirement between groups Postoperatively there was no difference in the occurrence of medical complications or mortality The re - operation rate was slightly higher for the SHS but the difference was not statistically significant At follow - up no difference in pain scores was seen but there was a tendency to improved mobility in the nailed group Results were split for the three main fracture types (A1 - stable A2 - unstable A3 - reversed) and these showed greater benefit for the

Cemented versus uncemented hemiarthroplasties for intracapsular hip fractures

Daniele Pili

GVM Mangioni Hospital Lecco, Italy

Controversy exists as to whether to use a cemented or uncemented arthroplasty for the treatment of an intracapsular hip fracture Potential problems of cement are that it achieves a better functioning arthroplasty with a lower risk of later revision surgery To review all randomised trials to date that have compared cemented with uncemented prosthesis for intracapsular hip fractures An extensive literature search was undertaken using the search strategy of the Cochrane trials group Over identified references were reviewed from all searchable databases trials involving patients were identified and included in the analysis Cementing the implant in place was found to increase the length of surgery by on average minutes (% confidence intervals [CI] to minutes) , but no significant difference in transfusion requirements (relative risk % CI -) . Operative fracture of the femur and later fracture of the femur were both increased for the cemented prosthesis (% versus % and % versus %) . There was tendency to a greater need to secondary surgery for the uncemented prosthesis (% versus %) . There was a tendency to a lower mortality for the cemented prosthesis although the difference was not quite statistically significant (odd ratio % CI -) . Residual pain was consistently reported as being less for the cemented prosthesis (relative risk % CI -) and regain of mobility tended to be superior for the cemented prosthesis These differences in need for revision surgery function and pain were less prevalent for the modern designs of prosthesis There was no difference in the other outcomes of dislocation wound infection medical complications or length of hospital

Femoral neck collapse after internal fixation of intracapsular hip fractures

Daniele Pili

GVM Mangioni Hospital Lecco, Italy

Excessive collapse of the femoral neck after internal fixation of an intracapsular hip fracture has been thought to lead to residual pain or impaired hip function. This theory remains to be proved in clinical practice. The new Targon FN hip screw has been designed for the internal fixation of intracapsular hip fractures to allow for limited collapse to occur along the line of the femoral neck with multiple telescoping lag screws, whilst resisting varus deformity occurring at the fracture site. This enables femoral neck collapse to be measured on follow-up radiographs. 328 patients with an intracapsular hip fracture were treated by internal fixation with the Targon FN screw and plate fixation. Collapse of the femoral neck at the fracture site was calculated by measuring the amount of slide that occurred in the sliding femoral neck screws. Femoral neck collapse was significantly increased for displaced fractures in comparison to undisplaced fractures (mean collapse 6.0mm versus 9.5mm). Increased collapse was also found with increasing age. Increased collapse was also associated with an increased occurrence of fracture healing complications (non-union, avascular necrosis) as shown in the table. For those patients in whom the fracture healed without complications, those patients with increasing collapse were more likely to report a reduced mobility. In summary, collapse of the femoral neck after an intracapsular hip fracture has a detrimental effect on outcome. Future research looking at ways to prevent this collapse is indicated.

Subtrochanteric fracture in pediatric age

Tiago Rebelo

Centro Hospitalar Tondela Viseu, Portugal

Introduction

Subtrochanteric fractures in children are rare and generally result from severe trauma. There are few cases described, as well as classification systems. There is no consensus on the best therapeutic strategy.

Material and Methods

The authors describe a case of a 9 years patient, male, victim of a hit by a car. In the Emergency room was performed initial clinical and imagiologic evaluation, and was diagnosed a subtrochanteric fracture of the right femur. The patient was operated in the same day, performed open reduction and internal fixation with plate and screws.

Results

The surgical result was good and it was achieved an excellent anatomical reduction. The patient initiated rehabilitation in next day after surgery and had a short hospital stay. At 6 months the patient shows a good recovery, with no complaints or functional limitation.

Discussion

There are few references in medical literature about this kind of lesions in children and the respective treatment. Taking that into account, the authors opted for open reduction and internal fixation with a plate and screws, with the careful not to cross the physis.

Take Home Message: The authors consider that this case was a success, using an uncommon treatment option with fast full recovery of the patient.

“DORGAN” Cross Pinning Of Supracondylar Humeral Fractures From A Lateral Approach

Siniša Dučić

University Children's Hospital, Serbia

Introduction

Supracondylar fractures of humerus are one of the most common injuries of the locomotor system in children, usually caused by the fall on outstretched hand.

Objectives

The purpose of this study was to evaluate the efficacy of percutaneous lateral cross-wiring technique for the treatment of completely displaced extension type supracondylar fractures of the humerus in children.

Methods

We prospectively included 40 consecutive patients with Gartland type II or III extension supracondylar humeral fractures referred to University Children's Hospital, during two-year period. The study included 27 boys and 13 girls aged 1,5-11,4 years (mean 6,5±2). At initial presentation 60% (n=24) fractures were classified as Gartland type II and 40% (n=16) as Gartland type III. All patients were treated with percutaneous fixation, lateral configuration of crossing wires. Results: The average time from the elbow fracture to clinical evaluation was 11.2±2.3 months. According to Flynn classification we achieved excellent result in 32 patients (80%), good in other 6 (15%) and poor in 2 cases (5%).

Conclusions

The use of percutaneous lateral cross-wiring technique is a safe and effective method with good functional outcome for the most unstable pediatric supracondylar humeral fractures. There were no iatrogenic ulnar nerve injuries, and two lateral pins provide adequate stability. Keywords: Supracondylar Humeral Fracture, Children, Lateral Pinning, Cross-Wiring.

Open reduction using ferguson medial approach as a treatment of choice for developmental dysplasia of the hip after failed conservative therapy

Siniša Dučić

University Children's Hospital, Serbia

Keywords

DDH, Open Reduction, Medial Approach

Purpose

The aim of our study is to evaluate results of open reduction of dislocated hip disorder using medial approach described by Ferguson. Methods: Between January 1999 and December 2005, 40 patients, aged 3,5 to 13,5 months (mean 8,6 months) underwent surgery due to developmental dysplasia of the hip using medial approach. There were 35 girls and 5 boys. Indication was previous failed conservative treatment (the Pavlik harness, abduction orthosis, traction, closed reduction and casting). Surgery was performed bilaterally in 3 patients. Postoperative follow-up included clinical examination, ultrasound scan and radiography. Results were evaluated using plain radiography acetabular index, center-edge angle as well as avascular necrosis by Ogden-Bucholz's. Results: Follow up was from 9 months to 6,5 years (mean 3,7 years). In 29 patients (72,5%) satisfactory reposition of the femoral head with normal acetabular index was achieved. Avascular necrosis of the femoral head developed in 6 patients (15%). In 11 patients (27,5%) Salter innominate and femoral derotation osteotomies were done, due to either relaxation (5 patients) or persistent acetabular dysplasia (6 patients).

Conclusions

Open reduction using medial approach by Ferguson is the treatment of choice in infants with typical perinatal dislocation of the hip, when the reduction of the femoral head was not achieved or failed by conservative treatment. Significance: This technique make it possible to achieve reduction of the femoral head in optimal age.

Minimal invasive surgery in treatment of flexible flatfoot in children

Bojan Bukva

University Children's Hospital, Serbia

Aim of this study is to evaluate the results in treatment of the flexible flatfoot in children using the technique of an extraarticular arthrodesis with the cannulated screw after failed conservative treatment. Method: Thirty feet in 17 children were included in this study during 6 years period. The average age was 10.5 years (8-15). There were 9 girls and 8 boys. We performed the same technique for each patient under the X ray fluoroscopy. The radiographic parameters were investigated before and after the surgical treatment. The talo-calcaneal (TC), talo-navicular (TN), talo-first metatarsal bone (T1MT) and calcaneal pitch (CP) angle were measured, in anteroposterior and (or) profile view. We compared the result before and after the surgery. Results: After the surgical treatment the radiographic parameters were not significantly changed but the clinical parameters were significantly improved. A degree of extension and eversion of the foot were remarkably reduced without disturbing other motions in talocrural and subtalar joint. Conclusion: Extraarticular arthrodesis using cannulated screw as a method of minimal invasive surgery represents a method of choice in treatment flexible flatfoot in children. Key words: flexible flatfoot, extraarticular arthrodesis, children

Combination of intramedullary alignment and Ilizarov external fixator in treatment of leg length discrepancies in children

Bojan Bukva

University Children's Hospital, Serbia

Background

The purpose of this study was to evaluate the influence of the intramedullary alignment with Kirschner (K) or Titanium Elastic (TE) wires combined with an Ilizarov external fixator (IEF) on the healing index lengthening index duration of hospital treatment and complications in congenital and acquired leg discrepancy.

Methods

This study included paediatric patients aged - years during years period We compare the healing index (HI), lengthening index (LI), duration of hospital treatment and complications between two groups of children. The first group of children undergoing limb lengthening by the IEF alone (group I). The other group (group II) was treated with the combination of the IEF and intramedullary stabilization using two K-wires or TE-wires Also we compare all of following parameters depending of the type of intramedullary alignment (K or TE wires).

Results

We found significant differences between Group I and Group II in the duration of external fixator application ($p < .$), HI ($p < .$) and duration of hospitalization ($p < .$). Concerning leg length inequality (LLI) and LI we found no significant differences between two groups of patients Also we found no significant differences in complication occurrence and etiology of LLI (congenital or acquired) between two groups of patients Depending of the type of intramedullary alignment we found less complications and shorter period of intrahospital treatment in patients treated using in combination of IEF and TE wires.

Conclusion

The intramedullary alignment has multiple advantages as a method of treatment of the limb discrepancy The major effect of the application of the combination of external circular fixation and intramedullary alignment is significant decrease of external osteosynthesis duration and healing process.

Imaging in Congenital Hip Dysplasia

Patricia Almela

Frimley Park Hospital, United Kingdom

Introduction

Developmental dysplasia of the hip (DDH) is a significant cause of disability in children. Ultrasonography (US) is the preferred modality for evaluating the hip in aged 6 months or younger. Graf angles represent the osseous coverage of the femoral head and its measurement facilitates grading of the condition. Plain pelvic radiographs are the primary imaging modality at 4-6 months after the femoral head begins to ossify. Objectives: Evaluate the standard of care of an Orthopaedic department in a District General Hospital in diagnosis and management of children DDH using combined radiological modalities.

Methods

A literature review regarding diagnosis and management of DDH was performed. All DDH patients referred to a District General Hospital, during the period 2005-2010 were reviewed and analysed regarding: demographics, age at referral and discharge, and radiology reports.

Results

113 patients (16 males, 97 females) were followed up, 76% of the cases were unilateral and 34% bilateral. Mean age of first scan was 3 months and follow-up average was 1 year and 3 months. 80% patients were discharged following a report establishing no joint abnormality and 9% were discharged with a minimally shallow acetabulum unilaterally. The mean number of scans for each patient was 5. 13% presented with DDH over 4 months of age and 7.5% over 1 year of age. 11% assessed with plain X-ray. 47% of patients had Graf angles calculated and documented in one or more US reports.

Conclusions

There is a need to establish an agreed imaging pathway for DDH that accurately monitors progression of the condition. The absence of a guideline produces inconsistency in follow up and potentially unnecessary treatment.

Extra articular hip impingement after rectus femoris muscle avulsion

Ribičić Tomislav, Šimić Marijana, Vlaić Josip, Žutelija Fattorini Matija

Children's Hospital Zagreb, Croatia

The anterior inferior iliac spine avulsion fracture occurs by the pull of the rectus femoris muscle. An apophyseal avulsion injury is seen most often in adolescents during sports activity involving kicking, due to eccentric contraction of the rectus femoris as hip extends and knee is flexed which causes avulsion of its anatomic origin of the pelvis. In some instances exostosis formation after an avulsion fracture of the anterior inferior iliac spine is observed and it can be quite extensive. Treatment of such type of impingement is open or arthroscopic decompression. We present two cases of teenage boys with a hip impingement due to rectus femoris muscle avulsion during sports activity. A fourteen-year-old boy developed complaints of pain and swelling in projection of the left anterior superior iliac spine. Few months later he noticed a firm bump on the same place. Clinical investigation showed significant flexion and internal rotation deficit of the left hip. The CT showed a large bony exostosis measuring 5x3,5cm arising from anterior inferior iliac spine towards the hip joint. An exostosis ablation was performed with the rectus femoris muscle origin transosseal reconstruction. One year later the boy developed the same symptoms and a new exostosis was found on the same place. There wasn't history of a new trauma. Another ablation was performed and the muscle origin was attached to the tensor fasciae latae muscle rather than another rectus femoris muscle origin reconstruction. After the second operation the boy had no symptoms. A seventeen-year-old boy had the similar problems on the right side. Simple exostosis ablation was performed and the boy was symptoms free.

Operative solutions for troublesome tumor localisations in children and adolescents

Tomislav Ribičić, Davor Bojić, Marijana Šimić, Robert Kolundžić

Children's Hospital Zagreb Zagreb, Croatia

For the last three years in the department of pediatric orthopedics of Children's hospital Zagreb we have performed complicated operative procedures treating malignant skeletal tumors in children and adolescents. The aim of this work is to show our experience in solving difficult problems of reconstruction after resection of a tumor in troublesome localization. We operated five teenage boys with diagnosis of pelvic Ewing sarcoma and one boy with the distal humeral osteosarcoma. Pelvic "en bloc" resections were followed by either 3D custom made implant or 3D custom made bone cement spacer and total hip arthroplasty. A custom made elbow endoprosthesis was built in after "en bloc" resection of the osteosarcoma of the distal humerus. Special problem is a reconstruction of the upper extremity in small children since the metal implant is too heavy for them. A resected part of the proximal humerus in a 4-year-old boy was temporary replaced by a bone cement spacer, and the arm function is surprisingly good. However the results mostly depend on tumor disease biology. Metal implants enable good reconstruction and extremity function unlike most of the cement spacers which primary serve temporary as space keepers until the metal implant is built in.

Our experience in usage of lcp pediatric hip plate for varus femoral corrective osteotomy

Davor Bojić, Tomislav Ribičić, Marijana Šimić, Robert Kolundžić

Children's Hospital Zagreb Zagreb, Croatia

There are many indications in pediatric orthopedics for performing a proximal femur varus osteotomy. The aim of this report is to show our experiences in usage of the LCP Pediatric Hip Plate for various indications requiring a femoral varus osteotomy. Last year we operated 10 children, 7 girls and 3 boys, aged from 3 to 14 using different sizes of LCP Pediatric Hip Plate. Indications were Legg-Calve-Perthes disease, sequels of septic arthritis and valgus deformity due to cerebral palsy and developmental hip disorder. The operative procedures took from 45 to 90 minutes, they were performed in general anesthesia and we had no complications. Our short experience in using LCP Pediatric Hip Plate is positive. The plate enables very good correction control and stability with less technical problems in comparison to the blade plate.

Epithelioid sarcoma rare soft tissue tumor presenting as finger wound that doesn't heal

Marijana Šimić, Josip Vlaić, Ida Matić; Davor Bojić

Children's Hospital Zagreb Zagreb, Croatia

Epithelioid sarcoma is a rare soft tissue sarcoma in young adults, mostly men, involving the upper extremities 60% of the time and it is often confused with a variety of malignant and benign conditions. It most frequently affects hands and forearms followed by distal lower extremities and proximal upper extremities. Most tumors present as firm-to-hard palpable masses, either in the deep soft tissue or in the dermis. Often the superficial lesions will ulcerate, causing a mistaken diagnosis of a poorly healing traumatic wound or wart. It has a tendency for lymph node metastasis. Five year survival and ten year survival rate for patients with epithelioid sarcoma are approximately 50-70% and 42-55% respectively. Gender, site, age of diagnosis, tumor size and microscopic pathology have been shown to affect prognosis. We present a rare case of the epithelioid sarcoma of the index finger in a thirteen-year-old girl. The sarcoma presented first as an ulceration of the finger tip and was treated as an infection. Otherwise the girl was healthy but the wound didn't heal so the sample for histopathology was taken, and the diagnosis was fibrous histiocytoma. The ulcer was progressing and the amputation of the distal phalanx was performed. Histopathology diagnosis was epithelioid sarcoma. The girl was then referred to our hospital for chemotherapy and was well for about a year. After that time, the same finger became painful, swollen with a new ulceration. Axillar lymph nodes on the same side were enlarged so the fine needle aspiration was performed for the cytology which found the cells of the epithelioid sarcoma in the specimen. We exarticulated the finger in the metacarpophalangeal joint, after which followed a chemotherapy.

Distal phalanx of the finger unusual localisation of the osteoid osteoma

Šimić Marijana, Vrdoljak Ozren, Miličić Gordana, Bojić Davor

Children's Hospital Zagreb Zagreb, Croatia

Osteoid osteomas of the distal phalanx of fingers are uncommon so the diagnosis is often delayed for several months to years. An eleven-year-old girl has complained of an occasional pain of the fifth finger tip of the hand for the last three years. The pain was more expressed at night and on direct palpation, without relief on ibuprofen. There was no history of trauma and infection. The nail surface was enlarged, without other changes. Radiographs were normal, MR investigation showed only soft tissue edema so she was treated with local corticosteroid injections and indomethacin tablets by a rheumatologist. Still there wasn't improvement about the symptoms, moreover, the nail seemed to be even more enlarged so she was referred to out hospital. We arranged a new MR which showed three millimeter oval structure on the dorsal aspect of the distal phalanx. We removed it and sent it to a histopathology analysis, the diagnosis was osteoid osteoma. After the operation, the girl was finally pain free. A better awareness of this tumor may prevent unwanted delays in diagnosis.

Decompression coupled with interspinous process device for degenerative lumbar spinal stenosis

Nino Mirnik, Samo K. Fokter

General Hospital Celje, Slovenia

Purpose

This study prospectively analyzed the success rates of DLSS patients treated with decompression and implantation of a soft IPD at one or two levels. We compared the results with a historic group of patients treated with traditional surgical decompression with or without PL fusion at one or two levels. Methods: In the DIAM group outcomes were measured with the Zurich Claudication Questionnaire, Oswestry Disability Index (ODI) and the Short Form Health Survey (SF-36) completed preoperatively and at 1, 3, 6, and 12 months postoperatively. In the historic group outcomes were measured with the ZCQ preoperatively and at 1, 3, 6, and 12 months. The two groups were compared in ZCQ results preoperatively and at 1, 3, 6, and 12 months. Results: The operating time was (\pm) minutes in the DIAM and (\pm) minutes in historic group. The blood loss was (\pm) ml in the DIAM and (\pm) ml in the historic group. The hospital stay was (\pm) days in the DIAM and (\pm) days in the historic group. The narcotic use was (\pm) days in the DIAM and (\pm) days in the historic group. In overall ZCQ results % () in the DIAM group and % () of the patients in the historic group were considered to be clinically successful. In the DIAM group the ODI and SF-36 results significantly improved on follow-up at 1, 3, 6, and 12 months and continued to improve to a 2-year observation period. Conclusion: Overall the adjunct of a soft IPD to the interspinous decompression has not provided patients with better results in comparison to traditional surgical methods. The main advantages of interspinous decompression coupled with soft IPD implantation for DLSS are less operating time, less blood loss, and less narcotic use, which may make this surgical method potentially usable in older, debilitating patients.



Nurse's day



Zdravstvena njega bolesnika prije i nakon rekonstrukcijskih zahvata

Mirjana Parać, Nataša Šitum

Institut : Klinika za plastičnu, rekonstrukcijsku i estetsku kirurgiju, KB "Dubrava", Zagreb

Rana je prekid anatomske i funkcionalne kontinuiteta tkiva ili organa, dijelimo ih na akutne i kronične. Akutna je rana ona kod koje nije prošlo više od 12 sati od njenog nastanka. Kronična rana je rana koja ne cijeli u očekivanom razdoblju od 4-6 tjedana od njenog nastanka. Ona predstavlja veliki problem za bolesnika, jer značajno umanjuje kvalitetu njegovog života, ali i veliki socioekonomski problem u zdravstvu.

Uloga medicinske sestre kao člana tima u liječenju rana je značajna. Ona planira i provodi pripremu bolesnika za operacijske zahvate te preuzima brigu o cjelokupnoj postoperacijskoj njezi. Medicinska sestra mora biti i psiholog, jer sam način pristupanja, toplina i osjećajnost će donekle ublažiti brigu i strah kod bolesnika.

Nakon debridmana, rana može biti rekonstruirana slobodnim kožnim transplantatom (SKT) ili režnjem. Ukoliko rana nakon debridmana nije pogodna za pokrivanje, nastavljamo redovni prevoj na klasičan način, jednom od modernih obloga ili metodom terapije negativnim tlakom (npr.V.A.C.). Rana je pogodna za pokrivanje kada je bez znakova infekcije, bris je sterilan i površina ima čiste granulacije. Medicinske sestre su educirane za primjenu terapije negativnim tlakom ili postavljanje SKT-a otvorenom ili zatvorenom metodom.

Kod defekta pokrivenim režnjem sestra prati određene parametre vitalnosti: boju, kapilarno punjenje i toplinu. Ukoliko primijeti odstupanja mora obavijestiti operatera kako bi se napravila pravodobna revizija.

Kvalitetnim provođenjem zdravstvene njege medicinska sestra doprinosi bržem cijeljenju rana i povećanju kvalitete života bolesnika.



Primjena suvremenih obloga u kliničkoj praksi kod opeklini i traumatološkog bolesnika

Martina Marić, Valentina Štrbac

KBC „Sestre Milosrdnice“ Klinika za traumatologiju

Akutne i kronične inficirane rane zbog sporog cijeljenja i komplikacija predstavljaju velik financijski problem. Tupferi i zavoji danas imaju samo povijesno značenje.

Danas postoje obloge za rane koje podržavaju osnovne fiziološke uvjete za cijeljenje rane. Proizvodi za njegu rane bazirani su na naprednoj teoriji vlažnog cijeljenja za koje je dokazano da ubrzava cijeljenje rane, smanjuje rizik od infekcije te osigurava pacijentu atraumatski način prevoja. Kako odabrati određenu oblogu ostaje osnovno pitanje, no najvažniji je individualan pristup svakom pacijentu kako bi se postigli brži, bolji i kvalitetniji način liječenja.

Med. sestra zajedno s kirurgom bira oblogu na osnovi kliničkog iskustva.

Cilj rada je prikazati naša iskustva na Klinici i razmjena mišljenja s kolegicama istih ili sličnih slučajeva. Cijene suvremenih obloga su više u odnosu na klasične materijale ali su ukupni troškovi liječenja smanjeni.

U radu će biti prikaz slučaj pacijenta s opeklinama IIb - III stupnja, koji je liječen u periodu od dva mjeseca kombinirano nekrekotomijom i plastikom autotransplantata, te primjenom obloga s hidrofiber tehnologijom obogaćenom ionima srebra. Liječenje će biti prikazano po fazama cijeljenja uz fotografije.

Također će biti prikazan slučaj pacijenta s ranom kao posljedicom komplikacija dugotrajnog ležanja (Philadelphia ovratnik, kvadriplegija) za koju je primijenjena hidrokoloidna obloga. Faze cijeljenja rane će biti prikazane fotografijama.

Zbog raznovrsnosti rana te individualnog pristupa svakom pacijentu, očito je da samo jedna vrsta obloge za rane ne može zadovoljiti sve terapijske potrebe. Liječenje kronične rane zahtijeva multidisciplinarni angažman (kirurg, internist, mikrobiolog, medicinska sestra). Idealna i univerzalna obloga još uvijek ne postoji. Liječenje rana suvremenim oblogama skraćuje vrijeme zarastanja, smanjuje broj dolazaka pacijenta na

previjanje, a to podrazumijeva i manje angažiranje i opterećenje zdravstvenog osoblja. Istovremeno je značajno bolja kvaliteta života pacijenata, a ukupni troškovi liječenja rane su smanjeni. Sestre koje sudjeluju u procesu liječenja pacijenta sa kroničnim ranama moraju imati adekvatnu suvremenu teorijsku i praktičnu edukaciju.

Ključne riječi: medicinska sestra, pokrivala, obloge, JIL, opeklina

Zbrinjavanje rana primjenom sistema za negativni tlak

Željka Roje

Klinika za plastičnu, rekonstrukcijsku i estetsku kirurgiju, KB "Dubrava", Zagreb

Terapija negativnim tlakom (TNT) je neinvazivna metoda zbrinjavanja rana sa sistemom koji se temelji na distribuciji kontroliranog sub-atmosferskog tlaka na površinu rane. Vakuum metodom se potiče lokalna prokrvljenost i stvaranje granulacijskog tkiva uz smanjenje edema i bakterijske kolonizacije. Duljina hospitalizacije je kraća, a time i troškovi liječenja. Cilj TNT je postići potpuno zatvaranje rane rubnim cijeljenjem ili priprema adekvatne podloge za konačno kirurško zatvaranje. Dobri klinički rezultati potaknuli su široku upotrebu TNT u liječenju akutnih i kroničnih rana.

Predavanje prikazuje način korištenja sistema za TNT kod 9 kliničkih slučajeva na Klinici za plastičnu, rekonstrukcijsku i estetsku kirurgiju, Klinička bolnica Dubrava, Zagreb. Prikazani slučajevi uključuju zbrinjavanje: abdominalnog kompartment sindroma, nekrotizirajućeg fascitisa, dehiscence rana sternuma nakon kardiokirurških operacija, akutne traumatske inficirane rane potkoljenice nakon osteosinteze, dekubitusa sakralne regije, venskog ulkusa potkoljenice, dijabetičkog ulkusa stopala i fiksaciju slobodnog kožnog transplantata.

Terapija negativnim tlakom u zbrinjavanju navedenih rana služila je za pripremu rane za zatvaranje plastično-rekonstruktivnom kirurškom metodom. Rezultati pokazuju značajno poboljšanje cijeljenja rane uz redukciju veličine i mikrobiološke kontaminacije.

Kako procijeniti ranu i odrediti pravilan način previjanja

Željka Roje, Cecilija Rotim

Klinika za plastičnu, rekonstrukcijsku i estetsku kirurgiju, Klinička bolnica "Dubrava", Zagreb

Medicinska sestra se u svojoj praksi često susreće sa akutnim i kroničnim ranama koje zahtijevaju svakodnevno previjanje. Dugogodišnjim radom i znanjem gradi se iskustvo koje nam pomaže u odgovoru na pitanje: „Kako dobro procijeniti ozbiljnost rane i odrediti pravi način liječenja i previjanja?“. Danas je ponuda obloga izrazito široka te se pojačanim marketingom naglašavaju prednosti svake obloge što nam predstavlja veliki problem za odabir one prave koja odgovara našem pacijentu.

Stoga će tijekom ovog predavanja biti prikazani svi tipovi obloga koje postoje na tržištu i dati će se opis njihovih glavnih karakteristika. Kroz prikaz kliničkih slučajeva interaktivnim sudjelovanjem dobiti će se uvid u pravilni algoritam izbora obloge prema vrsti rane.

Način postupanja sa ranama, od metoda previjanja do obloga za pokrivanje određuje mogućnost infekcije rane. No pravilni odabir obloge pomaže u sigurnijem, kvalitetnijem i bržem cijeljenju.



Radionica: Sestrinska dokumentacija

Cecilija Rotim

KBC Sestre milosrdnice, Klinika za traumatologiju

Biljana Kurtović

KBC Sestre milosrdnice, Klinika za neurokirurgiju

Povijest dokumentiranja u sestinstvu seže daleko u povijest. Zapisi iz drevnog Egipta osim o veterinarskoj znanosti i kirurgiji sadrže opisane sestrske intervencije (postavljanje zavoja i hranjenje pacijenta s tetanusom).

Najveća pažnja primjeni sestrske dokumentacije posvećuje se uvođenjem procesa zdravstvene njege. Dokumentacija predstavlja vezu između svih faza procesa zdravstvene njege. U našoj zemlji nakon osnutka HKMS i donošenja Zakona o sestinstvu, MS imaju obavezu dokumentiranja. Izrađena je jedinstvena sestrska lista koja se može prilagoditi potrebama bolesnika.

Razlozi za postojanje sestrske dokumentacije i dokumentiranje su: profesionalna odgovornost, prava zaštita, standard sestrske prakse /zakonska osnova, toškovi u zdravstvu i menadžment i društvene promjene.

U RH je sestrska dokumentacija regulirana i zakonskim propisima. Pravilnikom o sestrskoj dokumentaciji u bolničkim zdravstvenim ustanovama (NN 79/11) propisani su obavezni dijelovi sestrske dokumentacije te izdane upute za njihovu primjenu.

Sestrska dokumentacija označava skup dokumenata koje MS ispunjava ili u koje zapisuje podatke o svojim postupcima tijekom cjelokupnog procesa skrbi za pojedinca, sa svrhom sustavnog praćenja stanja, planiranja, vrednovanja i kontrole učinjenoga. Sestrska dokumentacija mora biti dokaz provedene skrbi i odgovora na tu skrb te osigurati zapise o bolesnikovoj sigurnosti (procjena rizika, zaštita, uočavanje promjena, dokumentiranje incidenata i neželjenih događaja).

Uvođenje procesa zdravstvene njege i sestrske dokumentacije u svakodnevni rad medicinskih sestara i skrb za pacijenta predstavlja temelj

početka procesa kontinuirane evaluacije provedene skrbi i unaprjeđenja kvalitete. Ona mora opisivati i osigurati komunikaciju o bolesnikovu statusu među zdravstvenim profesionalcima i između smjena.

Dokumentiranje u sestrskoj praksi mora slijediti zbrinjavanje pacijenta od dolaska u bolnicu sve do otpusta kući, a potrebno je osigurati i kontinuitet skrbi nakon otpusta.

Ključne riječi: sestrska dokumentacija, medicinska sestra, razlozi postovanja sestrske dokumentacija, pravilno vođenje sestrske dokumentacije



Standardni operativni postupci (SOP) kod bolesnika s prijelomom kuka

Dragana Barukčić, Margareta Bajsic
Beljak

KBC „Sestre Milosrdnice“ Klinika za
traumatologiju

Prijelom kuka je velik zdravstveni i socijalni problem unutar nacionalnog zdravstvenog sustava. Standardni operativni postupci (SOP) su detaljno napisane upute kako bi se postigla ujednačenost za obavljanje određene funkcije pa tako i u segmentu pružanja ortopedsko-traumatološke zdravstvene zaštite.

SOP se provode na svim razinama, to podrazumijeva prijem bolesnika u hitnoj službi bolnice, preoperativnoj, anesteziološkoj, perioperativnoj i postoperativnoj skrbi te pripremi za otpust iz bolnice.

Pretpostavka je da bi uvođenje SOP-a kod bolesnika s prijelomom kuka u Kliniku za traumatologiju KBC „Sestre Milosrdnice“ doprinijelo mnogim poboljšanjima, kao što je brži, lakši i kvalitetniji oporavak bolesnika, bolja koordinacija između bolničkog tima i bolja briga o bolesniku nakon odlaska iz bolnice kao i smanjenje troškova.

Pri izradi SOP-a provedena je retrospektivna studija u Klinici. U studiji je uključeno 382 bolesnika od toga je 267 žena i 115 muškaraca prosječne životne dobi 74 godine (14-102 godine). Korištena je deskriptivna metoda obrade podataka, kao i međunarodna iskustva. Uzorak je prigodnog tipa te su ga činili svi bolesnici koji su boravili u Klinici od 1.1.2014. do 31.12.2014. god.

Potrebno je provoditi sestrinsku skrb po striktnim uputama SOP-a pri čemu ne smije biti razlike u kojoj se regiji, gradu ili bolnici obavljaju. Međutim s obzirom na opseg SOP-a trebali bi razlikovati nacionalnu razinu, regionalnu i gradsku. Uvjeti za razvoj SOP-a se baziraju na opsegu javno zdravstvenih djelatnosti, kliničkoj praksi i vještini, kao i na napretku medicinske tehnologije. Medicinska sestra je bitan čimbenik multidisciplinarnog tima u zbrinjavanju pacijenata s prijelomom kuka.

Ključne riječi: SOP, prijelom kuka, Klinika za traumatologiju, sestrinska skrb



„SOP“ – Standardizirani operativni postupci u ortopedsko – traumatološkoj operacijskoj Sali

Nevenka Lukavski, Koraljka Česi

KBC „Sestre Milosrdnice“ Klinika za traumatologiju

Standardizirani operativni postupci u ortopedsko – traumatološkoj operacijskoj sali zahtijevaju zahtijevaju odgovornost i učinkovitost u svakodnevom radu medicinske sestare – instrumentarke u cilju besprijekornog izvođenja operacijskog zahvata na dobrobit pacijenta.

Materijali i metode koji se koriste u provođenju SOP-a su: svakodnevni, višegodišnji rad i iskustvo, te protokol za kontrolu infekcija u operacijskoj Sali, a algoritmi rada su:

- Provjera opreme u operacijskoj sali, prije početka zahvata
- Provjera sterilnosti općeg i specijalnog instrumentarija dan ranije i na dan zahvata
- Provjera potrebnih implantata ili komponenti
- Provjera opreme u operacijskoj sali prije početka zahvata
- Provjera potpunosti operacijske sale sa svim potrebnim sanitetskim materijalom
- Priprema operacijske sale (priprema operacijskog stola sa nastavcima specifičnim za određeni zahvat, itd.)
- Ispunjavanje „Cheeking“ liste (provjera indentiteta pacijenta, strane i mjesta incizije, predstavljanje pacijentu kirurškog tima koji će sudjelovati u operacijskom zahvatu, itd.
- Provođenje operacijskog zahvata i instrumentiranje
- Pranje, održavanje i pakiranje instrumenata za sterilizaciju
- Ispunjavanje sestrinske dokumentacije

Svakodnevni rad medicinske sestare/instrumentarke teško je predočiti kroz jednu prezentaciju. Stres i težina samog posla čine odgovornost za život i zdravlje pacijenta, odgovornost ozračje u operacijskoj sali za vrijeme trajanja operacijskog zahvata, odgovornost i briga o asepsi, antisepsi i sterilnosti, briga o uspješnom provođenju operacijskog zahvata i briga za vlastito zdravlje, iz svega prikazanog može se vidjeti sveobuhvatnost posla kroz standardizirane postupke u traumatološko – ortopedskoj operacijskoj sali koje pokušavamo uklopiti u trenutnu ograničenu financijsku situaciju u zdravstvu.

Ključne riječi: SOP, medicinska sestra – instrumentarka, ortopedko – traumatološka operacijska sala



Standardizirani postupci medicinske sestre kod traumatoloških bolesnika s ozljedama zdjelice

Marina Krleža, Sonja Staroveški

KBC „Sestre Milosrdnice“ Klinika za traumatologiju

Medicinske sestre i tehničari izravno sudjeluju u zbrinjavanju bolesnika s ozljedom zdjelice. Standardizirani postupci kod traumatološkog bolesnika s ozljedom zdjelice počinju se koristiti prilikom prvog kontakta s ozljeđenikom te tijekom cijele skrbi tokom hospitalizacije. Medicinska sestra/tehničar kao član zdravstvenog tima prilikom samog dolaska u bolnicu sudjeluje u dijagnostičkim i terapijskim postupcima, preoperativnoj i postoperativnoj zdravstvenoj skrbi. Njezine zadaće usmjerene su na praćenje stanja bolesnika, mogućnost nastanka komplikacija i edukaciju.

Zavod za kirurgiju zdjelice, Klinike za traumatologiju, KBC Sestre milosrdnice ima osmišljenje algoritame i protokole zbrinjavanja ozljeđenika s ozljedom zdjelice. Algoritam hitnog primitka temelji se laboratorijskim pretragama, RTG-u srca i pluća, snimanju EKG-a i anesteziloškom pregledu. Veliki broj ozljeđenika premješta se iz drugih zdravstvenih ustanova te se prilikom prijema na Zavod bolesniku uz standardizirane postupke uzimaju još i uzorci za mikrobiološko ispitivanje (urinokultura, bris nosa i bris rektuma).

U posleoperacijskom periodu zadaće medicinske sestre temelje se na praćenju vitalnih znakova svakih 15 minuta, procjeni GCS, kontroli zavoja operativne rane, drenaži, procjeni boli, primjeni ordinirane analgezije, pravilnom unosu i iznosu tekućine, kontroli laboratorijskih pretraga, pravilnom položaj ekstremiteta nakon operacije te evidenciji svega navedenog u sestriinsku dokumentaciju. Veliku ulogu u što bržem oporavku ozljeđenika s ozljedom zdjelice ima fizikalna medicina i rehabilitacija. Medicinska sestra u skladu sa svojim kompetencijama svoje zadaće usmjerava na što raniju imobilizaciju kretanja uz pomoć pomagala, obavljanja osobne higijene, izvođenju lakših poslova i razgibavanja.

Standardizirani postupci temelje se na profesionalnošću, holističkom pristupu i empatiji prema ozljeđeniku s ozljedom zdjelice. Medicinska sestra će mu omogućiti adekvatnu brigu i skrb pomoću zadaća koje si zadaje planiranjem procesa zdravstvene njege tijekom boravka na Zavodu za kirurgiju zdjelice.

Ključne riječi: medicinska sestra/tehničar, ozljeda zdjelice, standardizirani postupci tokom boravka na Zavodu za kirurgiju zdjelice.



Standardni Operativni Postupci u operacijskoj sali za traumatologiji

Budiselić Vidaić Ivanka

KBC Rijeka

Važan aspekt sustava kvalitete je raditi u skladu sa jasnim standardnim operativnim postupcima (SOP). U stvari cijeli proces od uzorkovanja do podnošenja analitičkog rezultata treba opisati kontinuiranim nizom SOP Standardni operativni postupak je dokument koji opisuje redovito ponavljajući operacije važne za kvalitetu rada Svrha SOP je za obavljanje poslova ispravno i uvijek na isti način. SOP trebaju biti na raspolaganju na mjestu gdje je djelo postupakučinjen.” Standardizirani postupci u zdravstvenoj njezi predstavljaju pravila po kojima su medicinske sestre dužne postupati. Jedinstveni način provođenja postupaka osigurava isti standard i sigurnost za svakog bolesnika. Vremenski i kadrovski normativi koji proizlaze iz „Standardiziranih postupaka” omogućavaju planiranje potrebnog broja medicinskih sestara i nužnost razine obrazovanja što je važno za organiziranje provođenja zdravstvene njege. Određivanjem vremenskih i kadrovskih normativa racionalno se koriste ljudski potencijali. Vremenski normativi su procijenjeni temeljem mjerenja jedinice vremena u kliničkim uvjetima, a kadrovski temeljem kompetencija medicinskih sestara. Standardizirani postupci su pisani na način koji omogućava korisniku i medicinskoj sestri racionalno shvaćanje provedbe postupka. Koraci provedbe postupka omogućavaju optimalnu iskoristivost vremena prostora i materijala. Razvidne su kompetencije Primjena standardiziranih postupaka otklanja organizacijske probleme i konflikte među zaposlenima Odličan su edukacijski materijal za novozaposlene pripravnike i studente. Pogodni su sa sestriinskom listom i kategorizacijom pacijenata ovisno o potrebama za zdravstvenom njegom za određivanje optimalnog broja medicinskih sestara u zdravstvenoj ustanovi”.(citat HKMS)

Ključne riječi: Standardni operativni postupci, dokumentacija, prijelomi, traumatologija



FREE PAPERS
Nurse's day

Koštana banka

Kljajić Vesna

KBC Zagreb, Klinika za ortopediju

Koštana banka je organizirani sustav nabave, obrade, pohrane i distribucije muskulo – skeletnog tkiva sa svrhom njegove upotrebe u ortopedsko – traumatološkoj kirurgiji. Povijest koštanih presađaka i koštane transplantacije duga je preko stotinu godina u svijetu. Klinika za ortopediju Kliničkog bolničkog centra Zagreb je najstarija ustanova u Hrvatskoj u kojoj se upotrebljavaju koštani presađci i djeluje neprofitna koštana banka. Presađci se uzimaju od živih i mrtvih darovatelja. Živi darovatelji su bolesnici kojima se odstranjuje glava bedrene kosti zbog ugradnje totalne endoproteze kuka i koji daju svoj informirani pristanak. Od 2009 godine uzima se i spongiozni čep iz kanala bedrene kosti. Od mrtvih darovatelja muskulo – skeletni presađci se uzimaju kod multiorganskih eksplantacija. Svi presađci podliježu mikrobiološkoj analizi i skladište se u zamrzivaču na – 80oC u kontroliranim uvjetima. Porijeklo presatka i njegova sljedivost uredno se dokumentira. Eksplantacijski tim čine liječnici ortopedi i medicinske sestre instrumentarke. Hrvatska je član Eurotransplanta od 2007. i banke tkiva rade prema direktivama Europske unije.

Ključne riječi: koštana banka, koštani presađak, darovatelj, eksplantacija

Sestrinska skrb bolesnika sa Ewingovim sarkomom nakon operativne

Anzulović Marina

Klinika za dječije bolesti Zagreb

Najčešći maligni tumori kosti u djece i adolescenata su osteosarkom i Ewing sarkom. Ewing sarkom najčešće se javlja u srednjem dijelu dugih kostiju nogu i ruku, ali se također može razviti u zdjelici i drugim kostima. Bolesnici s ovim tumorima zahtijevaju multidisciplinarnu skrb tima koji uključuje dječjeg onkologa, ortopedsko onkoloških operatera, fizikalnu terapiju, patologa i radiologa te medicinske sestre specijalizirane za njegu ovakvih bolesnika. Kombinacija poboljšanja novih tehnika za kirurško uklanjanje tih tumora i unapređenje postupka za funkcionalnu obnovu sada omogućuje da 90-95% pacijenata s agresivnim tumorima se mogu liječiti, bez potrebe za amputacijom. Korištenje novih limb-sparing tehnika u zbrnjavanju bolesnika sa Ewing sarkomom provodi se i na našem odjelu što predstavlja izazov za cijeli tim sa posebnim naglaskom na sestrinsku skrb. Medicinske sestre imaju priliku pomoći pacijentima u pronalaženju odgovarajuće psihosocijalne podrške u preoperativnom periodu, dok u postoperativnom periodu fokus je na managementu boli i nuspojavama liječenja te pružanju djetetu i roditeljima podrške da tim čini sve što može kako bi optimizirao kvalitetu života. Cilj ovog rada je prikazati sestrinske postupke kroz prikaz slučaja bolesnika J. D. 16 god. sa dijagnozom Ewing sarkom zdjelice. Primljen je na odjel dječje ortopedije sa jedinice intenzivnog liječenja nakon zahtjevnog operativnog zahvata rekonstrukcije zdjelice i gornjeg dijela femura. (limb-sparing tehnika)

Ključne riječi: Sestrinska skrb, Ewing sarkom, limb-sparing tehnika

Zadaci operacijske sestre kod prednje vratne diskektomije

Vesna Svirčević, Sanja Lesnjak

Kbc Seste Milosrdnice, Klinika za neurokirurgiju

Kod gotovo 30% populacije u dobi do 50 godina, a čak 85% u dobi od 65 godina rendgenski se nalaze znakovi degenerativnih promjena (spondilozе) vratne kralješnice.

Do sredine 50-ih godina 20. stoljeća za bolesnike s vratnom spondilozom rutinski je kirurški pristup bio stražnji. Problem kod tog pristupa je taj što se i disk, a i većina degenerativnih promjena (osteofita), nalaze sprjeda u odnosu na leđnu moždinu te je teško postići adekvatnu dekompresiju. Neadekvatni rezultati stražnjeg pristupa, ali i napredak operacijskih tehnika, doveli su do otkrića prednjeg pristupa 50-ih godina prošlog stoljeća

Vratna spondilozа ima u osnovi bolest intervertebralnog diska koji gubitkom svojih elastičnih svojstava dovodi posljedično do promjena na kostima odnosno mekim tkivima. Osnovna patološka karakteristika je gubitak sadržaja vode u nukleos pulposusu te gubitak elastičnih svojstava.

Operacijska sestra mora imati stručno, teorijsko i praktično znanje što joj omogućava da bude pripremljena na sve moguće komplikacije. Ona mora dobro poznavati sve faze operacije kako bi pratila kirurga u njegovom radu i kako bi znala pripremiti potreban instrumentarij i na vrijeme reagirati u svakoj prilici. Uloga operacijske sestre da pomaže operateru zahtjeva i u prvi plan stavlja njezinu sposobnost dobre mehaničke intervencije. Dobra komunikacija također je važan element za uspješan i profesionalni rad u bilo kojem zanimanju pa tako i u radu operacijske sestre, kako sa osobljem i suradnicima na poslu, tako i sa pacijentima. Kako bi se bolje osjećali i bili uspješniji u svojoj profesionalnoj ulozi kao profesionalci dužni smo djelovati ljubazno u svim situacijama jer ljubaznost i srdačnost smanjuju mogućnost konflikta, daju osjećaj međusobnog uvažavanja i poštovanja što je neophodno za timski rad.

Instrumentiranje ove operacije podrazumijeva obavljanje niza složenih zadataka koji moraju biti učinjeni, jer u suprotnom možemo ugroziti uspješnost zahvata kao i zdravlje pacijenta. Kako bi operacija prošla neometano sestra je dužna na vrijeme provjeriti i pripremiti potrebnu aparaturu, sterilni instrumentarij, te sve potrošne materijale koji će se koristiti u tijeku operacijskog zahvata.

Složenost operacijskih zahvata u neurokirurgiji, kao i napredak medicine, te uvođenje novih tehnološko sve zahtjevnijih zahvata obavezuje medicinsku sestru na kontinuiranu edukaciju.

Zadaci operacijskih sestara kod intraoperativne primjene gama detekcijske sonde

Marina Đakulović, Martina Čvrljak, Martina Stivičević

KBC „ Sestre Milosrdnice“ Klinika za traumatologiju

Koncept radionavigacije u kirurgiji razvijao se zadnjih 60 godina. U radu će biti prikazan primjer upotreba gama navigacijske sonde kod tretiranja osteidsateoma, pri čemu je stavljen naglasak na zadaci operacijske sestre - instrumentarke pri ovom dijagnostičko - kirurškom zahvatu.

Zadaci operacijske sestre - instrumentarke kod inovativnih i nesvakidašnjih tehnika u kirurgiji kao što je upotreba radionavigacije zahtjevaju posjedovanje visokod stupnja znanja, stručnosti i vještina. Njezine intervencije započinju pripremom bolesnika pri ulasku u operacijski blok, pripremom specifičnog instrumentarija i opreme kao i osiguranje sterilnosti istih. Osim svih operacijskih protokola koje primjenjujemo u Klinici za traumatologiju, KBC Sestre milosrdnice, operacijska sestra u prvom redu mora brinuti za sigurnost bolesnika i zaštitu od zračenja kako za operacijski tim, tako i za samog bolesnika.

Upotreba radionavigacije u kirurgiji zahtjeva educirane operacijske sestre koje poznaju samu tehniku zahvata u cilju što bolje pripreme bolesnika za zahvat i sprječavanju potencijalnih komplikacija. Ona svojim znanjem, vještinama i holističkim prirupom u skladu sa svojim kompetencijama pridonjet će što bržem provođenju ovog dijagnostičko-terapijskog zahvata, a samim time i krećem boravku bolesnika u bolnici.

Ključne riječi: gama navigacijska sonda, operacijski blok, zadaci medicinske sestre

Iskustva medicinskih sestara u OB Dubrovnik u svezi rada na ortopedsko traumatološkom odjelu

Violić Neda

OB Dubrovnik

Cilj predavanja je prikazati rad i tekuću problematiku u radu medicinskih sestara na ortopedsko traumatološkom odjelu OB Dubrovnik. Na našem odjelu opskrbljujemo ortopedsku i traumatološku kazuistiku lokomotronog sustava. Problemi se javljaju prvenstveno radi visoke dobi naših korisnika i otežane pokretljivosti, prije i poslije liječenja. Također, za napomenuti je socijalna problematika tih bolesnika koje je nakon liječenja u bolnici teško vratiti u svoju sredinu.

Reimplantacija totalne proteze kuka -uloga operacijske sestre-tehničara

Žuić Željko, Piliović Elvis

Specijalna bolnica za ortopediju Biograd n/m

Kroz ovaj rad smo htjeli prikazati indikacije, tijekom operacije i komplikacije ovog operacijskog zahvata kao i ulogu op.sestre-tehničara koji priprema sav potreban materijal i instrumente, asistira tijekom operacijskog zahvata pridržava se svih protokola i postupaka kako u pripremi tako i za vrijeme zahvata.

Kakvu medicinsku sestru treba pacijent?

Karmela Hrastinski

Specijalna bolnica za ortopediju i traumatologiju lokomotornog sustava, fizikalnu medicinu i rehabilitaciju Akromion

Pacijenti nerijetko nemaju predodžbu kako se trebaju ponašati u komunikaciji sa sestrama. Obično imaju predrasude. Profesionalan odnos trebao bi podrazumijevati percipiranje sestre kao osobe koja primjenjuje svoje znanje i vještine u cilju postizanja dobrobiti pacijenta. Sestra treba poštovati pacijentovu jedinstvenost i individualnost, te njegova prava da sudjeluje u procesu njege.

Provedeno je istraživanje među pacijentima u kojem je opći nalaz da ispitanici većinom izražavaju pozitivne stavove o sestrama. U prosjeku 61% ispitanika slaže se s tvrdnjama o pozitivnim osobinama m. s., međutim 39% se ne slaže s tim tvrdnjama. Među izjavama o poželjnim osobinama m. s. izražene su slijedećim pridjevima: pažljiva, vesela, suosjećajna, nježna, puna razumijevanja... Među nepoželjnim osobinama izraženu su: osorna, hladno poslovna, hladnokrvna, imuna na patnju, neemocionalna, bezosjećajna...

U bolesti, pacijent se prepušta liječniku/sestri, tražeći od njih privremenu fizičku/psihičku pomoć i stavlja se u stanje njihove ovisnosti. Cilj svake medicinske sestre treba biti da stavi bolesnika u situaciju u kojoj će sam moći utjecati na svoj život, s velikim povjerenjem prema pomoći koju mu ona pruža. Svi se ovi postulati mogu savršeno ostvariti, ukoliko sestre u svom profesionalnom radu provode koncept integralne skrbi.

Sigurna i točna navigacija = snaga i moć ortopedске operacijske sestre/tehničara

Kristina Krupljan, Maja Kovačić, Tihana Gabud

Specijalna bolnica Sveta Katarina, Zabok

Izvođenje operacijskih postupaka zahtjeva primjenu svih raspoloživih tehnika i vještina - navigaciju za iznalaženje najpovoljnijeg puta koji će rezultirati kvalitetnim radom cjelokupnog operacijskog tima. Opis poslova operacijske sestre / tehničara omogućava definiciju cost benefita za bolesnika i cjelokupnu zajednicu. Pacijent će profitirati tako da će svaki operacijski zahvat biti izveden na najučinkovitiji način uz maksimalnu sigurnost. Korist za zajednicu odnosi se na provođenje najracionalnijeg pristupa poslu uz najbolji učinak.

Kontrola kvalitete danas je imperativ i nemoguće ju je raditi bez specifikacije opisa poslova.

Opis poslova operacijske sestre čine dva glavna područja rada i djelovanja.

1. Medicinski operativni postupci
 - a. analiza, planiranje i organizacija rada
 - b. priprema radnog mjesta
 - c. operativni poslovi
 - d. administrativni poslovi
 - e. komercijalni poslovi
2. Standardi profesionalne prakse
 - a. komunikacija i suradnja s drugima
 - b. osiguravanje kvalitete
 - c. zaštita zdravlja i okoliša

Unutar navedenih područja rada mogu se procjenjivati i druge kategorije koje se svrstavaju unutar znanja, vještina i orijentacije.

Opis poslova osnova je za evaluaciju rada, razvijanje smjernica za rad, određivanje kompetencija, te uspostavu kontrole kvalitete. Sve navedeno dio je primjene menagementa u sestrinstvu i razvoja profesionalne prakse, u smjeru znanstveno dokazanih postupaka (EBC Evidence Base Care) i napuštanje tradicionalističkog pristupa. Dobro bi bilo slijediti načela rada prognostičara vremena: neprekidno prikupljati podatke, te prognoze mjenjati i popravljati.

Sestrinske intervencije kod ugradnje intramedularne fiksacije (supernail)

Željka Vondraček, Sanja Kraševac

Opća bolnica "Dr. Tomislav Bardek"
Koprivnica

AO metoda, kao opće prihvaćena metoda liječenja koštanih prijeloma prvi se puta spominje 1958. god. u Švicarskoj. Razvoj u tehnologiji pridonio je izradi implantanata, boljem poznavanju biomehanike, funkciji i oblik normalnog i patološki promijenjenog sustava za kretanju po zakonu statike i dinamike. Napredak kirurških tehnika, asepsa i antisepsa, upotreba antibiotika te razvoj anesteziologije doveli su do velikog napredka na području traumatologije.

Cilj ovoga rada je prikazati standardizirane postupke kod uvođenja intramedularne fiksacije pomoću RTG pojačivača, s naglaskom na sigurnost pacijenta od ulaska u operacijski blok, do završetka op. zahvata i izlaska iz bloka.

Rad cijelog zdravstvenog tima uvelike pridonosi kvaliteti izvođenja samog zahvata. Medicinska sestra kao jedna od članova tima svojim znanjem, vještinam i profesionalnošću tijekom cijelog operativnog zahvata, ali prije i post operativnoj zdravstvenoj skrbi pridonosi poboljšanju i što prijem opravku bolesnika.

U Općoj bolnici Koprivnica prvi takav zahvat izveden je 2005. godine i od tada do danas provodi se po protokolu usvojenom od strane jedinice za kvalitetu.

Ključne riječi: medicinska sestra, intervencija, fractura, intramedularna fiksacija, supernail

Konzervativno liječenje humeroskapularne luksacije

Mihael Strle, Natalija Hadžić, Dragana Barukčić

KBC „Sestre Milosrdnice“ Klinika za traumatologiju

Uvijek u slučaju dislokacija (iščašjenja), nastaje jaka sila koja vuče rame prema van ili dolazi do ekstremne rotacije zgloba koja izbacuje glavu humerusa iz ležišta na lopatici. Ukoliko se ruka naglo i snažno povuče prema nazad mišići su nesprenni na akciju ili je sila prevelika, isto tako dolazi do dislokacije.

Cilj rada je kroz praćenje broja pacijenata u Klinici za traumatologiju prikazati koliko pacijenata je zaprimljeno u Kliniku sa dijagnozom humeroskapularne luksacije, povezanost povrede sa dobi i spolom pacijenta, koliko je prosječno trajanje liječenja i oporavka, koje su najčešće komplikacije koje se javljaju kod konzervativnog liječenja, te omjere konzervativnog i operativnog liječenja. Naravno i sama prevencija i smanjenje broja povreda, unapređenje metoda konzervativnih postupaka.

Koristi se statistička obrada podataka dobivena iz baze podataka Klinike iz koje će se dobiti potrebni podaci.

Istraživanje će obuhvatiti razdoblje od 4 mjeseca, točnije siječanj, srpanj, kolovoz te prosinac 2014. godine, kroz koje će biti obuhvaćeno 87 pacijenata.

Intervencije medicinske sestre, odnosno tehničara započinju već prilikom samog dolaska pacijenta u hitnu ambulantu gdje se pacijent zbrinjava za daljnje pretrage. Svoja znanja i vještine medicinska sestra/tehničar nastavlja koristiti kroz daljnju obradu pacijenta, bilo to daljnje konzervativno liječenje, ili sama briga za takvog bolničkog pacijenta.

Ključne riječi: humeroskapularna luksacija, dislokacija, liječenje, medicinska sestra/tehničar.

Stručnost, učinkovita komunikacija i timski rad u operacijskoj sali

**Blaženka Kozina, Snježana Bastaja,
Ljiljana Ljiljak, Jasmin Suljičić**

KB Dubrava

Operacijska dvorana je mjesto koje zahtijeva timski rad, učinkovitu komunikaciju, brzo donošenje odluka, rutinske provjere te pridržavanje protokola.

Priprema bolesnika, promišljeno pozicioniranje, očna zaštita te pravilno rukovanje opremom samo su neki od čimbenika važnih za sigurnost pacijenata u operacijskoj dvorani. Ako se izvode pravilno mogu se spriječiti ozljede živaca i postoperativna bol u zglobovima ili mišićima bolesnika.

Operacijska sestra/tehničar, kirurg i članovi anesteziološkog tima odgovorni su za pravilan položaj tijela pacijenta tijekom operacijskog zahvata. Prije operacije potrebno je uzeti u obzir faktore rizika kao što su npr. duljina postupka, operacijski položaj, dob, stanje kože, mobilnost itd. Bazični položaji u operaciji su supinacijski, pronacijski, lateralni i litotomijski. Svaki od njih nosi određene rizike za komplikacije odnosno za neželjeni događaj koji se mora pravilno dokumentirati i prijaviti.

Provođenjem kontinuirane edukacije osoblja u operacijskoj dvorani razvija se svijest o potencijalnim komplikacijama te unapređuje sigurnost i zaštita pacijenta tijekom operacijskog zahvata. Učinkovita komunikacija je također važna u osiguravanju pružanja učinkovite zdravstvene usluge i izbjegavanja pogrešaka.

Ključne riječi: operacijska dvorana, medicinska sestra, sigurnost, učinkovitost



E-POSTER
Nurse's day

Zadaća medicinske sestre - instrumentarke kod ugradnje personaliziranog 3 – D implantata u rekonstruktivnoj kirurgiji zdjelice

**Željka Anić, Sunčica Babić, Marijana
Biluš – Barković**

KBC Sestre Milosrdnice, Klinika za traumatologiju

Razvoj tehnologije, kirurških tehnika i instrumentarija, doveo je do novih terapijskih mogućnosti u liječenju do sad neizlječivih i mutilirajućih oboljenja.

Cilj rada je prikazati slučaj pacijentice s hondrosarkomom zdjelice u Klinici za traumatologiju, KBC Sestre milosrdnice. Dosadašnji način liječenja bio hemipelvektomija dok je novi način liječenja upotrebom rekonstruktivnog, personaliziranog 3 – D implantata.

Šesdestedvogodišnjakinja zaprima se u Kliniku za traumatologiju, KBC Sestre milosrdnice kao redovni primitak s ciljem ugradnje personaliziranog 3 – D implantata. Medicinska sestra/instrumentarka kao član multidisciplinarnog tima sudjeluje u procesu dijagnostike, liječenja i rehabilitacije bolesnika s ugradnjom 3-D personaliziranog implantata. Ovo stanje zahtjeva holistički pristup pacijentici s puno stručnosti, znanja i vještina. Kod ovako opsežnih operativnih zahvata potrebna je velika koncentracija i sinhroniziranost unutar cijelog tima. Medicinska sestra – instrumentarka, kao „temeljna čestica“ svake operacijske sale, u ovakvim zahvatima, prikazuje svu raskoš svog znanja i organiziranosti, te je njezina uloga od presudnog značaja.

Računalno potpomognuti modeli imaju svoju primjenu u kirurgiji budućnosti pri rješavanju kompleksnih traumatoloških i ortopedskih te tumorskih stanja.

Ključne riječi: zadaće medicinske sestre – instrumentarka, personalizirani 3-D implantat

Operacijska sestra alfa i omega operacijske dvorane

**Tatjana Stiperski, Mihaela Tomašek,
Tina Šajnović**

KBC Sestre Milosrdnice, Klinika za traumatologiju, Croatia

Operacijska sala je mjesto koje zahtjeva timski rad, dobru komunikaciju, dinamičnost, učinkovitost, stručnost i efikasnost. Multidisciplinarni tim (anesteziolog, anesteziološki tehničar, kirurg, radiolog, medicinska sestra/ instrumentarka...) koji boravi tijekom operativnog zahvata u operacijskog sali odgovoran je za ishod operativnog zahvata, a samim time i za zdravstveno stanje bolesnika.

Cilj rada je predočiti svakodnevni rad, zadaće, odgovornost i intervencije medicinske sestra/ instrumentarke kao ravnopravnog člana multidisciplinarnog tima unutar operacijske sale. Njezine zadaće i intervencije u svakodnevnom radu osim instrumentiranja su usmjerene na brigu i sigurnost bolesnika prije i poslije operacijskog zahvata, broj i vrstu instrumenata i implantata, pripremu operacijske dvorane, instrumentiranje prilikom operativnog zahvata i ispunjavanje sestrinske dokumentacije nakon operativnog zahvata.

Instrumentiranje unutar operacijske dvorane zahtjeva obavljanje niza složenih zadataka koji moraju biti učinjeni, suprotno tome može se ugroziti uspješnost zahvata, a time i zdravlje bolesnika. Posebno poglavlje u svakodnevnom radu medicinske sestare/ instrumentarke predstavlja dezinfekcija, sterilizacija i rad u aseptičnim uvjetima kao preduvjet uspješnog operacijskog liječenja.

Medicinska sestra/instrumentarka mora biti visoko educirana, mora pratiti nove smjernice i metode rada u operacijskoj dvorani. Ona mora posjedovati stručnost, vještinu i znanje kako bi bila kvalitetan i ravnopravan član multidisciplinarnog operacijskog tima.

Ključne riječi: zadaće medicinske sestre- instrumentarke, instrumentiranje, operacijski zahvat

Slobodni kožni transplantat; uzimanje, postavljanje i njega

Mandica Lagundžija, Đurđa Matovina,
Janja Pranjčić, Zora Kaurin

Klinika za plastičnu, rekonstrukcijsku i estetsku kirurgiju, KB "Dubrava", Zagreb

Kirurški postupak presađivanja kože uključuje uzimanje kože sa donorskog mjesta i pripremu za pokrivanje defekta nastalog nakon odstranjenja tumora, za pokrivanje opeklinjskih rana i defekta nakon debridmana kroničnih i akutnih rana. Tipovi kože transplantata su podijeljeni prema debljini, transplantati djelomične i pune debljine.

Za uzimanje transplantata se koristi kirurški instrument dermatom. Slobodni kožni transplantat se pričvršćuje za podlogu malim šavovima ili kirurškim zakovicama, te preživljava na podlozi plazmatskom imbibicijom. Terapija rane negativnim tlakom omogućuje veći postotak prihvaćanja transplantata. Rizici operacije uzimanja slobodnog kožnog transplantata su: krvarenje, infekcija i gubitak presađene kože. Poslije postavljanja transplantata važno je zadržati odgovarajuće uvjete u prva dva dana kako bi se transplantat prihvatio. Stoga prvi prevoj slijedi 3-4 postoperativni dan. Tijekom slijedećih dana primajuća regija se ostavlja 1 sat svaki dan pod "šatorom" da bi omogućilo brže cijeljenje. Njega transplantata zahtjeva znanje i posebnu njegu.

Davajuća regija treba stvoriti novi sloj epidermisa rubnim cijeljenjem. Potrebno je adekvatno zaštititi ranu tijekom tog cijeljenja. Vrste obloga koje se mogu koristiti kao pokrov donorskog mjesta su: Granuflex, Aquacel, Aquacel Ag., Kaltostat, Biatain te paste i gelovi.

Medicinske sestre su educirane o metodama postavljanja transplantata i postoperativne njege.

KLJUČNE RIJEČI: presađivanje kože, oporavak, obloge, medicinska sestra

Multidisciplinarni pristup pacijentu s prijelomom uslijed opeklina

Zorica Martić

KBC Sestre milosrdnice, Klinika za traumatologiju, Zavod za opeklina

Opeklina kože, potkožnog tkiva i mišića obuhvaćaju širok raspon različitih traumatskih struktura organa i organskih sustava pri čemu nastaju brojne komplikacije po život opasne za samog ozljeđenika. Tijekom 2014. godine u KBC Sestre milosrdnice, Zavodu za opeklina, Kinike za traumatologiju hospitalizirano je 118 pacijenata, od čega 4 pacijenata s pridruženim ozljedama lokomotornog sustava.

Cilj rada je predočiti pravilnu hitnu obradu pacijenta s opeklinjskim ozljedama kože i lokomotornog sustava, terapijskim metoda te mogućim komplikacije tijekom liječenja. Pacijentica N.V. zaprima se kao dogovoreni premještaj iz OB Požeja koja je prilikom obavljanja kućanskih poslova s vrelom vodom zadobila otvoreni prijelom desne potkoljenice sopeklinama 1,2 i 3 stupnja gornjih i donjih ekstremiteta, trupa i spolovila. Pri samom primitku pacijentica je pri svijesti, kontaktibilan, GCS 15, respiratorno suficijentan, urednih vitalnih funkcija. Učinjena je obrada opeklinjskih rana te uz nadzor anesteziologa učinjena je repozicija prijeloma u području desnog gležnja.

Nakon dva dana učinjen operativni zahvat u OETA. Plasiran vanjski fiksator na desni gležanj, učinjena je nekrekotomija u području desnog gležnja, uzet biopiat tkiva za MKB. Postoperativno bolesnica budna, spontanog suficijentnog disanja upućena u opeklinjski JIL. U opeklinjskom JIL-u kontinuiran monitoring vitalnih funkcija, praćenje satne diureze, primjena ordinirane terapije, kontrola ordiniranih laboratorijskih nalaza.

Liječenje opeklina provedeno operativno u nekoliko navrata, učinjena je nekrekotomija i pokrivanje defekata kože vlastitim slobodnim kožnim presatkom po Tierschu - Mash graft tehnikom i Micrografting. Treiranje operiranih rana se vrši svakodnevno uz poštivanje mjera asepse i antiseptike kako bi se smanjio rizik unošenja infekcije, te dolazi do brže epitelizacije opečenih površina i davajućih regija u cijelosti.

Medicinska sestra/ tehničar kao član multidisciplinarnog tima sudjeluje u svim fazama dijagnosticiranja, liječenja i rehabilitacije pacijenta s opeklinjskom ozljedom. Ovo stanje zahtjeva holistički pristup ozljeđeniku s puno stručnosti, znanja i vještina. Medicinska sestra/tehničar stalnim promatanjem i dokumentiranjem vitalnih znakova te samih promjena i komplikacija na koži dobiva komplementan uvid u stanje bolesnika, ali i o učinkovitosti svog rada. Zdravstvena njega

opeklinskog pacijenta s prijelomom opsežna je i zahtijeva svakodnevnu suradnju medicinskih sestara s anesteziolozima, kirurzima, te ostalim timom (mikrobiolozi, radiolozi, fizioterapeutima...).

Suradnja cijelog tima mora biti na visokoj razini, jer samo dobrom suradnjom tima postižu se dobri i brzi rezultati.

KLJUČNE RIJEČI: opelikle, prijelom, medicinska sestra, operativni zahvat, JIL,

Zadaci operacijske sestre kod prednje vratne diskektomije

Vesna Svirčević, Sanja Lesnjak

Kbc Seste Milosrdnice, Klinika za neurokirurgiju

Kod gotovo 30% populacije u dobi do 50 godina, a čak 85% u dobi od 65 godina rendgenski se nalaze znakovi degenerativnih promjena (spondiloze) vratne kralješnice.

Do sredine 50-ih godina 20. stoljeća za bolesnike s vratnom spondilozom rutinski je kirurški pristup bio stražnji. Problem kod tog pristupa je taj što se i disk, a i većina degenerativnih promjena (osteofita), nalaze sprijeda u odnosu na leđnu moždinu te je teško postići adekvatnu dekompresiju. Neadekvatni rezultati stražnjeg pristupa, ali i napredak operacijskih tehnika, doveli su do otkrića prednjeg pristupa 50-ih godina prošlog stoljeća

Vratna spondiloza ima u osnovi bolest intervertebralnog diska koji gubitkom svojih elastičnih svojstava dovodi posljedično do promjena na kostima odnosno mekim tkivima. Osnovna patološka karakteristika je gubitak sadržaja vode u nukleosu pulposusa te gubitak elastičnih svojstava.

Operacijska sestra mora imati stručno, teorijsko i praktično znanje što joj omogućava da bude pripremljena na sve moguće komplikacije. Ona mora dobro poznavati sve faze operacije kako bi pratila kirurga u njegovom radu i kako bi znala pripremiti potreban instrumentarij i na vrijeme reagirati u svakoj prilici. Uloga operacijske sestre da pomaže operateru zahtjeva i u prvi plan stavlja njezinu sposobnost dobre mehaničke intervencije. Dobra komunikacija također je važan element za uspješan i profesionalni rad u bilo kojem zanimanju pa tako i u radu operacijske sestre, kako sa osobljem i suradnicima na poslu, tako i sa pacijentima. Kako bi se bolje osjećali i bili uspješniji u svojoj profesionalnoj ulozi kao profesionalci dužni smo djelovati ljubazno u svim situacijama jer ljubaznost i srdačnost smanjuju mogućnost konflikta, daju osjećaj međusobnog uvažavanja i poštovanja što je neophodno za timski rad.

Instrumentiranje ove operacije podrazumijeva obavljanje niza složenih zadataka koji moraju biti učinjeni, jer u suprotnom možemo ugroziti uspješnost zahvata kao i zdravlje pacijenta. Kako bi operacija prošla neometano sestra je dužna na vrijeme provjeriti i pripremiti potrebnu aparaturu, sterilni instrumentarij, te sve potrošne materijale koji će se koristiti u tijeku operacijskog zahvata.

Složenost operacijskih zahvata u neurokirurgiji, kao i napredak medicine, te uvođenje novih tehnološko sve zahtjevnijih zahvata obavezuje medicinsku sestru na kontinuiranu edukaciju.

Dijabetičko stopalo

Višnja Šimunović

Kristina Muhvić, Anamarija Čupić, Marina Samec

Klinika za plastičnu, rekonstrukcijsku i estetsku kirurgiju, Klinička bolnica "Dubrava", Zagreb

Komplikacije infekcije dijabetičkog stopala u 50% - 70% slučajeva predstavlja indikaciju za amputaciju donjih ekstremiteta. Liječenje dijabetičkog stopala uključuje opsežni kirurški debridman i vaskularne intervencije, nošenje "off-loading" obuće, korekcija glikemije te provođenje antibiotske terapije. Terapija sistemom za negativni tlak predstavlja koristan i učinkovit način za kontrolu infekcije i potporu u cijeljenju rane. Terapijom negativnim tlakom (TNT) priprema se granulacijska podloga rane za konačno direktno zatvaranje ili pokrivanje defekta sa režnjem. Klinička slika dijabetičkog stopala se razvija kao infekcija tkiva stopala kao posljedica neprepoznatog mehaničkog oštećenja. Ono nastaje zbog smanjenog lokalnog osjeta kao posljedica dijabetičke neuropatije i smanjenje cirkulacije kao posljedica dijabetičke angiopatije.

E-poster je prikaz kliničkog slučaja pacijenta od 68 godina kod kojeg se liječila komplikacija infekcije dijabetičkog stopala. Nakon kirurškog debridmana postavljen je sistem za TNT kako bi se smanjila bakterijska kontaminacija rane i potaklo stvaranje granulacijskog tkiva. Svi prijave i postavljanje slobodnog kožnog transplantata tip Thiersch radili su se na Klinici, gdje su medicinske sestre sudjelovale u kontroli sistema za negativni tlak i postavljanju SKT-a. Kod pacijenta je došlo do potpunog cijeljenja rane.

KLJUČNE RIJEČI: dijabetičko stopalo, TNT, medicinska sestra

Uloga medicinske sestre u liječenju akutne boli kod ortopedskih bolesnika

Snježana Mičić

Specijalna bolnica za ortopediju i traumatologiju lokomotornog sustava, fizikalnu medicinu i rehabilitaciju akromion

Bol je intenzivan osjećaj praćen strahom i tjeskobom koji utječe na cjelovito funkcioniranje organizma i remeti zadovoljavanje svih ljudskih potreba. Dakle, veoma je važno bolesniku ublažiti bol, te time postići bolji poslijeoperacijski oporavak čime se postiže i poboljšanje samog operacijskog zahvata.

Intervencije medicinske sestre su da uspostavi odnos povjerenja s bolesnikom, prepozna fazu boli, primjeni propisani analgetik, prepozna neželjene učinke analgetika, podučava o bolovima, planira i primjenjuje nemedikamentne postupke za ublažavanje boli, prati uspješnost ublažavanja boli, planira provođenje njege bolesnika, vodi dokumentaciju o boli i koordinira radom između svih zdravstvenih djelatnika.

Medicinska sestra ima mnogobrojne zadaće u poslijeoperacijskoj skrbi bolesnika a za njihovo provođenje važno je poznavanje svih postupaka, njihovo kontinuirano provođenje, stalno monitoriranje bolesnika te timski rad sa drugim sestrama i medicinskim osobljem uključenim u liječenje. Samo pravilnim provođenjem svih postupaka moguće je postići optimalno liječenje poslijeoperacijske boli.

Algoritmi zbrinjavanja ozljeđenika s prijelomom zdjelice

Margareta Bajsic Beljak, Dragana Barukčić, Natalija Hadžić,

KBC „Sestre Milosrdnice“ Klinika za traumatologiju

Prijelomi zdjelice su indikator teške traume. Ispravno rana postavljena dijagnoza najvažnija je za plan liječenja i daljnju opservaciju ozljeđenika. Medicinska sestra kao stručan dio tima sudjeluje u intervenciji i liječenju od samog dolaska ozljeđenika u zdravstvenu ustanovu. Pretpostavka je da poznavajući algoritam zbrinjavanja ozljeđenika s prijelomom zdjelice znači najbolju moguću dijagnozu, liječnje i skrb za ozljeđenika. Cilj mora biti skrb bolesnika izvedena na učinkovit, primjeren i ekonomski prihvatljiv način. Pri izradi rada korištena je anketa, bazirana na „Likertovoj ljestvici“, usmjerena na analizu teoretskog prepoznavanja težine ozljede kod ozljeđenika s traumom zdjelice te mjesta i načina hitnog zbrinjavanja takvih ozljeda u Klinici za traumatologiju, KBC Sestre milosrdnice. Većina ispitanika svjesna je težine ozljede zdjelice i kakve konsekvence ona potencijalno nosi sa sobom. Većina ima spoznaju o tome kako soba za hitni primitak mora izgledati, odnosno s kakvim lijekovima i aparatima mora biti opremljena. Nadalje, polovičan postotak ispitanika je upoznat s algoritmom zbrinjavanja ozljede zdjelice i u mogućnosti su adekvatno komplementarno djelovati u timskom zbrinjavanju ozljeda, a svi su svjesni potrebe za osnovnom i trajnom edukacijom vezanom uz hitno zbrinjavanje ozljeda zdjelice.

Intervencije medicinske sestre pri hitnom zbrinjavanju teških ozljeđenika s ozljedom zdjelice usko je vezana uz liječnički posao te u isto vrijeme ima specifičnosti kojima svaka medicinska sestra koja ima doticaja s takvim ozljeđenima mora vladati. U pozadini svega stoji teoretsko poznavanje zbrinjavanja teških ozljeđenika kako bi se to znanje uspješno primijenilo u konkretnim slučajevima.

Intervencije medicinske sestre nezostavna je u suradnji s ostalim sudionicima tima omogućuje pružanje kvalitetne i profesionalne medicinske pomoći. Medicinska sestra kao dio zdravstvenog tima koji pruža pomoć ozljeđeniku s ozljedom zdjelice potrebna je trajna edukacija vezana uz posao koji obavlja. Za samog ozljeđenika to predstavlja bolje shvaćanje svojeg zdravstvenog stanja i potencijalnih rezultata liječenja, vraćanje optimizma te na kraju znatno uspješniji i kraći boravak u zdravstvenoj ustanovi.

Ključne riječi: medicinska sestra, ozljeda zdjelice, suradnja zdravstvenog tima, edukacija

Zadaće medicinske sestre kod zbrinjavanja ortopedskog bolesnika

Maja Pleša, Nada Haluga

KBC “Sestre milosrdnice”, Croatia

Operativnim zahvatom poboljšava se kvaliteta života, medicinska sestra kao član zdravstvenog tima uključena je u sam proces skrbi za bolesnika od trenutka njegovog prijema na odjel do otpusta. Ona provodi najviše vremena uz bolesnika i samim time može procijeniti njegov fizički, psihički i emocionalni odgovor na zahtjeve zdravstvene njega.

Proteza kuka ili koljena se ugrađuje ako se liječenje ne može provesti konzervativnim putem. Postoje totalne proteze, kojima se zamjenjuje cijeli zglob kuka i bescesmentne. Uz totalne poteze postoje još i parcijalne proteze, kojima se zamjeni samo glava bedrene kosti. Proteza koljena se sastoji iz natkoljenog i potkoljenog dijela.

Operacija ugrađivanja umjetnog zgloba kuka ili koljena danas je postala standard svakodnevnog rada naše ustanove te se još uvijek ubraja u složene operacijske zahvate. Bolesnik se 15 dana prije zahvata obavijesti o operativnom zahvatu i on dobiva upute o preoperativnim pretragama. Periperatovna priprema bolesnika se sastoji od krvnih pretraga, urina, urinokulture, RTG srca i pluća, EKG srca, anesteziološki pregled, te ovisno o zdravstvenom stanju i životnoj dobi internistički pregled. Samim dolaskom bolesnika na odjel medicinska sestra uzima anamnezu, pregledava medicinsku dokumentaciju, ispisuje temp.liste, izrađuje plan zdravstvene njega te bolesnika smješta u sobu. Postoperativno razdoblje uključuje kontrolu vitalnih funkcija, uočavanje promjena u tjelesnom sustavu, kontrolu lab.nalaza, kontrolu krvarenja, prevenciju hemoragijskog šoka i primjenu analgezije. Kasnija skrb med.sestre svodi se na pomoć pri samozbrinjavanju.

Nakon ugradnje proteza kuka smanjuje se bolesnikova bol i patnja. Bolesniku se poboljša izgubljena funkcija zgloba, smanje se ili potpuno nestanu tegobe te se poboljša kvaliteta života.

“Mnogi bolesnici za vrijeme boravka u bolnici nemogu zadovoljiti neke od svojih osnovnih psiholoških potreba kao što su: potreba za ljubavlju i pripadanjem, potreba za sigurnošću i ugodom, potreba za poštovanjem i samopoštovanjem”. (Kalauz S.)

Uspoređujući ovaj citat jasno možemo vidjeti da medicinska sestra kirurškom bolesniku pomaže : psihološki, fizički i edukacijom.

Zdravstvena njega se provodi bazirajući se na individualnom i holističkom pristupu bolesniku, jer

se jedino na taj način može postići cilj da se pojedinac osposobi za što kvalitetniji i samostalniji život.

Ključne riječi: bolesnik, ugradnja proteze kukai koljena, perioperativna i postoperativna zdravstvena njega, medicinska sestra

Nekrotizirajući fasciitis trupa

Katarina Kljak, Ana Zelić, Marko Petrović

KB Dubrava, Croatia

Nekrotizirajući fasciitis (NF) je brzo šireća infekcija mekih tkiva, obično uzrokovana toksinima koje proizvode bakterije. Rana dijagnoza s agresivnim multidisciplinarnim liječenjem je obvezatna. Standardni pristup liječenju uključuje radikalni kirurški debridman za uklanjanje nekrotičnog tkiva i liječenje kombinacijom antibiotika i parenteralnu nadoknadu u jedinicama intenzivne skrbi.

Nakon adekvatne kirurške ekscizije najčešće zaostaje veliki defekt mekih tkiva koje treba zbrinuti. Metoda izbora prije konačnog kirurškog zbrinjavanja je pokrivanje defekta oblogama do stabilizacije pacijenta i urednog brisa rane. Nakon toga kirurško pokrivanje defekta može biti sa slobodnim kožnim transplantatom ili režnjem. Terapija negativnim tlakom (TNT) se također koristi za pokrivanje defekta ili fiksaciju transplantata.

Ovaj e-poster prikazuje klinički slučaj nekrotizirajućeg fascitisa trupa. Kiruršku eksciziju, konzervativnu njegu nastalog defekta mekih tkiva, pokrivanje slobodnim kožnim transplantatom i primjenu terapije negativnim tlakom.

Medicinska sestra sudjeluje u pripremi pacijenta za operaciju; uzimanju, pripremi i fiksaciji transplantata te postoperativnoj njezi.

KLJUČNE RIJEČI: NF, standardi liječenja, TNT, medicinska sestra

Medicinska sestra u pripremi i primjeni orthokin terapije

Ivana Štefan

SB Akromion, Croatia

Indikacije za primjenu orthokin terapije:

-akutne i kronične zglobne bolesti (artroze koljena, kuka, ramena, lakta i gležnja)

-reumatske ozljede hrskavice

-lumboishijalgije

-traumatske rupture muskulature.

U bolnici Akromion terapija orthokinom, aplicirana u koljeno, provedena je kod 41 pacijenta, od toga 19 žena i 22 muškaraca. Kod 6 žena i 1 muškarca orthokin terapija je aplicirana u oba koljena. Orthokin je potpuno biološka metoda liječenja koja ne koristi ništa drugo osim vlastitih endogenih proteina i faktora cijeljenja.

Intravencijske medicinske sestre u pripremi orthokin injekcija:

1. Krv iz vene se direktno uzima u specijalne EOT monovete (4 monovete)

-posebno tretirane staklene kuglice koje se nalaze unutar monovete lijepe na sebe krvna tjelešca i potiču sintezu zaštitnih proteina tijela.

2. Monovete se pohranjuju u termostat na 37°C 6 sati – što predstavlja optimalne uvjete za kvalitetnu sintezu zaštitnog proteina.

3. Centrifugiranjem 10 minuta na 5 000 okretaja krvna tjelešca se odvajaju od seruma obogaćenog visokom koncentracijom zaštitnog proteina, spremamo injekcije po 2ml u štrcaljku.

4. Dobijemo 5-6 injekcija seruma, stavljaju se u označeni spremnik i pohranjuju u zamrzivač

5. Ovisno o indikaciji liječnik aplicira orthokin u zglob jednom tjedno.

Zadaće medicinske sestre/ tehničara prije uzimanja uzorka krvi temelji se na pripremi bolesnika, priprema pribora za uzimanje uzorka i pripremi bolesnika i pribora za aplikaciju orthokin injekcije

Konzervativno liječenje prijeloma distalnog radijusa

David Elvis, Miran Bučar, Dragana Barukčić

KBC „Sestre milosrdnice“ ,Klinika za traumatologiju

Prijelom podlaktice, osobito palčane kosti jedan je od najčešćih prijeloma starije životne dobi. Ručni zglob jedan je od vjerojatno najkomplikiranijih zglobova ljudskog tijela zbog svoje anatomske specifičnosti i velikog broja zglobova koji ga čine kao cjelinu. Podlaktica i ručni zglob su u funkciji gornjeg ekstremiteta i tijekom svakodnevnih aktivnosti su od velike važni, što nalaže veliku pozornost pri zbrinjavanju njihovih ozljeda. U starijoj životnoj dobi većina prijeloma nastaje u žena i uvjetovani su slabijom osteoporotičnom kosti, što dodatno otežava liječenje.

Cilj rada je kroz praćenje broja ozljeđenika u Klinici za traumatologiju, KBC Sestre milosrdnice kroz dva uzastopna mjeseca pobliže prikazati koliko je zaprimljeno ozljeđenika s ozljedom prijeloma distalnog radijusa, koja im je prosječna životna dob, najčešće komplikacije koje se javljaju kod konzervativnog liječenja i omjer konzervativnog i operativnog liječenja. Usporedbom smjernica liječenja i algoritima u Klinici za traumatologiju, KBC Sestre milosrdnice i u zapadnim državama dobit ćemo uvid u duljinu trajanja liječenja i rehabilitacije ozljeđenika i odnos osteoporoze i prijeloma palčane kosti.

Obradom podataka istraživanja dobivene iz bolničkog informatičkog sustava (BIS-a) dobit ćemo uvid u broj ozljeđenika s ovom ozljedom, procjenu razine kvalitete dobivenih usluga za vrijeme liječenja, specifikacija usluga te evaluaciju uspjeha liječenja prijeloma i funkcije ručnog zgloba nakon liječenja u Klinici za traumatologiju KBC Sestre milosrdnice. Medicinska sestra/ tehničar kao dio zdravstvenog tima svoje znanje i vještine počinju koristiti prilikom samog dolaska ozljeđenika u hitnu ambulantu. Njezine intervencije i zadaće u skladu s njezinim kompetencijama započinju prilikom same dijagnostike ozljede i nastavljaju se tokom liječenja i rehabilitacije.

Važno je napomenuti da u sprječavanju nastanka ozljede palčane kosti veliku zadaću ima primarna zdravstvena zaštita koja edukacijom starijih osoba odnosno upućivanjem na mjere prevencije padova, liječenju osteoporoze i izradom plana i smjernica liječenja smanjuje broj ozljeđenika.

Ključne riječi: ozljeda palčane kosti, učestalost ozljede, liječenje, medicinska sestra/ tehničar

Liječenje V.A.C. VeraFlo sistemom u slučaju izloženog osteosintetskog materijala nakon operacije skolioze

Romana Vukšić

Helena Gugec, Blaža Karaklajić

Klinika za plastičnu, rekonstrukcijsku i estetsku kirurgiju, Klinička bolnica "Dubrava", Zagreb

Terapija negativnim tlakom (TNT) je neinvazivna metoda zbrinjavanja rane kojom se potiče stvaranje granulacijskog tkiva povećanjem lokalne prokrvljenost, smanjenjem edem i bakterijske kolonizacije.

E-poster je prikaz kliničkog slučaja pacijentice od 16 godina koja je bila podvrgnuta operaciji zbog skolioze. Pet godina nakon operacije došlo je do otvaranja rane i ekspozicije Harrington šipki. Predoperativna primjena KCl-a VeraFlo sistema se koristi kako bi se smanjila bakterijska kontaminacija rane i potaklo stvaranje granulacijskog tkiva. Nakon adekvatne pripreme rane slijedi plastično-rekonstruktivni kirurški postupak kojim se pokrije navedeni defekt i eksponirana šipka. Defekt se prekrilo lokalnim mišićnokutani režnjem lednog mišića, latissimus dorsi.

Lokalna infekcije rane je glavni uzrok dehiscence rane. Uporabom V.A.C. VeraFlo sistema potaknulo se smanjenje infekcije uz mehaničko čišćenje rane što je dalo značajan napredak u kvaliteti cijeljenja. Kod pacijentice godinu dana nakon operativnog zahvata rana je još uvijek u dobrom stanju, bez izlaganja materijala.

Medicinska sestra sudjeluje u pripremi pacijenta, postavljanju V.A.C sistema, debridmanu rane, odizanju i pripremi režnja te pokrivanju defekta.

KLJUČNE RIJEČI: TNT, rana, upotreba VAC, medicinska sestra

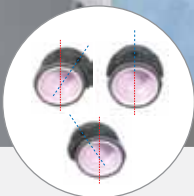
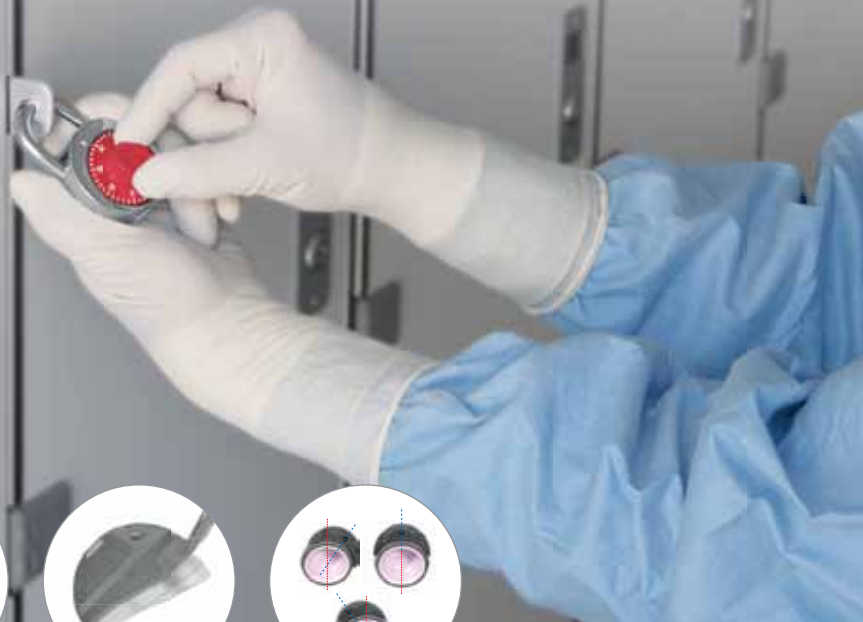
SEEFORT has made every effort to be accurate and exhaustive in this Book of Abstracts. As this is the only edition printed, we apologize for any mistakes that might have been made during the process of gathering information and prepress editing.



In some cases

only one combination leads to success



> SPACERS <

The use of spacers ensures precise coverage and anteversion of the acetabular component

> AUGMENTS <

The cranial module system is designed to fill bone defects and adapt to the size and position of the defect

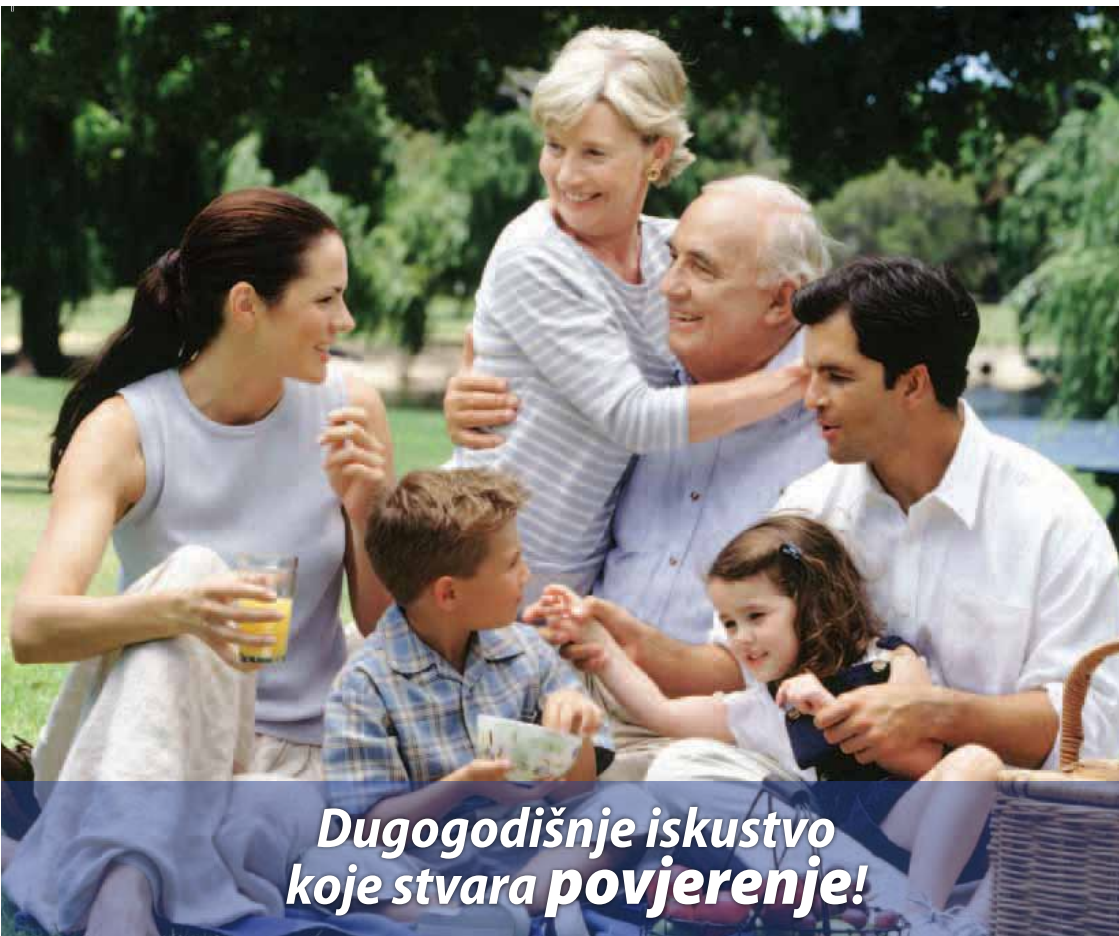With the **DELTA-REVISION TT** you can precisely restore the centre of rotation in case of bone defects thanks to the fully modular spacers, but not only. You can also restore the anteversion and the coverage - independently of the cup positioning. And there is more. The osteoconductive TT structure maximizes the bone contact and provides an optimal anchorage of the cup. For a successful revision.



Arthrex 







*Dugogodišnje iskustvo
koje stvara povjerenje!*



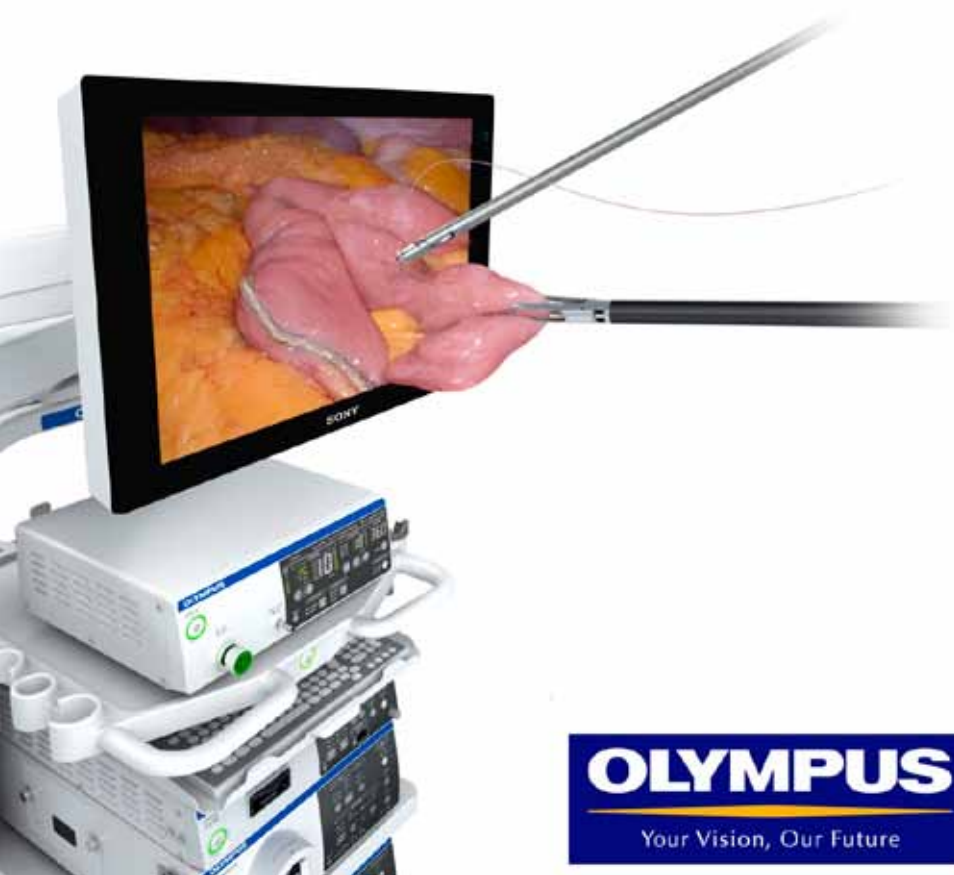ORTOPEDIJA

PAR-MAR

Nova cesta 75, 10000 ZAGREB

Tel: 01 / 3634 841 • Fax: 01 / 3820 898

www.par-mar.com



OLYMPUS

Your Vision, Our Future



ottobock.

Quality for life

Ortopedska pomagala

Pomagala za rehabilitaciju djece i odraslih

Steznici i bandaže

Otto Bock Adria d.o.o.

Dr. F. Tuđmana 14 · 10 431 Sv. Nedelja | T 01 3361 544 | e-mail ottobockadria@ottobock.hr

www.ottobock.hr

ZA LJEČENJE OSTEOPOROZE KOD ŽENA U POSTMENOPAUI I KOD MUŠKARACA
S POVEĆANIM RIZIKOM OD PRIJELOMA I ZA LJEČENJE OSTEOPOROZE
POVEZANE S PRODUŽENOM SISTEMSKOM GLUKOKORTIKOIDNOM TERAPIJOM
KOD ŽENA I MUŠKARACA S POVEĆANIM RIZIKOM OD FRAKTURE!

NJEZIN SLJEDEĆI KORAK NAKON PRIJELOMA ZBOG KRHKOSTI JE NOVA KOST



POUZDAJTE SE U ANABOLIČKI
UČINAK LIJEKA FORSTEO
KOJI POMAŽE BOLESNICIMA S
PRIJELOMIMA U SPRJEČAVANJU
NASTANKA NOVIH²⁻⁵

FORSTEO 20 mikrograma/80 mikrolitara otopina za injekciju u neupunjenu brizgalicu

Jedna doza od 80 mikrolitara sadrži 20 mikrograma teriparatida*. Jedna napunjena brizgalica s 2,4 ml sadrži 600 mikrograma teriparatida (što odgovara 250 mikrograma po ml).

*Teriparatid, rFTHr(1-34), koji je proizveden u E. coli tehnologijom rekombinantne DNK, istovjetan je sekenci 34 N-terminalne aminokiseline endogenog humanog paratiroidnog hormona.

Broj odobrenja za stavljanje lijeka u promet: EU/1/03/247/001 **Način i mjesto izdavanja lijeka:** Lijek se izdaje na recept. **Naziv i adresa nositelja odobrenja za stavljanje gotovog lijeka u promet:** Eli Lilly Nederland B.V., Grootslag 1-5, NL-3991 RA Houtven, Nizozemska. **Terapijske indikacije:** FORSTEO je indiciran u odraslih osoba. Liječenje osteoporoze u žena u postmenopauzi i u muškaraca s povećanim rizikom od prijeloma. U postmenopausalnih žena dokazano je značajno smanjenje incidencije vertebralnih i nevertebralnih prijeloma, no ne i prijeloma kuka. Liječenje osteoporoze povezano s dugotrajnom terapijom sustavnim glukokortikoidima u žena i muškaraca s povećanim rizikom od prijeloma. **Kontraindikacije:** preosjetljivost na djelatnu tvar ili na bilo koju od pomoćnih tvari, trudnoća i dojenje, već postojeća hiperkalcemija, teško oštećenje bubrega, metaboličke bolesti kostiju, osim osteoporoze (uključujući hiperparatireoidizam i Pagetovu bolest kostiju), nerazjašnjeno povećanje koncentracije alkalne fosfataze, prethodna teleradioterapija ili brahioradioterapija skeleta, bolesnici s malignim bolestima skeleta ili koštanim metastazama moraju se isključiti iz terapije teriparatidom. **Posebna upozorenja i mjere opreza pri uporabi:** U bolesnika s normalnom razinom kalcija u krvi primijećen je blagi i prolazan porast koncentracije serumskog kalcija nakon injekcije teriparatida. Vršne koncentracije kalcija u serumu postižu se između 4 i 6 sati nakon primjene lijeka, a vraćaju se na početne vrijednosti 16-24 sata nakon svake doze teriparatida. Nije potrebno rutinski pratiti koncentraciju kalcija tijekom liječenja. FORSTEO može malo povećati izlučivanje kalcija mokraćom, no incidencija hiperkalcemije nije se razlikovala od one u bolesnika koji su tijekom kliničkih ispitivanja primali placebo. FORSTEO nije ispitivan u bolesnika s aktivnom urolitijazom. FORSTEO treba primjenjivati uz oprez u bolesnika s aktivnom ili nedavnom urolitijazom jer može dovesti do pogoršanja tog stanja. U kratkoročnim kliničkim ispitivanjima su u bolesnika koji su primali FORSTEO zabilježene izolirane epizode prolazne ortostatske hipotenzije. Potreban je oprez u bolesnika s umjerenim ili teškim oštećenjem bubrega. Ograničena su iskustva primjene u populaciji mladih odraslih bolesnika, uključujući žene u predmenopauzi. Liječenje u ovoj skupini bolesnika smije započeti samo ako korist jasno nadilazi rizike. Žene generativne dobi moraju koristiti djelatovne metode kontracepcije tijekom primjene lijeka FORSTEO. Dode li do trudnoće, treba prekinuti primjenu lijeka FORSTEO. **Nuspojave:** Najčešće nuspojave u bolesnika koji su primali FORSTEO bile su mučnina, bol u udovima, glavobolja i omaglica. Nuspojave povezane s primjenom teriparatida u kliničkim ispitivanjima liječenja osteoporoze te nakon stavljanja lijeka u promet: porast tjelesne težine, srčani šum, porast alkalne fosfataze, srčani poremećaji (palpitacije, tahikardija), krvni poremećaji i poremećaji limfnog sustava (anemija), poremećaji živčanog sustava (omaglica, glavobolja, išijas, sinkopa), poremećaji uha i labirinta (vrtoglavica), poremećaji dišnog sustava (urimna inkontinencija, polurija, hitan nagon na mokrenje, nefrolitijaza), poremećaji kože i potkožnog tkiva (pojačano znojenje), poremećaji mišićno-koštanog sustava i vezivnog tkiva (bol u udovima, grčavi mišići, mialgija, artralgija, grč/bol u leđima), poremećaji metabolizma i prehrane (hiperkolesterolemija, hiperkalcemija, hiperuricemija), krvotilni poremećaji (hipotenzija), opći poremećaji i reakcije na mjestu primjene (umor, bol u prsima, astenija, blagi i prolazni događaji na mjestu davanja injekcije, uključujući bol, oticanje, eritem, lokalizirane podjave, pruritis i manja krvarenja na mjestu davanja injekcije, eritem na mjestu davanja injekcije, reakcija na mjestu davanja injekcije, moguće alergijske reakcije kratko nakon davanja injekcije, akutna dismija, orofacijalni edem, generalizirana urtikarija, bol u prsima, edem, psihijatrijski poremećaji (depresija)). **Doziranje i način primjene:** Preporučena doza lijeka FORSTEO iznosi 20 mikrograma jedanput na dan. Ukupno trajanje liječenja lijekom FORSTEO smije iznositi najduže 24 mjeseca (vidjeti dio 4.4). **24-mjesečni ciklus liječenja** lijekom FORSTEO ne smije se ponoviti tijekom života bolesnika. Sigurnost i djelatnost lijeka FORSTEO u djece i adolescenata mlađih od 18 godina nisu ustanovljene. FORSTEO se ne smije primjenjivati u pedijatrijski bolesnika (mlađih od 18 godina) niti u mladih odraslih osoba s otvorenim epifizama. **Važno: Informacije o primjeni samo za zdravstvene radnike.** Lijek Forsteeo izdaje se na recept. **Prije propisivanja lijeka Forsteeo molimo pročitajte zadnji odobreni Sažetak opisa svojstava lijeka i Uputu o lijeku.** Detaljnije informacije o ovom lijeku i zadnji odobreni Sažetak opisa svojstava lijeka možete dobiti od Eli Lilly (Suisse) S.A. Predstavništva u RH i na web stranici Europske agencije za lijekove: <http://www.ema.europa.eu>, te na web stranicama Europske komisije: http://ec.europa.eu/health/documents/community_register/html/allregister.htm. **Ovaj promotivni materijal sadrži bitne podatke o lijeku koji su istovjetni cjelokupnom odobrenom sažetku svojstava lijeka te cjelokupnoj odobrenoj uputi sukladno članku 15. Pravilnika o načinu oglašavanja o lijekovima i homeopatskim proizvodima („Narodne novine“ broj 118/2009, HRFT00177a(1)a), RUIJAN 2014.**

Reference: 1. Sažetak opisa svojstava lijeka Forsteeo, veljača 2014. 2. Near RM, et al., N Engl J Med 2011; 344: 1434 – 1441; 3. JIang Y, et al., J Bone Miner Res 2003; 18: 1932 – 1941. 4. Saag KG et al., NEJM 2007; 357: 2028. 5. Fahrleitner – Pammer A, et al. Osteoporosis Int 2011; 22: 2709 – 19.



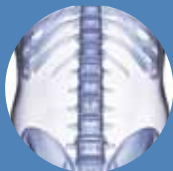
FORSTEO®
teriparatid

STVARAJUĆI NOVU KOST POMAŽE U BORBI
PROTIV NOVIH OSTEOPOROTIČNIH PRIJELOMA

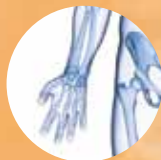

CROATIAN MEDICAL ASSOCIATION

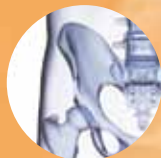**Croatian
Orthopaedic
Society**



SPINE



À la Carte



**Croatian
Orthopaedic
Society**

**Slovenian
Orthopaedic
Society**

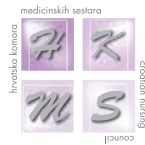

24.10.2015.



CROATIAN MEDICAL ASSOCIATION

**Croatian
Orthopaedic
Society**



**CROATIAN SOCIETY
FOR SPINE SURGERY**
CROATIAN MEDICAL ASSOCIATION



City of
Dubrovnik

SEEFORT Conference Organizers

Diamond sponsor



Platinum sponsor



Golden sponsor



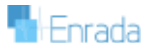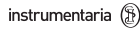Silver sponsor




Bronze sponsors



Other sponsors



SEEFORT Conference Sponsors



**GENERAL
ORTHOPAEDICS**




SPINE



JOINT REPLACEMENT



**PAEDIATRIC
ORTHOPAEDICS**



**MUSCULOSKELETAL
TRAUMATOLOGY**



**BIOTECHNOLOGY IN
ORTHOPAEDICS**



YOUTH DAY



NURSES DAY



REHABILITATION DAY